

4. Karaođlanođlu N, Gorguner M, Erođlu A. Hydatid disease of rib. *Ann Thorac Surg.* 2001;71:372–3.
5. Cobanoglu U, Sayir F, Őehitoglu A, Bilici S, Melek M. Therapeutic strategies for complications secondary to hydatid cyst rupture. *Int J Clin Exp Med.* 2011;4:220–6.

Miklat Arif Haberal,^a ŐzlemŐengoren DikiŐ,^{b,*} Gökhan Őztürk^a

^a Health Sciences University Bursa Y¼ksekhtisas Education & Research Hospital, Thoracic Surgery Department, Bursa, Turkey

^b Health Sciences University Bursa Y¼ksekhtisas Education & Research Hospital, Pulmonary Diseases Department, Bursa, Turkey

* Corresponding author.

E-mail address: ozlemsengoren@hotmail.com (. DikiŐ).

1579-2129/

 2017 SEPAR. Published by Elsevier Espaa, S.L.U. All rights reserved.

Incidental Finding of Right Pulmonary Artery Agenesis in an Adult[☆]



Hallazgo incidental de agenesia de la arteria pulmonar derecha en el adulto

To the Editor,

Pulmonary artery agenesis is a rare disease with a prevalence of 1 in 200 000 adults. It is associated with cardiovascular abnormalities, and is diagnosed in childhood. Patients can sometimes remain asymptomatic until adulthood without experiencing other complications.

We report the case of a 47-year-old man, referred to the pulmonology clinic after observation of elevated right hemidiaphragm on a routine chest X-ray (Fig. 1). The patient was a former smoker with no other history of interest. He did not report any symptoms.

Thoracic ultrasound was requested, which revealed an elevated right hemidiaphragm, with no signs of paradoxical movement.

Chest computed tomography (CT) (Fig. 1) showed findings consistent with right pulmonary artery agenesis, and an underdeveloped right lung with compensatory eventration of the contralateral lung. The examination was completed with cardiac magnetic resonance imaging (Fig. 1), which showed right pulmonary artery agenesis and partial agenesis of the right lung. The right upper lobe was draining via a single right pulmonary vein to the left atrium, with no evidence of an artery feeding that lobe, nor of shunts or other anomalies. Pulmonary hypertension was ruled out by echocardiogram.

Since the patient was asymptomatic, we decided to treat him conservatively with clinical follow-up in the pulmonology clinic.

Unilateral pulmonary artery agenesis is a rare congenital anomaly, caused by an anomaly in the rotation and migration of the sixth primitive aortic arch in the fourth or fifth week of embryonic development. Absent pulmonary artery is more frequent in the right branch than in the left. It is classified into three groups, depending on the clinical presentation¹: in group I, a left-to-right shunt develops and is diagnosed in childhood. In group II, severe pulmonary hypertension occurs and these patients generally die in the first few months of life. Group III consists of adults with few manifestations. The most common symptoms in adults are dyspnea, chest pain, hemoptysis, and recurrent infections, and 44% of patients develop pulmonary hypertension.²

This disease is generally diagnosed in childhood, in association with other cardiovascular malformations. A diagnostic suspicion in adulthood can be prompted by an abnormal chest X-ray.³ The definitive diagnostic test is CT with contrast medium and/or magnetic resonance imaging and/or angiographic studies.

There is no consensus on treatment. Some authors have recommended the use of repeated echocardiograms to monitor the development of pulmonary hypertension.⁴ In these cases, treatment with specific vasodilators or revascularization of the affected lung can improve patient progress.⁵ When lung infections are recurrent or severe hemoptysis develops, lobectomy or pneumonectomy is indicated.

Pulmonary artery agenesis, though rare, should be considered in the differential diagnosis of adults with recurrent lung infections or hemoptysis. Chest X-ray is a useful tool for the initial diagnosis,

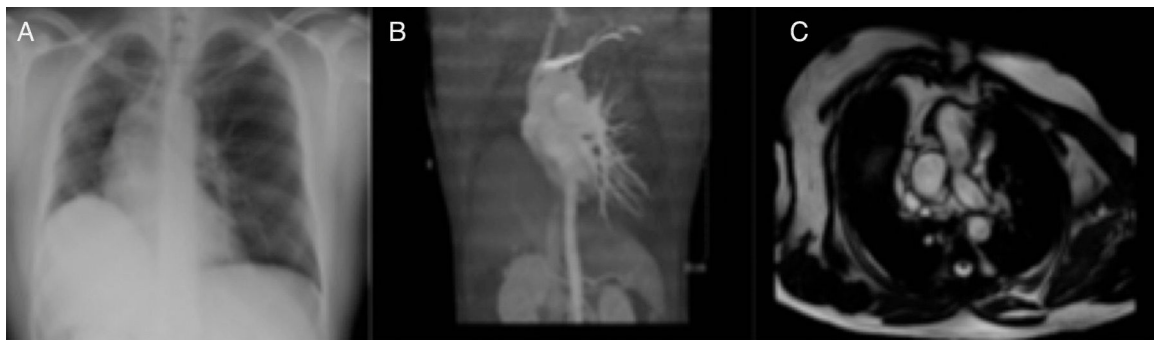


Fig. 1. (A) Chest radiograph showing elevation of the right hemidiaphragm. (B) CT reconstruction showing absence of the right pulmonary artery. (C) Cardiac magnetic resonance imaging slice with right pulmonary artery agenesis and partial agenesis of the right lung.

[☆] Please cite this article as: Csar EC, Aguirre MCF, Jimnez LP. Hallazgo incidental de agenesia de la arteria pulmonar derecha en el adulto. *Arch Bronconeumol.* 2017;53:693–694.

which should be confirmed by CT scans with contrast medium or magnetic resonance imaging.

Acknowledgements

We thank the Respiratory Medicine Department of the Hospital Universitario Virgen de la Victoria, and, in particular, Dr. Juan Antonio Romero Arias.

References

1. Bahler RC, Carson P, Traks E, Levene A, Gillespie D. Absent right pulmonary artery. Problems in diagnosis and management. *Am J Med.* 1969;46:64–71.
2. Takahashi T, Endo H, Ito T. Isolated unilateral absence of the left pulmonary artery: a case report. *Ann Vasc.* 2014;7:178–82.
3. Yiu MWC, Le DV, Leung Y, Ooi CGC. Radiological features of isolated unilateral absence of the pulmonary artery. *J HK Coll Radiol.* 2001;4:277–80.

4. Turner DR, Vincent JA, Epstein ML. Isolated right pulmonary artery discontinuity. *Images Paediatr Cardiol.* 2000;4:24–30.
5. Reading DW, Oza U. Unilateral absence of a pulmonary artery: a rare disorder with variable presentation. *Proc (Bayl Univ Med Cent).* 2012;25:115–8.

Eva Cabrera César,* M. Carmen Fernández Aguirre,
Lorena Piñel Jiménez

*Servicio de Neumología, Hospital Universitario Virgen de la Victoria,
Málaga, Spain*

Corresponding author.

E-mail address: evacabreracesar@gmail.com (E.C. César).

1579-2129/

© 2017 SEPAR. Published by Elsevier España, S.L.U. All rights reserved.

Pleural Effusion After Intravesical Administration of Bacillus Calmette-Guérin*



Derrame pleural tras tratamiento intravesical con bacilo de Calmette-Guérin

To the Editor,

Intravesical instillation of bacillus Calmette-Guérin (BCG), a live attenuated strain of *Mycobacterium bovis*, has been shown in numerous studies to be an effective treatment for superficial *in situ* bladder cancer. However, this procedure is not free of complications.^{1–3}

We report the case of a patient diagnosed with pleural effusion due to *M. bovis* after treatment with intravesical BCG instillation.

This was an 85-year-old man, former smoker, with mild chronic obstructive pulmonary disease, atrial fibrillation, and pacemaker implantation due to sick sinus syndrome, diagnosed with multifocal transitional cell carcinoma of the bladder treated by transurethral resection and 6 BCG instillations. One year later, he presented in the emergency department with pleuritic chest pain and increased dyspnea. Chest radiograph (Fig. 1) revealed right pleural effusion. Empirical antibiotic therapy began with amoxicillin/clavulanic acid and the patient was admitted to the respiratory medicine department for further examination with chest computed tomography (CT) and diagnostic thoracentesis. The CT revealed extensive right pleural effusion with passive atelectasis of the ipsilateral lower lobe, subpleural calcified granuloma in the left lower lobe, and prevascular and hilar lymphadenopathies, suggestive of a previous granulomatous process. Thoracentesis was performed, yielding cloudy pleural exudate with elevated adenosine deaminase (ADA) (63.9 U/l), and a predominance of mononuclear cells (85%). We did not perform a pleural biopsy due to the high probability that this was a *Mycobacterium* infection, given the characteristics of the pleural fluid. Culture of the fluid was positive for *M. bovis*, leading to a diagnosis of pleural effusion due to *M. bovis* caused by intravesical instillation of BCG. The patient was treated for 6 months with isoniazid, rifampicin, and ethambutol with good clinical response and resolution of the pleural effusion, with no adverse drug effects.

Although intravesical instillation of BCG is usually well tolerated, local (1%) and systemic (4.8%) complications have been described. Among the systemic events, pulmonary complications

account for 1%–3% and 5 forms of presentation have been described: interstitial pneumonitis, empyema, diffuse alveolar damage, pneumonia with or without cavitation, and miliary tuberculosis (TB). The latter is the most common form of infection due to BCG in the literature and accounts for one third of cases.^{1,2} Some authors argue that the underlying cause of systemic involvement is hypersensitivity to the BCG, while others believe that it is due to systemic dissemination after hematogenous seeding from the bladder.^{3,4}

No evidence is available to show that prophylaxis with isoniazid protects against systemic dissemination after intravesical BCG administration.⁵ Complications may take months or even years to appear after the first instillation.²

In our patient, culture was positive for *M. bovis*. The chest CT showed residual lesions suggestive of an old untreated TBC. Complications occur more often in patients with a history of TBC than in patients without previous tuberculous disease.⁶

Our case was an unusual presentation of bacilli in the pleural fluid, prompting a diagnosis of pleural effusion due to BCG dissemination after intravesical instillation, 1 year after receiving this treatment. It is also uncommon for this complication to present as pleural effusion. We could only find 1 similar case of pleural

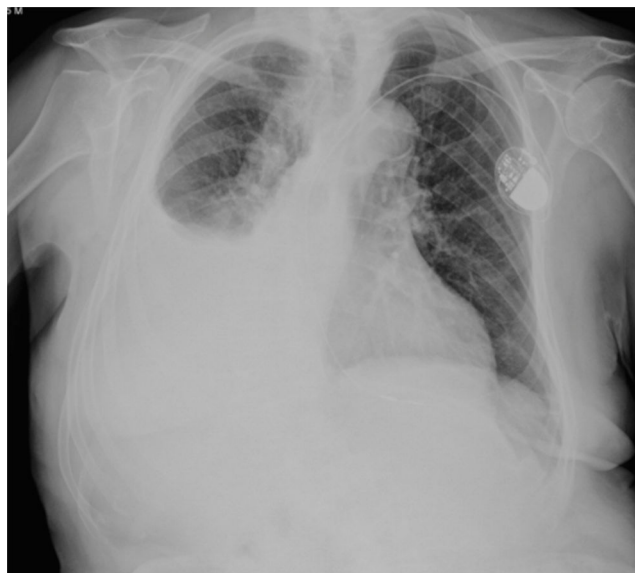

Fig. 1. Posteroanterior chest radiograph. Large right pleural effusion. Intracavitary pacemaker.

* Please cite this article as: Roca Noval A. Derrame pleural tras tratamiento intravesical con bacilo de Calmette-Guérin. *Arch Bronconeumol.* 2017;53:694–695.