

## Scientific Letters

### Sarcoid-Like Reaction With Mediastinal and Pulmonary Involvement in a Patient With Testicular Cancer<sup>☆</sup>



#### *Reacción sarcoidosa con afectación mediastínica y pulmonar en paciente con antecedente de cáncer testicular*

To the Editor,

Sarcoidosis is a chronic multi-systemic granulomatous disease of unknown origin, characterized by the appearance of multiple epithelioid granulomas in different organs. It has typically been described in cancer patients, before, during or after their diagnosis of malignant disease.<sup>1</sup> In contrast, a sarcoid-like reaction (SR) is considered a specific entity, consisting of a sarcoid-like syndrome caused by a crossover reaction to circulating tumor antigens in some cancer patients.<sup>2</sup> We report a case of SR in a cancer patient detected during the differential diagnostic process of suspected metastatic dissemination of the primary tumor.

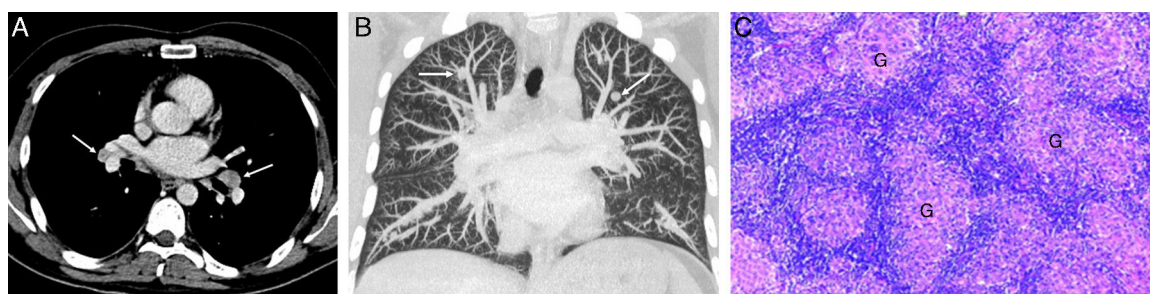
This was a 32-year-old man with a history of testicular germ cell tumor (embryonal carcinoma) detected in 2009, treated with surgery and chemotherapy, with no evidence of local or distant tumor relapse. In follow-up, a whole-body computed tomography (CT) performed 6 years after diagnosis revealed a symmetric radiological pattern of bilateral mediastinal and hilar lymphadenopathies (Fig. 1A) and bilateral pulmonary nodules (Fig. 1B). In view of these radiological findings, a differential diagnosis of either metastatic tumor dissemination or SR was proposed. The latter seemed more likely, given the radiological pattern and the long period (6 years) without evidence of malignant disease. To reach a definitive diagnosis, we first performed a biopsy of one hilar lymphadenopathy by endobronchial ultrasound, which was

found on histology to be consistent with SR. Secondly, we decided to perform a surgical biopsy of several pulmonary nodules using video-assisted thoracoscopy, which were also confirmed on histology to be SR (Fig. 1C).

Cases have been described in the literature of patients with testicular cancer who have developed SR during their oncological follow-up, in the absence of local tumor recurrence or distant metastasis. The relationship between SR and testicular cancer is controversial, partly because both diseases occur in young men, so the association may, to a certain extent, be coincidental.<sup>3,4</sup> Patients with SR generally have a symmetrical radiological pattern of bilateral hilar and mediastinal lymphadenopathies, while concomitant bilateral pulmonary nodules are less common. In a recent review of SR in patients with testicular cancer, it was observed that: (1) involvement is mild and basically limited to the mediastinum and the lung; (2) it can resolve spontaneously without specific treatment (indeed, most patients did not receive corticosteroids), and (3) chemotherapy is not a criterion for appearance.<sup>5</sup>

The appearance of intrathoracic lymphadenopathies and pulmonary nodules in patients with testicular cancer is a diagnostic challenge with significant therapeutic repercussions. SR should be suspected if metastatic disease is not detected in other sites, and it is essential that a definitive histological diagnosis is reached using fiberoptic bronchoscopy/endobronchial ultrasound and/or video-assisted thoracoscopy. To assume the presence of metastatic disease without histological confirmation would involve exposing the patient to unnecessary chemotherapy, and even worse, the failure of the granulomatous disease to respond to chemotherapy would lead to the use of more aggressive second-line therapies with greater side effects.

We believe that awareness of SR as a syndrome that can simulate metastatic disease in some patients with testicular cancer is



**Fig. 1.** (A) Axial chest CT (mediastinal window) showing symmetrical bilateral hilar lymphadenopathies (arrows). (B) Coronal maximum intensity projection of chest CT (pulmonary parenchymal window) revealing bilateral pulmonary nodule, predominantly in the upper lobes (arrows). (C) Histological image of a pulmonary nodule resected by video-assisted thoracoscopy showing non-necrotizing granulomas (G) formed by epithelioid histiocytes with no neoplastic cellularity.

<sup>☆</sup> Please cite this article as: Ureña-Vacas A, Pinilla-Pagnon I, Gorospe Sarasúa L. Reacción sarcoidosa con afectación mediastínica y pulmonar en paciente con antecedente de cáncer testicular. Arch Bronconeumol. 2017;53:77–78.

essential for optimal management, and for avoiding unnecessary chemotherapy. Cases in which SR is suspected on radiology must always be confirmed by histology.

## References

- Shigemitsu H. Is sarcoidosis frequent in patients with cancer? *Curr Opin Pulm Med.* 2008;14:478–80.
- Parra ER, Canzian M, Saber AM, Coêlho RS, Rodrigues FG, Kairalla RA, et al. Pulmonary and mediastinal sarcoidosis following surgical resection of cancer. *Pathol Res Pract.* 2004;200:701–5.
- Tjan-Heijnen VC, Vlasveld LT, Pernet FP, Pauwels P, de Mulder PH. Coincidence of seminoma and sarcoidosis: a myth or fact. *Ann Oncol.* 1998;9:321–5.
- Paparel P, Devonec M, Perrin P, Ruffion A, Decaussin-Petrucci M, Akin O, et al. Association between sarcoidosis and testicular carcinoma: a diagnostic pitfall. *Sarcoidosis Vasc Diffuse Lung Dis.* 2007;24:95–101.
- Kaikani W, Boyle H, Chatte G, de la Roche E, Errihani H, Droz JP, et al. Sarcoid-like granulomatosis and testicular germ cell tumor: the great imitator. *Oncology.* 2011;81:319–24.

Almudena Ureña-Vacas,<sup>a,\*</sup> Ignacio Pinilla-Pagnon,<sup>b</sup> Luis Gorospe Sarasúa<sup>a</sup>

<sup>a</sup> Servicio de Radiodiagnóstico, Hospital Universitario Ramón y Cajal, Madrid, Spain

<sup>b</sup> Servicio de Anatomía Patológica, Hospital Universitario Ramón y Cajal, Madrid, Spain

\* Corresponding author.

E-mail address: [almuvacas90@gmail.com](mailto:almuvacas90@gmail.com) (A. Ureña-Vacas).

## Tracheomalacia Due to Esophageal Achalasia<sup>☆</sup>



### Traqueomalacia debida a acalasia esofágica

To the Editor,

Primary esophageal achalasia, although rare, is a disorder of esophageal motility that is the result of a loss of ganglion cells responsible for motility and relaxation of the lower esophageal sphincter. As a result, patients present with worsening dysphagia to both liquids and solids and suffer from significant regurgitation of retained food, with weight loss and chronic cough. Achalasia symptoms may often mimic common diseases, and therefore, may delay the diagnosis.<sup>1</sup>

We report the case of a 10 years-old child who complained of barking cough from the age of 2 years and recurrent wheezing from the age of 3 years, with positive skin prick tests for alternaria. The child presented with frequent regurgitations in his first months of life, which subsequently disappeared.

Over the previous 6 months, the child had complained of epigastric discomfort and sensation of heaviness while eating, nocturnal cough and occasionally nocturnal emesis. Based on the change of symptoms, the family's pediatrician proposed treatment with long acting  $\beta$ 2-adrenergic agonist (LABA)/ICS, without benefit. Admitted to a peripheral hospital, the child was transferred to our ward with the request to perform fiberoptic bronchoscopy and esophageal pHmetry for wheezing not responding to treatment and suspicion of gastroesophageal reflux disease. At admission he had body length of 141 cm (25–50th percentile), body weight of 31.5 kg (10th–25th percentile), transcutaneous oxygen saturation of 100%, respiratory rate 20 breaths per minute. Chest and abdomen examination were normal. Routine laboratory tests were normal, and allergy tests showed total IgE 193 KU/L with specific IgE for alternaria 23.2 KU/L. Spirometry revealed a flow/volume curve with reduction in PEF and FEV1 and a plateau consistent with tracheomalacia.

Fiberoptic bronchoscopy showed a tracheomalacia suggestive of aberrant innominate artery compression. The tracheal stenosis was fixed and pulsating, and the diameter remained constant with inspiration/expiration. The disease was localized where the vascular compression was present.

Spelunking the esophagus with the same instrument showed a severe dilatation. The child underwent esophagography, which showed a megaesophagus with “bird’s beak appearance” of the distal portion, typical of achalasia; esophageal manometry con-

firmed the diagnosis. Magnetic resonance angiography of the thorax showed compression of the trachea against the innominate artery normally located, caused by megaesophagus (Fig. 1).

The patient underwent a laparoscopic Heller myotomy and Dor fundoplication with progressive resolution of symptoms.

The indication to perform the fiberoptic bronchoscopy in this patient was the recurrent wheezing not responding to treatment and chronic barking cough. The tracheomalacia shown during the procedure was first considered to be a consequence of aberrant innominate artery compression. Tracheomalacia can be caused by weakness of muscular wall and supporting cartilage due to external compression from abnormal vascular structures. In this patient, however, tracheomalacia was likely due to a displacement of the trachea caused by megaesophagus against the innominate artery normally located. The presence of burking cough from the age of 3 years shows that this tracheal anomaly was antecedent.

The incidence of achalasia in childhood is 0.11–0.18/100,000 children/year.<sup>2–4</sup> The disease can manifest at any age, but onset of symptoms before adolescence is rare.<sup>3</sup> Achalasia commonly manifests with dysphagia, post-prandial vomiting, failure to thrive and retrosternal chest pain or discomfort. Pulmonary symptoms may appear as a consequence of chronic inhalation of the esophageal stagnant content; children can present with chronic nocturnal wet cough, wheezing and recurrent pneumonia. Tracheal compression is also reported, due to bulging of megaesophagus against the trachea, together with cough, wheezing and/or stridor as prominent feeding or exercise correlated symptoms. Chest X-ray can be suggestive when presenting an air-fluid level in thoracic esophagus, a small/absent gastric air bubble and anterior displacement and bowing of trachea on the lateral view.<sup>2</sup>

Esophagography shows retained food in the esophagus and the “bird’s beak” sign in the distal portion, suggestive of esophageal achalasia. Manometry will confirm the diagnosis. Pulmonary function tests can be useful, and fiberoptic bronchoscopy usually is not requested.

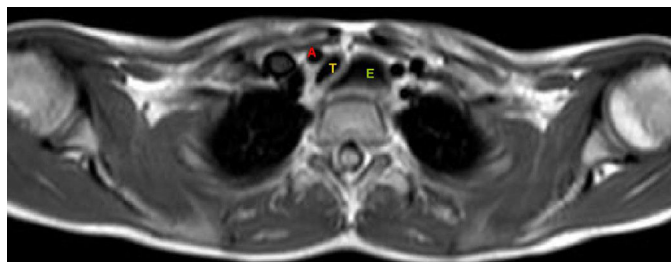


Fig. 1. MRA showing displacement and compression of the trachea (T) against innominate artery (A) caused by esophageal dilatation (E).

<sup>☆</sup> Please cite this article as: De Pieri C, Cogo P, Barbato A. Traqueomalacia debida a acalasia esofágica. *Arch Bronconeumol.* 2017;53:78–79.