

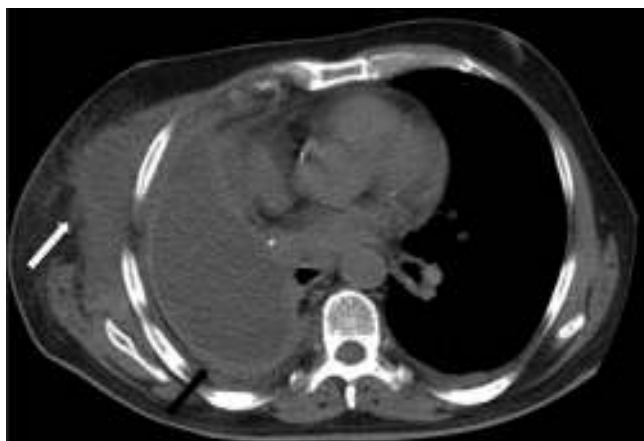

Fig. 1. Pleural empyema of the remaining cavity (black arrow) associated with an abscess contiguous with the chest wall (white arrow).

References

1. Kacprzak G, Marciniak M, Addae-Boateng E, Kolodziej J, Pawelczyk K. Causes and management of postpneumectomy empyemas: our experience. *Eur J Cardiothorac Surg.* 2004;26:498–502.
2. Schueckler OJ, Rodriguez MI, Takita H. Delayed postpneumectomy empyema. *J Cardiovasc Surg (Torino).* 1995;36:515–7.
3. Cooper GS, Kou TD, Rex DK. Complications following colonoscopy with anesthesia assistance: a population-based analysis. *JAMA Intern Med.* 2013;173:551–6.
4. Jamieson NF, Willoughby CP. Gas gangrene after colonoscopy. *Postgrad Med J.* 2001;77:47–9.

Agustin Dietrich,* Victor E. Abdala, David E. Smith

Servicio de Cirugía Torácica y Trasplante Pulmonar, Hospital Italiano de Buenos Aires, Buenos Aires, Argentina

* Corresponding author.

E-mail address: Agustin.dietrich@hospitalitaliano.org.ar

(A. Dietrich).

Non-Invasive Ventilation: Has it Been Forgotten in the Diagnosis-Related Groups?*



Ventilación no invasiva: una realidad olvidada en los grupos relacionados de diagnóstico

To the Editor:

Nowadays, no-one questions the role of non-invasive ventilation (NIV) in the routine practice of a pulmonology department. However, despite its widespread use, we encounter serious difficulties when coding this intervention in the diagnosis-related groups (DRG). As we know, the DRG system groups patients with similar clinical characteristics and resource requirements into categories. In Spain, we have been using the All Patient Refined-DRG (APR-DRG) since 1997, which provides an additional 4 severity levels and 4 mortality risk levels.¹ The main problem is that no DRGs specifically mention NIV.

Criner et al.² drew attention to this problem in 1995, when they reported that failure to allocate the real cost of NIV could prevent hospitals from obtaining reimbursement for this treatment. Other authors have alerted us to the urgent need for incorporating NIV in DRG coding to prevent a situation in which clinicians, compelled by their managers, may even prefer to intubate patients rather than apply NIV, in order to receive greater reimbursement.^{3,4}

We have reviewed version 25.0 of the DRG definitions manual,¹ and found that NIV is not mentioned at all. The term “invasive mechanical ventilation” is specified in only 2 DRGs: 881 (respiratory system diagnosis with mechanical ventilation more than 96 h) and 882 (respiratory system diagnosis with mechanical ventilation less than 96 h). The term “mechanical ventilation for certain clinical situations” appears as a procedure classified as a major complication or comorbidity (CC) in other disease entities. This is the case for DRG 588 (bronchitis and asthma, age <17 years with major CC),

589 (bronchitis and asthma, age <18 years with major CC), 540 (respiratory infections and inflammations except uncomplicated pneumonia with major CC), and 541 (uncomplicated pneumonia and other respiratory disorders except bronchitis, asthma with major CC) (Table 1).

If NIV is administered to a patient with obesity hypoventilation syndrome, things become even more complicated. The term “hypoventilation” does not figure in the manual, and the term “obesity” only appears in surgical DRG 288 (gastric procedures for obesity). However, the term “respiratory failure” appears as a CC in many other diseases.

How, then, are DRGs being applied for patients seen on the pulmonology ward? How do we code our discharge reports? Is it correct to include NIV administered to hypoventilated patients in DRG 588? Should severely ill patients who receive NIV for more than 96 h be classified as DRG 881? Could this failure to provide clear criteria lead to local arrangements in different hospitals, meaning that different DRGs are applied to the same diseases and procedures? We firmly believe that NIV needs to be included as a separate entity in DRG manuals. This would give NIV recognition as a product, and allow this therapeutic tool to be correctly valued.

Table 1

Diagnosis-Related Groups From Major Diagnostic Category 4: “Respiratory Tract Diseases and Disorders” in Which the Term “Mechanical Ventilation” Appears.

DRG	Description	Weight
540	Respiratory infections and inflammations except uncomplicated pneumonia with major CC	3367.9
541	Uncomplicated pneumonia and other respiratory disorders except bronchitis, asthma with major CC	2343.1
588	Bronchitis and asthma. Age >17 years with major CC	1486.6
589	Bronchitis and asthma. Age <18 years with major CC	1736.4
881 ^a	Respiratory system diagnosis with mechanical ventilation >95 h	10,748.8
882 ^a	Respiratory system diagnosis with mechanical ventilation <96 h	4642.5

CC, complication or comorbidity; DRG, diagnosis-related groups.

^a Invasive mechanical ventilation.

* Please cite this article as: Mayoralas-Alises S, Díaz-Lobato S, Granados-Ulecia C. Ventilación no invasiva: una realidad olvidada en los grupos relacionados de diagnóstico. *Arch Bronconeumol.* 2016;52:281–282.

References

1. Manual de descripción de los Grupos Relacionados de Diagnóstico (APGRD v25.0). 5th ed. Bilbao: Administración de la Comunidad Autónoma del País Vasco, Osakidetza/Servicio Vasco de Salud; 2010. Available at: http://www.osakidetza.euskadi.eus/contenidos/informacion/osk_publicaciones/es_publi/adjuntos/calidad/ManualAPGRDv.25.0.pdf [accessed 12.09.15].
2. Criner GJ, Creimer DT, Tomaselli M, Pierson W, Evans D. Financial implications of noninvasive positive pressure ventilation (NPPV). *Chest*. 1995;108:475–81.
3. Elliot MW, Confalonieri M, Nava S. Where to perform noninvasive ventilation? *Eur Respir J*. 2002;19:1159–66.
4. Gabrielli A, Caruso LJ, Layon AJ, Antonelli M. Yet another look at noninvasive positive-pressure ventilation. *Chest*. 2003;124:428–31.

Sagrario Mayoralas-Alises,^{a,*} Salvador Díaz-Lobato,^a Cristina Granados-Ulecia^b

^a Servicio de Neumología, Hospital Ramón y Cajal, Madrid, Spain

^b Dirección Gerencia, Complejo Hospitalario de Toledo, Toledo, Spain

Corresponding author.

E-mail address: sarimayoralas@gmail.com

(S. Mayoralas-Alises).

Fire Eater's Pneumonia: The Role of Computed Tomography[☆]



Neumonía del tragafuegos: el papel de la tomografía computarizada

To the Editor,

We read with great interest the recent letter to the editor from Lizarzábal Suárez et al.¹ describing the case of a 19-year-old man who aspirated liquid paraffin during a fire-eating act. The patient developed lipoid pneumonia, and chest computed tomography showed three cavitary lesions in the pulmonary parenchyma.

We would like to highlight the findings from a similar case recently encountered. A 26-year-old man was admitted with dyspnea, cough, fever (39 °C), and chest pain. Two days before admission, he had accidentally aspirated liquid paraffin during a fire-eating act. Blood count revealed elevated white blood cells,

with a leftward shift. Other laboratory data were unremarkable. Computed tomography demonstrated a heterogeneous mass in the right lower lobe, adjacent to the pleural surface (Fig. 1A). Bronchoscopy revealed inflamed, hyperemic bronchial mucosa without purulence or evidence of necrosis. Bronchoalveolar lavage fluid showed numerous lipid-laden macrophages (Fig. 1C). The patient was treated with systemic steroids and antibiotics. Computed tomography performed 2 weeks after admission showed remarkable improvement, with reabsorption of the mass, leaving residual scarring (Fig. 1B).

Fire eater's pneumonia (FEP) is caused by the accidental acute aspiration of hydrocarbon products during a fire-blowing act.^{2–4} The performer blows a mouthful of liquid hydrocarbon against a burning stick, thereby creating an aerosol that ignites around the stick.⁵ If aspirated, these hydrocarbons can diffuse rapidly throughout the bronchial tree, inducing bronchial edema, tissue damage, and surfactant destruction. As a consequence, the compounds provoke macrophage activation and cause a local inflammatory reaction.^{2,4}

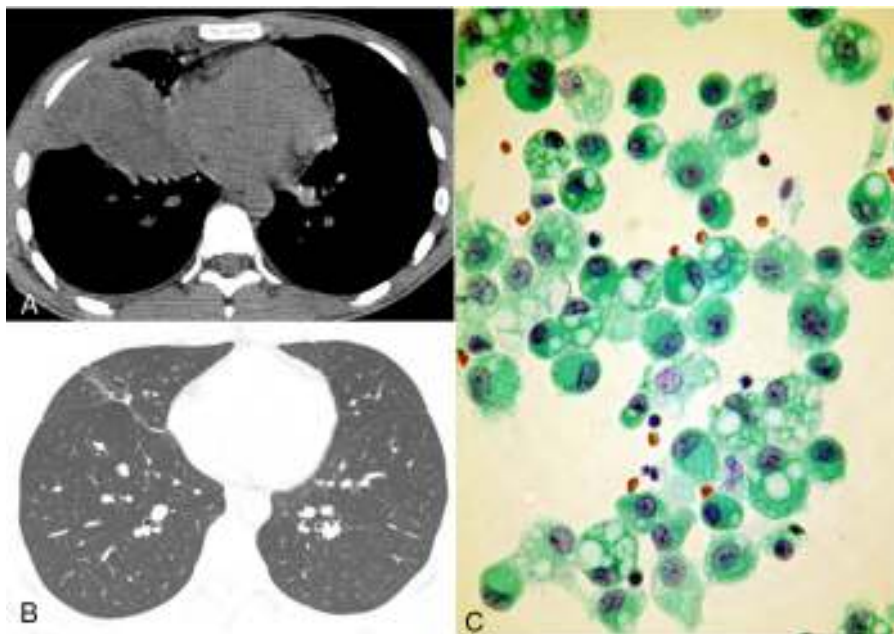


Fig. 1. (A) Computed tomography with the mediastinal window setting shows a mass in the right lower lobe, adjacent to the pleural surface. (B) Follow-up computed tomography with the lung window setting demonstrated reabsorption of the mass, with residual scarring. (C) Alveolar macrophages recovered by bronchoalveolar lavage. The cytoplasm is full of large rounded vacuoles that displace nuclei to the periphery.

[☆] Please cite this article as: Marchiori E, Soares-Souza A, Zanetti G. Neumonía del tragafuegos: el papel de la tomografía computarizada. *Arch Bronconeumol*. 2016;52:282–283.