

essential for optimal management, and for avoiding unnecessary chemotherapy. Cases in which SR is suspected on radiology must always be confirmed by histology.

References

- Shigemitsu H. Is sarcoidosis frequent in patients with cancer? *Curr Opin Pulm Med.* 2008;14:478–80.
- Parra ER, Canzian M, Saber AM, Coêlho RS, Rodrigues FG, Kairalla RA, et al. Pulmonary and mediastinal sarcoidosis following surgical resection of cancer. *Pathol Res Pract.* 2004;200:701–5.
- Tjan-Heijnen VC, Vlasveld LT, Pernet FP, Pauwels P, de Mulder PH. Coincidence of seminoma and sarcoidosis: a myth or fact. *Ann Oncol.* 1998;9:321–5.
- Paparel P, Devonec M, Perrin P, Ruffion A, Decaussin-Petrucci M, Akin O, et al. Association between sarcoidosis and testicular carcinoma: a diagnostic pitfall. *Sarcoidosis Vasc Diffuse Lung Dis.* 2007;24:95–101.
- Kaikani W, Boyle H, Chatte G, de la Roche E, Errihani H, Droz JP, et al. Sarcoid-like granulomatosis and testicular germ cell tumor: the great imitator. *Oncology.* 2011;81:319–24.

Almudena Ureña-Vacas,^{a,*} Ignacio Pinilla-Pagnon,^b
Luis Gorospe Sarasúa^a

^a Servicio de Radiodiagnóstico, Hospital Universitario Ramón y Cajal, Madrid, Spain

^b Servicio de Anatomía Patológica, Hospital Universitario Ramón y Cajal, Madrid, Spain

* Corresponding author.

E-mail address: almuvacas90@gmail.com (A. Ureña-Vacas).

Tracheomalacia Due to Esophageal Achalasia[☆]



Traqueomalacia debida a acalasia esofágica

To the Editor,

Primary esophageal achalasia, although rare, is a disorder of esophageal motility that is the result of a loss of ganglion cells responsible for motility and relaxation of the lower esophageal sphincter. As a result, patients present with worsening dysphagia to both liquids and solids and suffer from significant regurgitation of retained food, with weight loss and chronic cough. Achalasia symptoms may often mimic common diseases, and therefore, may delay the diagnosis.¹

We report the case of a 10 years-old child who complained of barking cough from the age of 2 years and recurrent wheezing from the age of 3 years, with positive skin prick tests for alternaria. The child presented with frequent regurgitations in his first months of life, which subsequently disappeared.

Over the previous 6 months, the child had complained of epigastric discomfort and sensation of heaviness while eating, nocturnal cough and occasionally nocturnal emesis. Based on the change of symptoms, the family's pediatrician proposed treatment with long acting β 2-adrenergic agonist (LABA)/ICS, without benefit. Admitted to a peripheral hospital, the child was transferred to our ward with the request to perform fiberoptic bronchoscopy and esophageal pHmetry for wheezing not responding to treatment and suspicion of gastroesophageal reflux disease. At admission he had body length of 141 cm (25–50th percentile), body weight of 31.5 kg (10th–25th percentile), transcutaneous oxygen saturation of 100%, respiratory rate 20 breaths per minute. Chest and abdomen examination were normal. Routine laboratory tests were normal, and allergy tests showed total IgE 193 KU/L with specific IgE for alternaria 23.2 KU/L. Spirometry revealed a flow/volume curve with reduction in PEF and FEV1 and a plateau consistent with tracheomalacia.

Fiberoptic bronchoscopy showed a tracheomalacia suggestive of aberrant innominate artery compression. The tracheal stenosis was fixed and pulsating, and the diameter remained constant with inspiration/expiration. The disease was localized where the vascular compression was present.

Spelunking the esophagus with the same instrument showed a severe dilatation. The child underwent esophagography, which showed a megaesophagus with “bird’s beak appearance” of the distal portion, typical of achalasia; esophageal manometry con-

firmed the diagnosis. Magnetic resonance angiography of the thorax showed compression of the trachea against the innominate artery normally located, caused by megaesophagus (Fig. 1).

The patient underwent a laparoscopic Heller myotomy and Dor fundoplication with progressive resolution of symptoms.

The indication to perform the fiberoptic bronchoscopy in this patient was the recurrent wheezing not responding to treatment and chronic barking cough. The tracheomalacia shown during the procedure was first considered to be a consequence of aberrant innominate artery compression. Tracheomalacia can be caused by weakness of muscular wall and supporting cartilage due to external compression from abnormal vascular structures. In this patient, however, tracheomalacia was likely due to a displacement of the trachea caused by megaesophagus against the innominate artery normally located. The presence of burking cough from the age of 3 years shows that this tracheal anomaly was antecedent.

The incidence of achalasia in childhood is 0.11–0.18/100,000 children/year.^{2–4} The disease can manifest at any age, but onset of symptoms before adolescence is rare.³ Achalasia commonly manifests with dysphagia, post-prandial vomiting, failure to thrive and retrosternal chest pain or discomfort. Pulmonary symptoms may appear as a consequence of chronic inhalation of the esophageal stagnant content; children can present with chronic nocturnal wet cough, wheezing and recurrent pneumonia. Tracheal compression is also reported, due to bulging of megaesophagus against the trachea, together with cough, wheezing and/or stridor as prominent feeding or exercise correlated symptoms. Chest X-ray can be suggestive when presenting an air-fluid level in thoracic esophagus, a small/absent gastric air bubble and anterior displacement and bowing of trachea on the lateral view.²

Esophagography shows retained food in the esophagus and the “bird’s beak” sign in the distal portion, suggestive of esophageal achalasia. Manometry will confirm the diagnosis. Pulmonary function tests can be useful, and fiberoptic bronchoscopy usually is not requested.

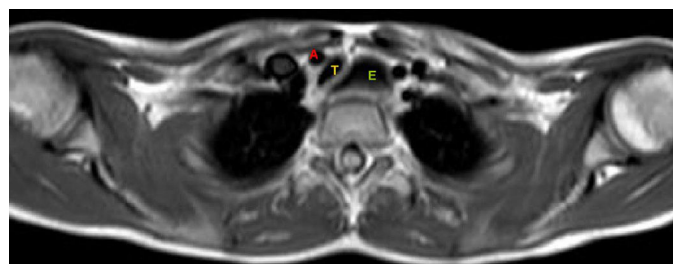


Fig. 1. MRA showing displacement and compression of the trachea (T) against innominate artery (A) caused by esophageal dilatation (E).

[☆] Please cite this article as: De Pieri C, Cogo P, Barbato A. Traqueomalacia debida a acalasia esofágica. *Arch Bronconeumol.* 2017;53:78–79.

Heller's esophagocardiomyotomy is the treatment of choice for children with achalasia because of its safety and long-term effective results after surgery.⁵

In our patient, chronic barking cough was caused by a secondary tracheomalacia resulting from a shift of the trachea against the innominate artery normally located.

References

- Franklin AL, Petrosyan M, Kane TD. Childhood achalasia: a comprehensive review of disease, diagnosis and therapeutic management. *World J Gastrointest Endosc.* 2014;6:105–11.
- Al-Abdoulisalam T, Anselmo MA. An 11-year-old male patient with refractory asthma and heartburn. *Can Respir J.* 2011;18:81–3.
- Hallal C, Kieling CO, Nunes DL, Ferreira CT, Peterson G, Barros SG, et al. Diagnosis, misdiagnosis, and associated diseases of achalasia in children and adolescents: a twelve-year single center experience. *Pediatr Surg Int.* 2012;28:1211–7.
- Marlais M, Fishman JR, Fell JM, Haddad MJ, Rawat DJ. UK incidence of achalasia: an 11-year national epidemiological study. *Arch Dis Child.* 2011;96:192–4.
- Zhang Y, Xu CD, Zouche A, Cai W. Diagnosis and management of esophageal achalasia in children: analysis of 13 cases. *World J Pediatric.* 2009;5:56–9.

Carlo De Pieri,^{a,*} Paola Cogo,^a Angelo Barbato^b

^a Division of Pediatrics, Department of Clinical and Experimental Medical Sciences, University of Udine, Udine, Italy

^b Pediatric Bronchoscopy Unit, Department of Women's and Children's Health, University of Padova/General Hospital, Padova, Italy

* Corresponding author.

E-mail address: carlodepieri@gmail.com (C. De Pieri).

An Unusual Cause of Adult Respiratory Distress[☆]



Una causa no habitual de distrés respiratorio del adulto

To the Editor,

Acute fibrinous and organizing pneumonia (AFOP) is a rare histologic interstitial pneumonia pattern described in 2002 by Beasley.¹ It is usually idiopathic, but among the possible causes associated with AFOP, infections, autoimmune diseases, drugs, environmental or occupational exposures, cancers and organ trans-

plantation have all been previously reported.² We report the case of AFOP in a previously healthy woman.

A 43-year-old woman presented to the emergency room (ER) with a 3-day history of worsening dyspnea along with intermittent fever since the previous week. She worked in a school as a teacher, and her personal history was unremarkable except for a smoking habit. She denied recent travels, environmental exposures and had no pets. Physical examination revealed bad general condition with fever, tachypnea, hypotension (95/69 mmHg) and desaturation (oxygen saturation of 89% on room air). Moreover, inspiratory crackles in the base of the right lung were detected. Thorax X-ray

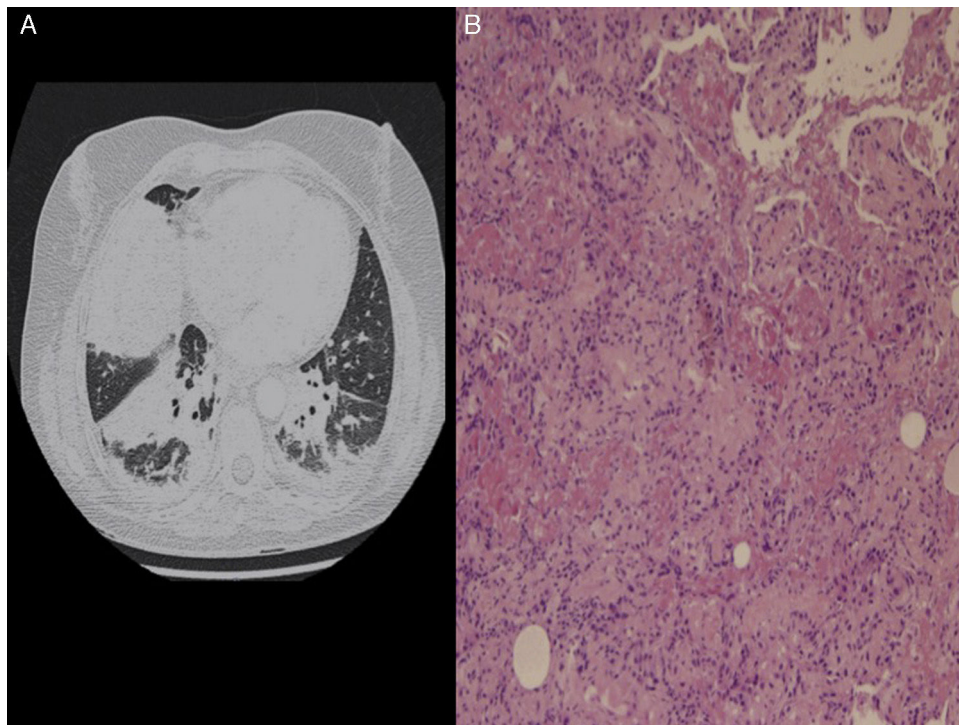


Fig. 1. (A) Thorax with contrast scan: Bibasilar alveolar consolidations, more prominent in the right lung. (B) Lung biopsy: multiple intra-alveolar fibrin "balls" and inflammatory thickening of alveolar septa along with areas of organizing pneumonia with patchy distribution.

[☆] Please cite this article as: Vargas-Hitos JA, Fernández-Muñoz J, Caba-Molina M, Jiménez-Alonso J. Una causa no habitual de distrés respiratorio del adulto. *Arch Bronconeumol.* 2017;53:79–80.