

## Leptomeningeal Carcinomatosis in a Patient With Clinical Stage III Lung Adenocarcinoma and Sudden Neurological Impairment



### *Carcinomatosis leptomeningea en un paciente con adenocarcinoma pulmonar en estadio III y súbito deterioro neurológico*

Dear Editor:

Leptomeningeal carcinomatosis (LC) is a devastating complication for oncologic patients and the optimal therapeutic approach remains a challenge. Lung cancer is one of the most common primary tumors related with LC and Adenocarcinoma is the most frequent histological subtype involved.

We present the case of a 75-year-old man with a long history of smoking who was referred to our Hospital because of an abnormal nodule in the right lung detected by a routine chest radiology. A computed tomography (CT) scan showed a tumor of 30 mm in the right upper lobe with no evidence of nodal involvement. The Positron Emission Tomography (PET) confirmed only glucose uptake by the tumor and there was no evidence of disease at the brain CT. A transthoracic CT-guided tumor biopsy was consistent with a primary adenocarcinoma of the lung. No mutations in epidermal growth factor gene or rearrangement in anaplastic lymphoma kinase were detected. An endobronchial ultrasound was performed with transbronchial needle aspiration of lymphadenopathies in 4R, 10R and 10L stations but pathological analyses were negative for cancer. Finally, a videomediastinoscopy showed evidence of Adenocarcinoma in one node of station 4R. Then, clinical stage III • A (cT2aN2M0) was established (8th Edition of the TNM Classification for Lung Cancer).

The patient presented an Eastern Cooperative Oncology Group performance status of 1 and treatment with chemotherapy and concomitant radiotherapy was planned. However, during the radiotherapy planning, the patient was admitted to our unit with a rapid clinical deterioration of the performance status and headache. The patient presented no fever or other symptomatology. In the physical examination only a mild instability to walk was detected. No papilledema. Presented normal values in serum calcium and ionogram. Blood cultures were negative. Magnetic resonance imaging (MRI) study of the central nervous system was completely normal. A lumbar puncture was performed twice with normal concentrations of glucose and proteins and no pathologic results in cytology and culture analysis of the cerebrospinal fluid. The patient presented progressive clinical worsening with deterioration of the level of consciousness and died after 11 days of hospitalization. An

autopsy was performed showing evidence of isolated tumor cells of lung adenocarcinoma at the meninges (Fig. 1).

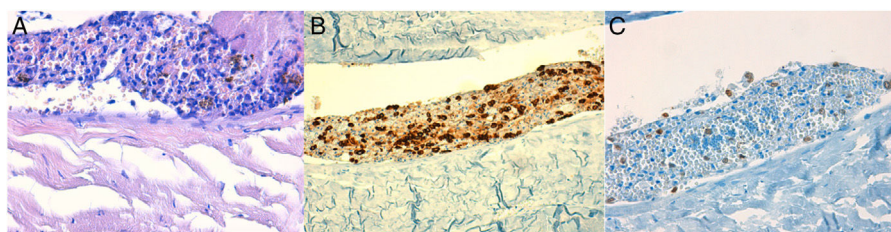
In the present case we describe an atypical presentation of LC patient with a locally advanced lung adenocarcinoma and rapid clinical progression with neurologic impairment. No concise clinical diagnosis of LC or paraneoplastic syndrome could be made and patient died because of a rapid neurological deterioration. Finally, the autopsy was necessary for the diagnosed showing evidence of meningeal dissemination of the disease.

LC is a rare but rapidly fatal clinical condition found in approximately 5•8% of all patients with malignant solid tumors.<sup>1,2</sup> In autopsy series, LC incidence may be 20% or more,<sup>3</sup> suggesting that they are clinically underdiagnosed. Lung cancer is one of the most common primary tumors resulting in LC with an incidence of 4•9% among non-small cell lung cancer population, more frequent in adenocarcinoma subtype.<sup>2</sup> The median survival time is only 4•6 months in selected patients who receive treatment and only 4•8 weeks in patients without treatment.<sup>5</sup> Diagnosis is based on clinical, imaging and cerebral-spinal fluid (CSF) cytological examinations. MRI represent the gold standard for the imaging evaluation and LC involvement is observed in 40•75% of brain and in 15•25% of spine MRI. CSF evaluations are abnormal in more than 90%. However, in up to 30% of LC the CSF cytological analysis is negative.<sup>4</sup> Thus, autopsy is sometimes necessary to get the diagnostic.

In conclusion, LC diagnosis can be a challenge and prognosis is still poor. Nowadays, some trials are being published reporting significant improvement of overall survival with new TKI and immunotherapy agents.<sup>3,5</sup> A correct multidisciplinary management of the disease using those new therapies is a future challenge in cancer patients to improve the prognosis.

## References

1. Lee SJ, Lee JI, Nam DH, Ahn YC, Han JH, Sun JM, et al. Leptomeningeal carcinomatosis in non-small-cell lung cancer patients, impact in survival and correlated prognosis factors. *J Thorac Oncol.* 2013;8:185–91.
2. Beauchesne P. Intrathecal chemotherapy for treatment of leptomeningeal dissemination of metastatic tumors. *Lancet Oncol.* 2010;11:871–9.
3. Remon J, Le Rhun E, Besse B. Leptomeningeal carcinomatosis in non-small cell lung cancer patients: a continuing challenge in the personalized treatment era. *Cancer Treat Rev.* 2017;53:128–37.
4. Chamberlain M, Soffietti R, Raizer J, Rudà R, Brandsma D, Boogerd W, et al. Leptomeningeal metastasis: a response assessment in neuro-oncology critical review of endpoints and response criteria of published randomized clinical trials. *Neuro Oncol.* 2014;16:1176–85.
5. Park JH, Kim YJ, Lee JO, Lee KW, Kim JH, Bang SM, et al. Clinical outcomes of leptomeningeal metastasis in patients with non-small cell lung cancer in the modern chemotherapy era. *Lung Cancer.* 2012;76:387–92.



**Fig. 1.** Histology of neoplastic cells at the meningeal tissue. (A) Epithelial proliferation in relation to meningeal tissue, cytologically formed by neoplastic cells of hyperchromatic small or medium size oval nuclei, with no apparent nucleolus and scarce cytoplasm. (Hematoxylin•eosin staining 40i.) (B) Cytokeratin AE1•AE3 positivity in the neoplastic cells. (Immunohistochemistry.) (C) TTF-1 focal positivity in the neoplastic cells. (Immunohistochemistry.)

Jose Carlos Benítez,<sup>a</sup> Romà Bastús,<sup>a</sup> Luis Luizaga,<sup>b</sup> Luis Cirera,<sup>a</sup>  
Marc Campayo<sup>a,\*</sup>

<sup>a</sup> Department of Medical Oncology, Hospital Universitari Mutua  
Terrassa, Terrassa, University of Barcelona, Barcelona, Spain

<sup>b</sup> Department of Pathology, Hospital Universitari Mutua Terrassa,  
Terrassa, University of Barcelona, Barcelona, Spain

\* Corresponding author.

E-mail address: [mcampayo@mutuaterrassa.es](mailto:mcampayo@mutuaterrassa.es) (M. Campayo).

1579-2129/

© 2018 SEPAR. Published by Elsevier España, S.L.U. All rights reserved.

## Safety of a Modified Protocol of Bronchial Thermoplasty



### Seguridad de un protocolo modificado de termoplastia bronquial

Dear Editor:

Bronchial thermoplasty (BT) is a new endoscopic treatment for severe and uncontrolled asthma patients despite adequate medical treatment.<sup>1</sup> BT applies radiofrequency (RF)-produced heat to the bronchial wall. Clinical trials have observed improvement in quality of life and fewer exacerbation rates.<sup>2</sup> The proposed mechanism for improvement in asthma control is the reduction in the amount of airway smooth muscle (ASM) and consequent reduction in the airway hyperresponsiveness. Reduction of ASM induced by BT has been observed in animal models<sup>3</sup> and small case series.<sup>4,6</sup>

BT treatment requires three different bronchoscopy sessions (right lower lobe (RLL), left lower lobe (LLL) and upper lobes (UL), respectively) separated each other by a minimum of 3 weeks. The catheter is introduced into the working channel of the bronchoscope and placed in visible airways from distal to proximal guided by 5 mm distance marks. The technique description advises not to lose visual contact with the distal extreme of the catheter, where the electrodes are placed (Fig. 1(a)).<sup>7</sup> The amount of bronchial mucosa treated is limited to accessible airways where the tip of the catheter can be observed from bronchoscopic vision.

Considering BT as a locally applied treatment, there is controversy whether the number of activations and the extension of the treated area might have an influence in clinical response. Some authors suggest that the thermoplasty effect might be also related to regional changes induced by neurogenic mechanisms while others found that higher number of activations were related to better response to BT, measured by the Asthma Control Questionnaire Score (ACQ-5).<sup>8</sup>

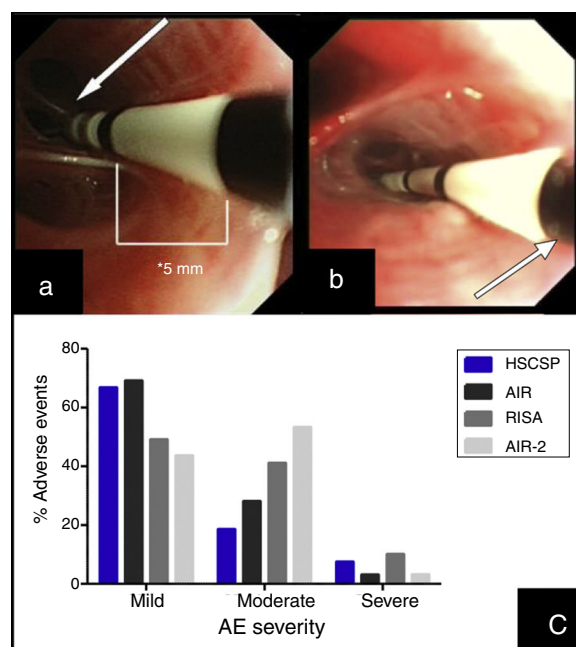
This article describes a little modification in the published protocol, allowing further introduction of the catheter into smaller airways, losing visual contact with the distal extreme of the catheter but not with the last black mark, placed at 2 cm of the electrode wire (Fig. 1(b)). We hypothesized that this modification might increase the treated bronchial area (at least 2 cm each bronchus) and thus might have a potential benefit in the clinical response without increase in side effects.

Approval for this study was obtained by the Clinical Research Ethics Committee of our center (approval number: EC/12/103/1388) and patients included signed informed consent. We included all severe and uncontrolled asthma patients<sup>1</sup> accepted for BT by an expert asthma team in our center since September 2012. Other inclusion criteria were: >18 years old, uncontrolled disease (maintained *Asthma Control Test* [ACT] score <19; ≥2 exacerbations in the previous year) and impaired quality of life (maintained shorter version of the *Asthma Quality of Life* [AQLQ] score <6.5). Subjects were excluded if: contraindication for bronchoscopy, allergy to sedative drugs, implantable devices, current

smokers, past smoking habit of >15 pack-years, other respiratory diseases such as emphysema or bronchiectasis, concomitant non-respiratory diseases, such as severe cardiopathies, that could contribute to impaired control of asthma.

BT was performed with the modified procedure in three different sessions. Patients were deeply sedated with remifentanyl and propofol, and intubated (Bronchoflex 7.5 mm, Rñ/4sch, Teleflex Medical, Durham, NC, USA) to achieve a better control of cough.

We collected the length of the procedure, number of activations, adverse events (AE) during each BT session and in the first 24 h after. AE were classified as described previously<sup>10</sup> into: mild (transient symptoms well tolerated not interfering with normal activities, and that did not required treatment except by short-acting bronchodilators; bleeding during bronchoscopy that did not required any specific measure for its resolution); moderate (symptoms that caused interference with patient's usual activities; symptomatic treatment is possible; bleeding during bronchoscopy that requires aspiration during >3 s); and severe (signs or symptoms causing inability to do work or usual activities, requiring medical intervention and/or treatment; bleeding during bronchoscopy that leads to stop the procedure).



**Fig. 1.** (a) Insertion of the catheter up to distal airway without losing visual contact with the electrodes (arrow) according to established protocol. (b) Introduction of the catheter with loss of visual contact with the electrodes wire, but not with the last black mark (arrow), located at 2 cm from the electrodes wire. (c) Occurrence of adverse events in different series: our Hospital de la Santa Creu I Sant Pau are the sum of AE observed during the procedure and the 24 h after (percentages are calculated from the 27 modified procedures); AIR: Asthma Intervention Research<sup>9</sup>; RISA; Research in Severe Asthma<sup>10</sup>; AIR-2.<sup>11</sup>