

Clinical Image

Substernal Goiter with Carinal Involvement Presenting as Mediastinal Mass



Bocio substernal con afectación carinal que se presenta como masa mediastínica

Vahit Mutlu<sup>a</sup>, Yener Aydın<sup>b</sup>, Hayri Oğul<sup>c,\*</sup>

<sup>a</sup> Department of Otolaryngology, Faculty of Medicine, Ataturk University, Erzurum, Turkey

<sup>b</sup> Department of Thoracic Surgery, Medical Faculty, Ataturk University, Erzurum, Turkey

<sup>c</sup> Department of Radiology, Medical Faculty, Ataturk University, Erzurum, Turkey

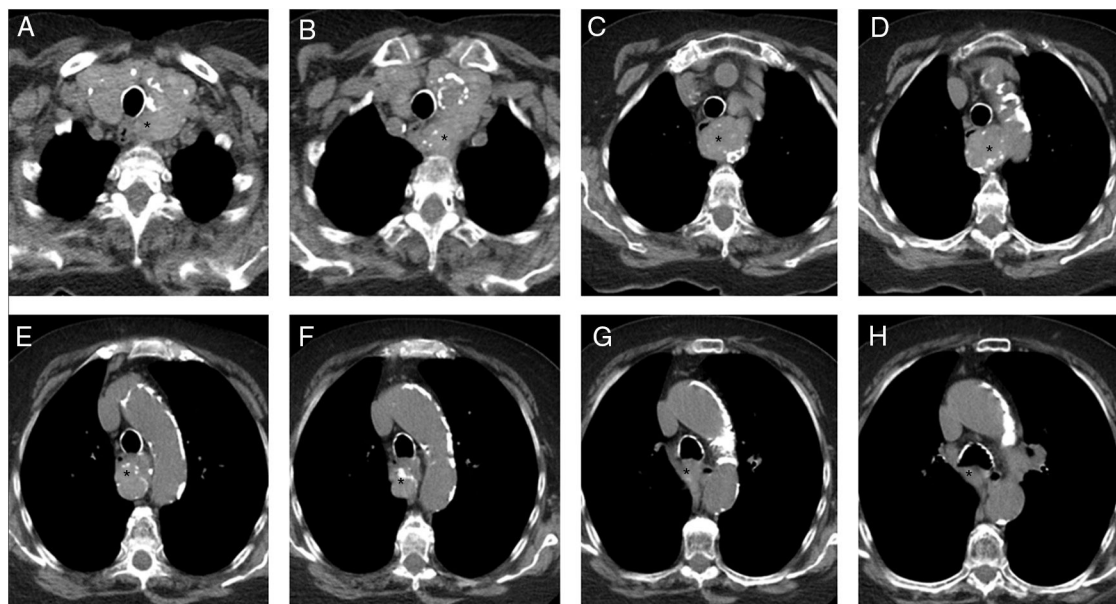


Fig. 1. Non-contrast consecutive CT scans of the chest demonstrated a large calcified mass (asterisk). The mass extends to carina level.

A 50-year-old man was referred to thoracic surgery clinic with shortness of breath. The patient had no history of smoking. There was no history of trauma. Physical examination was normal. Blood biochemistry and hematocrit were normal. Anteroposterior chest radiograph showed a mediastinal enlargement. Non-contrast computed tomography (CT) imaging of the chest demonstrated a large mass (Fig. 1A-H) in the posterior mediastinum displacing the esophagus to the anterior. The mass originating left thyroid lobe was extending to the level of the carina. CT results were considered

pathognomonic for substernal goiter. Surgical treatment was not performed because the patient refused operation.

Substernal goiter uncommonly extends to carina level. Substernal or carinal goiter may cause pericardial effusion or tracheal compression. Severe airway obstruction may rarely require anesthesia.<sup>1</sup> CT easily reveals evidences of tracheobronchial tree obstruction.

Reference

1. Tan PC, Esa N. Anesthesia for massive retrosternal goiter with severe intrathoracic tracheal narrowing: the challenges imposed -A case report-. Korean J Anesthesiol. 2012;62:474-8.

\* Corresponding author.  
E-mail address: drhogul@gmail.com (H. Oğul).