

Case Report

## Hypersensitivity Pneumonitis-like Histological Findings Secondary to SARS-COV-2 Pneumonia

Cristina Aljama<sup>a</sup>, María Florencia Pilia<sup>b,c</sup>, Iñigo Ojanguren<sup>a,b,c,\*</sup>

<sup>a</sup> Servei de Pneumologia, Hospital Universitari Vall d'Hebron, Departament de Medicina, Universitat Autònoma de Barcelona (UAB), Barcelona, Spain

<sup>b</sup> Vall d'Hebron Institut de Recerca (VHIR), Barcelona, Spain

<sup>c</sup> CIBER de Enfermedades Respiratorias (CIBERES), Barcelona, Spain

Pneumonia by SARS-CoV-2 may induce a wide spectrum of pulmonary sequelae, with diffuse interstitial pulmonary involvement that may lead to pulmonary fibrosis being of note.

Viruses may be an environmental trigger of autoimmunity in genetically predisposed individuals, with viral infections being known modulators of immune response. In this sense, viral infection by SARS-CoV-2 could produce a Th1 inflammatory response which would present common zones with the pathogenesis of hypersensitivity pneumonitis (HP) leading to an entity of similar characteristics after the initial infection, although no case series have been described to date.<sup>1</sup>

Between May 2020 and December 2021, 2586 patients were admitted in our hospital due to COVID-19 pneumonia and all were followed in the respiratory outpatient clinics. During the follow-up, all the patients underwent a high-resolution computerized tomography (HRCT) and lung function tests within three months of hospital discharge. Sixty-eight cases presented sequelae of interstitial lung involvement, requiring the performance of a transbronchial cryobiopsy in order to investigate the aetiology. A number of 5 out of 68 cryobiopsies showed findings mimicking HP (7.35%) and these cases were carefully reviewed by the expert multidisciplinary interstitial lung disease team and other causes of HP were excluded.<sup>2</sup> Regarding these 5 patients, the mean age was 59 years (p25–p75 57–63 years), 4 were men (4/5), 3 were ex-smokers and arterial hypertension was the most frequent comorbidity (2/5). None had presented previous lung disease. Regarding their admission for COVID pneumonia, all were diagnosed by polymerase chain reaction, 3 required orotracheal intubation and admission to the intensive care unit (ICU), while the other 2 only required low-flow oxygen therapy in a conventional ward. All the included patients were on wide spectrum systemic antibiotics during their admission encompassing ceftriaxone, azithromycin or meropenem. Four of them also received hydroxychloroquine (for 5 days) and lopinavir/ritonavir (for 2 days), and another patient received 2 doses of tocilizumab according to the local recommen-


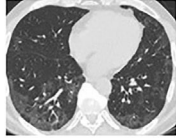
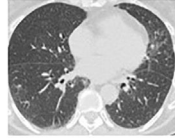

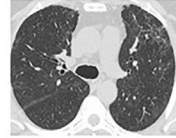
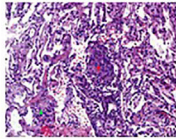
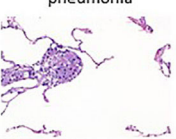
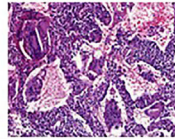
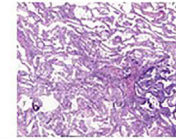
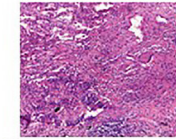
dations during that period. While pneumonitis has been described in context of hydroxychloroquine and ritonavir, it is very unlikely that in the presented clinical frame these drugs were the cause of the described histological findings. In the HRCT performed, the predominant findings were patchy pulmonary opacities and bilateral ground glass images with peripheral linear and reticular densities. Pulmonary function test in all these patients showed a non-obstructive ventilatory disorder with a reduction in the diffusing capacity of the lungs for carbon monoxide (DLCO). A common biopsy finding was patchy pneumonitis with interstitial granulomas. Lymphocyte infiltrate was present in 3 cases, while giant cell clusters presented also in 3 cases (Fig. 1).

Although the hypothesis of the relationship between SARS-CoV-2 and HP had previously been suggested by other authors,<sup>3</sup> to our knowledge this is the first study to describe a cases serie showing histological involvement compatible with HP in patients with diffuse interstitial disease as a sequela of COVID pneumonia. The agents that trigger the immune reaction and the disease varies and more than 100 causes have been described, including a viral aetiology. In fact, other ribonucleic acid viruses such as influenza or syncytial respiratory virus have been described as being involved in the aetiology of HP.

HP is a lung disease caused by immune response to a variety of inhaled antigens, producing inflammation at the bronchioalveolar level in genetically predisposed individuals. Progression of the sensitization to HP requires the accumulation of CD4+ Th1 cells in the lung, creating a proinflammatory microenvironment that precipitates the disease.<sup>4</sup> During the cell response derived from SARS-COV-2 infection, once exposed to the antigen, the Th0 cells mainly polarize to Th1, leading to the release of IFN- $\gamma$  to eliminate the virus. In predisposed individuals, the cellular response of the T cells may be suboptimal, deteriorated or excessive in patients with COVID-19, perpetuating a proinflammatory pulmonary status.<sup>5</sup>

Thus, taking into account that SARS-CoV-2 launches a mechanism of T1 cell response and HP is produced by predominantly T1 cellular response, it is likely that after the infection, common inflammatory pathways are activated and produce HP-like histological findings as observed in the present study. Thus, this

\* Corresponding author.  
E-mail address: [inigo.ojanguren@vallhebron.cat](mailto:inigo.ojanguren@vallhebron.cat) (I. Ojanguren).

Patient number	1	2	3	4	5
Age	56	64	57	63	57
Gender	Man	Man	Woman	Man	Man
Smoking (pack/year)	0	25	0	7	40
Pneumological history	No	No	No	No	No
Days of admission	51	11	6	47	45
Maximum respiratory support	Orotracheal intubation	Not required	Not required	Orotracheal intubation	Orotracheal intubation
FVC (L) (%)	2.55 (62%)	4.6 (105%)	2.16 (68%)	4.6 (112%)	3.6 (93%)
FEV1 (L)	2.16 (67%)	3.6 (106%)	1.73 (68%)	3.98 (124%)	3.1 (104%)
DLCO (%)	50	69	42	67	70
CT	Ground glass and reticulation 	Ground glass and reticulation 	Ground glass 	Ground glass and reticulation 	Ground glass and reticulation 
BAL cytology	M 55%; L 38%; PMN 5%; E 2%	M 87%; L 10%; PMN 3%; E 0%	M 31%; L 67%; PMN 2%; E 0%	M 90%; L 8%; PMN 2%; E 0%	M 97%; L 2%; PMN 1%; E 0%
Biopsy	Interstitial granulomas and Masson bodies 	Interstitial granulomas and collagenized organizing pneumonia 	Interstitial granulomas and giant cells 	Giant cells and pigmented macrophages 	Giant cells and lymphocytic infiltration 

\*Abbreviations FVC: Forced vital capacity; FEV1: Forced expiratory volume in the first second; DLCO: diffusing capacity of the lungs for carbon monoxide; CT: computed tomography; BAL: Bronchoalveolar Lavage; M: macrophages; L: lymphocytes; PMN: polymorphonucleated; E: eosinophils

Fig. 1. Characteristics of the study population.

subgroup of patients may benefit from a more specific treatment, in terms of dosage and duration of oral corticosteroids and immunosuppressants that may be closer to the management of HP.

### Conflict of Interest

IO declares to have received honoraria in the last three years for participating as a speaker in meetings sponsored by Astrazeneca, Boehringer-Ingelheim, Chiesi, and Novartis and as a consultant for Astrazeneca, GlaxoSmithKlein, Puretech and Sanofi. He received financial aid from Astrazeneca, Bial and Chiesi for congress attendance and has received grants from Sanofi for research projects.

### References

1. Limongi F, Fallahi P. Hypersensitivity pneumonitis and alpha-chemokines. Clin Ter [Internet]. 2017;168:140–5 [cited 27.01.23].
2. Raghu G, Wilson KC, Bargagli E, Bendstrup E, Chami HA, Chua AT, et al. Diagnosis of hypersensitivity pneumonitis in adults. An official ATS/JRS/ALAT clinical practice guideline. Am J Respir Crit Care Med [Internet]. 2020;202:E36–69 [cited 27.01.23].
3. Sanchez-Gonzalez MA, Moskowitz D, Issuree PD, Yatzkan G, Rizvi SAA, Day K. A pathophysiological perspective on COVID-19's lethal complication: from viremia to hypersensitivity pneumonitis-like immune dysregulation. Infect Chemother [Internet]. 2020;52:335–44 [cited 27.01.23].
4. Costabel U, Miyazaki Y, Pardo A, Koschel D, Bonella F, Spagnolo P, et al. Hypersensitivity pneumonitis. Nat Rev Dis Primers [Internet]. 2020;6 [cited 27.01.23].
5. Toor SM, Saleh R, Sasidharan Nair V, Taha RZ, Elkord E. T-cell responses and therapies against SARS-CoV-2 infection. Immunology [Internet]. 2021;162:30–43 [cited 27.01.23].