

Clinical Image

Unusual Cause of Bronchial Obstruction: Tracheobronchial Amyloidosis



Una causa poco frecuente de obstrucción bronquial: amiloidosis traqueobronquial

Veysel Ayyildiz^a, Yener Aydin^b, Hayri Ogul^{c,*}

^a Department of Radiology, Medical Faculty, Suleyman Demirel University, Isparta, Turkey

^b Thoracic Surgery, Medical Faculty, Ataturk University, Erzurum, Turkey

^c Department of Radiology, Medical Faculty, Ataturk University, Erzurum, Turkey

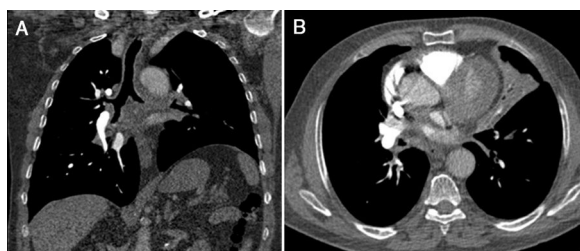


Fig. 1. (A) Post-contrast coronal CT scan reveals diffuse thickened tracheobronchial wall. (B) Axial CT scan shows atelectasi in the lingular segment of the left upper lobe.

A 60-year-old male presented with complaints of chronic cough, occasional mucus secretion, and dyspnea. Coronal CT scans revealed diffuse thickened tracheobronchial wall (Fig. 1A). Axial CT scan showed atelectasi in the lingular segment of the left upper lobe (Fig. 1B). Three-dimensional volume-rendered air-specific coronal plan MDCT image (Fig. 2A) and virtual CT bronchoscopy (Fig. 2B) demonstrated obstruction of the left main bronchus. Bronchoscopic biopsy diagnosed diffuse tracheobronchial amyloidosis.

Primary tracheobronchial amyloidosis has rarely been reported in the literature.^{1,2} There is no relationship between endobronchial amyloidosis and systemic amyloidosis.¹ The endobronchial involvement can mimic a tumoral lesion. Although it is very rare,

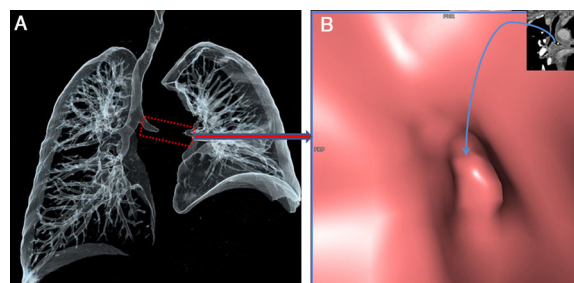


Fig. 2. Three-dimensional volume-rendered air-specific coronal plan MDCT image (A) and virtual CT bronchoscopy (B) demonstrate obstruction (frame and arrow) of the left main bronchus.

tracheobronchial amyloidosis should be considered in case of bronchial obstruction.

References

1. Lal A, Akhtar J, Khan MS, Chen Y, Goldman Y. Primary endobronchial amyloidosis: a rare case of endobronchial tumor. *Respir Med Case Rep.* 2018;23:163–6.
2. Berraondo J, Novella L, Sanz F, Lluch R, de Casimiro E, Lloret T. Management of tracheobronchial amyloidosis with therapeutic bronchoscopic techniques. *Arch Bronconeumol.* 2013;49:207–9.

* Corresponding author.
E-mail address: drhogul@gmail.com (H. Ogul).