

Organising Pneumonia Associated with Psoriasis

Neumonía organizada asociada a psoriasis

To the Editor:

Organising pneumonia, formerly known as bronchiolitis obliterans with organising pneumonia, is an interstitial pulmonary disease which was first recognised in 1985.¹ Since then, many cases of this entity have been described. On occasions it is not related to a specific cause and is called cryptogenic organising pneumonia, but it is often associated with another aetiology. Psoriasis is a chronic inflammatory disease which can occasionally have pulmonary manifestations. Here, the case of a patient is described in which both entities can be clearly related.

We present the case of a 51 year old woman with a 20 year history of psoriasis, the diagnosis of which was confirmed histopathologically and not treated. One month earlier she had begun with a dry cough and progressive dyspnoea, with an exacerbation of her psoriasis lesions, so she consulted doctors in a different centre to ours, where she underwent chest x-rays. As these showed bilateral opacities, together with the symptoms stated above, she was prescribed antibiotics. The same symptoms continued, and she began to suffer mild fever. She was prescribed 2 more courses of antibiotics, but as no improvement was evidenced she decided to consult our centre. At the time of the consultation she had a temperature (38.3° C), tachypnoea (36x') and dry rales in both lower lung fields. Oxygen saturation was 82%. Faced with these symptoms she was admitted and given oxygen, non-invasive ventilation (NIV) and other support in the ICU. She was given a chest x-ray (fig. 1A), which showed opacities in both bases. Tests showed a leukocyte count of 9,300 μ l, GSV of 83mm, blood Ph of 7.43, arterial oxygen pressure of 53mmHg, carbonic anhydride pressure of 32mmHg and oxygen saturation of 83%. The analysis included a haemogram and a complete hepatogram

and the levels of creatinine, urea, calcium, sodium, potassium, total proteins, albumin, thyrotropin and cholesterol were all normal. A high resolution CT chest scan revealed extensive patchy areas with occupation of the alveolar air space and other areas of ground-glass opacity in both lower lobes with areas of air bronchogram (fig. 1B). In view of these findings, the patient underwent bronchoscopy with bronchoalveolar lavage (BAL) and transbronchial biopsies in the segments that the CT scan showed were most affected. Treatment with corticosteroids (meprednisone) was begun immediately at a dose of 1.5mg/kg. The result of the BAL was negative for tuberculosis, fungal infection and common bacteria, and showed a predominance of lymphocytes. Collagen levels were normal, and serological tests for HIV and mycoplasma, chlamydia and cytomegalovirus were all negative. The results of the biopsies yielded a diagnosis of organising pneumonia. The patient made good progress in the following days and on the fourth day she was moved to a general ward, where an x-ray was performed showing clear improvement. Oxygen saturation was 94% and a spirometry test produced a forced expired volume (FEV₁) of 67% and a forced vital capacity (FVC) of 58%. The distance walked in the 6 min test was 374m, reaching a minimum saturation of 88%. The patient was discharged and given a course of meprednisone at a dose of 60mg/day. She was monitored in the outpatient clinic and a clear improvement in the clinical symptoms and oxygen saturation was evidenced. One month later, spirometry yielded a FEV₁ of 79% and FVC of 71%. The distance walked in the 6 min test was 453m, with a minimum saturation of 93%. A CT scan was performed which revealed that minimal infiltration persisted in the lower lobes (fig. 1C). After 3 months of steroid treatment with decreasing doses, the CT scan revealed the patient had no symptoms (fig. 1D). It showed that the opacities had disappeared almost completely; she had a FEV₁ of 83%, a FVC of 84% and she walked 519m in the 6 min test without oxygen desaturation.

Organising pneumonia is an interstitial lung disease characterised by the presence of subacute symptoms including cough, dyspnoea and a high temperature, with radiological manifestations characterised by alveolar and interstitial infiltrates, which sometimes migrate.² The most common findings from computerised tomography are parenchymal consolidation, ground glass opacity, bronchial dilation and centrilobular nodularity.³ The histopathological symptoms are non-specific tissue repair with distal air spaces occupied by buds of loose fibroinflammatory tissue which extend from one alveolar to another through Kohn's pores and cause a patchy distribution of the affectation around small airways. The symptoms may be secondary to diverse aetiologies, amongst which are drugs, toxins, infections, autoimmune diseases and radiotherapy, or what is known as cryptogenic organising pneumonia when the cause is unknown.² A transbronchial or surgical biopsy is necessary to confirm the diagnosis histopathologically, and the treatment of choice are oral corticosteroids, which are associated with a positive response in most cases.⁴ The previous name bronchiolitis obliterans with organising pneumonia was replaced by consensus by the term organising pneumonia, which defines the location of the inflammatory process better.

Psoriasis is an inflammatory skin disease in which flare-ups may occur. There is a well-documented link between psoriasis and: certain lung diseases, such as acute respiratory distress syndrome; some interstitial diseases, such as usual interstitial pneumonia; chronic obstructive pulmonary disease; and even sarcoidosis. In this case we found that the pulmonary complications of the psoriasis, which was in an exacerbation phase, were organising pneumonia, which was confirmed by a pathological anatomical study. It responded excellently to steroid treatment, as did the psoriasis symptoms.

We performed a thorough search of the literature but found only 2 cases of psoriasis with organising pneumonia. One was an acute cytomegalovirus infection, so psoriasis was assumed to be secondary to this virus.⁵ In the other case it is hard to say for certain, but

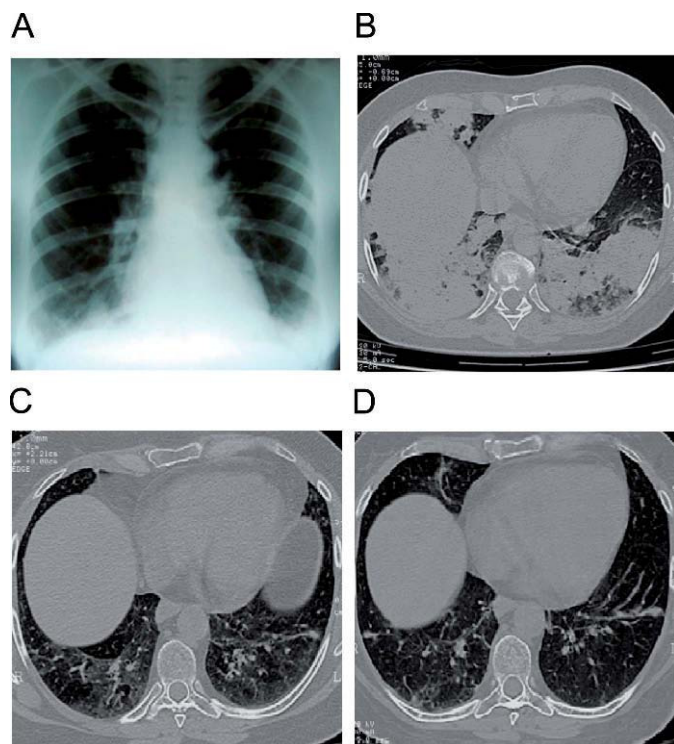


Figure 1. A) X-ray on admission. B) CT scan on admission. C) One month after treatment. D) 3 months after treatment.

psoriasis cannot be ruled out as the cause of the lung disease; however, the patient had a history of treatment with methotrexate and cyclosporine and during hospital admission she was given many drugs which could have caused the lung affection, amongst which was acitretine, which has a well-documented link with interstitial damage.⁶ In the case of the patient we are reporting, she did not receive any medicine to justify the symptoms, and all the bacteriological studies performed were also negative. Likewise, the response to steroids alone was very good from both the point of view of the lungs and the skin, so we inferred that there was a clear association between the 2 entities, and this is the first reported case which links, beyond all doubt, organising pneumonia with psoriasis.

To conclude, we must say that psoriasis patients can have lung manifestations and that organising pneumonia may be just another kind of lung affection caused by this skin disease.

References

1. Epler GR, Colby TV, Mc Loud TC, Carrington CB, Gaensler EA. Bronchiolitis obliterans organizing pneumonia. *N Eng J Med*. 1985;312:152-8.
2. Cordier JF. Cryptogenic organizing pneumonia. *Clin Chest Med*. 2004;25:727-38. vi-vii. Revision.
3. Bravo Soberón A, Torres Sánchez MI, García Río F, Sánchez Almaraz C, Parrón Pajares M, Pardo Rodríguez M. Patrones de presentación de la neumonía organizada mediante tomografía computarizada de alta resolución. *Arch Bronconeumol*. 2006;42:413-6.
4. Xaubet A, Ancochea J, Blanquer R, Montero C, Morell F, Rodríguez Becerra E, et al. Diagnóstico y tratamiento de las enfermedades pulmonares intersticiales difusas. *Arch Bronconeumol*. 2003;39:580-600.
5. Messina M, Scichilone N, Guddo F, Bellia V. Rapidly progressive organizing pneumonia associated with cytomegalovirus infection in a patient with psoriasis. *Monaldi Arch Chest Dis*. 2007;67:165-8.
6. Webber NK, Elston CM, O'Toole EA. Generalized pustular psoriasis and cryptogenic organizing pneumonia. *Br J Dermatol*. 2008;158:853-4.

Miguel Penizzotto,^{a,*} Mariela Retegui,^b and María Florencia Arrién Zucco^c

^aServicio de Neumonología, Sanatorio San Roque, Curuzú Cuatiá, Corrientes, Argentina

^bServicio de Anatomía Patológica, Sanatorio San Roque, Curuzú Cuatiá, Corrientes, Argentina

^cServicio de Diagnóstico por Imágenes, Sanatorio San Roque, Curuzú Cuatiá, Corrientes, Argentina

*Corresponding author.

E-mail address: penitato@curuzu.net (M. Penizzotto).

Round Pneumonia: A Rare Cause of Multiple Pulmonary Nodules

Neumonía redonda: una causa poco habitual de nódulos pulmonares múltiples

To the Editor:

Round pneumonia (RP) is a very uncommon cause of solitary pulmonary nodules and it is more infrequent in adults than in children. In rare cases it may present as multiple nodules and resemble diffuse tumours of the pulmonary parenchyma. We present the case of a female patient aged 56 with a history of bronchial asthma and a smoking habit of 50 cigarettes per day. She arrived at our hospital with a clinical profile of pleuritic pain in the left hemithorax, dry cough, night sweats, high fever, asthenia and weight loss of 2kg in the course of 5 days. The general physical examination was normal, except for auscultation which detected a few isolated rales in the left hemithorax. There were no signs of cyanosis, acropachy or adenopathy on any level. The clinical profile and the haematological and biochemical parameters pointed to an infectious origin: leukocytosis (15,800/mm³), elevated C-reactive protein (33.4UI) and globular sedimentation rate (62mm/h), but the chest radiography showed several pulmonary nodules. For that reason, we decided to admit the patient for study in order to rule out a neoplastic origin for the nodules. In addition, oral antibiotic treatment was initiated with levofloxacin (500mg/24 h) and a chest CT was ordered. The study was amplified to include microbiology tests, tumour markers and immunology tests. These gave negative results except for antigenaemia in urine, which was positive for pneumococcus. Two days after admission, her respiratory symptoms had improved. After the patient had been hospitalised for seven days, new analytical and radiology tests were ordered. The tests showed that the abnormal blood parameters had become normal and the pulmonary nodules had resolved; resolution was confirmed by the CT, which showed none of previously described lesions and no adenopathies on any

level. Antibiotic treatment was continued over 10 days, and it was decided to discharge the patient and monitor her on an outpatient basis. Based on the results, the patient was diagnosed with multiple-lesion RP of pneumococcal origin. Six months after the episode, the patient is asymptomatic with normal blood tests and with no radiological evidence of a relapse (Fig. 1).

RP is a rare subtype of lobar pneumonia which arises due to a developmental defect in connective tissue (pores of Köhn and channels of Lambert). While this is a well-known entity in childhood (it mainly affects children younger than eight), it has hardly ever been described in adults. It normally presents as a single nodule or mass-shaped lesion in the context of a profile suggesting a respiratory infection. There are few cases describing a presentation with multiple nodular modules or a main nodule with several satellite lesions, which makes this case especially important: the presentation may resemble tumour involvement, particularly where a family history and risk factors are present. The symptoms and the abnormalities in the analysis are size-related¹ and fit the usual profile (fever, cough, dyspnoea, chest pain, leukocytosis, elevated C-reactive protein and globular sedimentation rate). It often happens that this pneumonia is not detected in adults and appears as a casual finding in asymptomatic patients. In the radiology study,¹⁻³ RP may present as a nodule with a diameter of up to 7cm located in the inferior and posterior lobes adjacent to the pleura; it can appear in an air bronchogram with smooth or poorly defined edges, and satellite lesions are possible. Although microbial aetiology is quite varied, most cases in children and adults alike are attributed to *Streptococcus pneumoniae*. However, other authors⁴ defend the hypothesis that Q fever is the most common cause of RP in adults, especially in the case of multiple lesions. The differential diagnosis⁵ mainly includes neoplasias, especially if the lesions are found in the upper lobes (bronchioloalveolar carcinoma, metastasis or lymphomas); other infections (hydatid cysts, parasitic and opportunistic infections or septic embolism); immunological causes (sarcoidosis or Wegener); metabolic or vascular causes (arterial and venous malformations)