

.to that of water (0-20 Hounsfield units) or even lower, and therefore can be diagnosed reliably.^{4,5} However, in 50% of all patients, cysts have a higher attenuation similar to that of a soft-tissue injury.⁵ This increase in attenuation can be caused by an infection in the cyst or by high levels of proteins or calcium oxalate in the cyst's mucoid content.⁵ When the CAT scan does not permit differential diagnosis, magnetic resonance imaging is useful for establishing the nature of the lesion's liquid content.⁴ In our case, the high probability of neoplasia led us to think that the upper right paratracheal lesion could be an adenopathy, but it was found to be an incidental mediastinal cyst.

EBUS easily detects mediastinal cysts: it distinguishes them from vascular structures due to their lack of Doppler flow signal, and also enables cytological diagnosis and treatment by draining.

References

1. Adams K, Shah PL, Edmonds L, Lim E. Test performance of endobronchial ultrasound and transbronchial needle aspiration biopsy for mediastinal staging in patients with lung cancer: Systematic review and meta-analysis. *Thorax*. 2009;64:757-62.

2. Nakajima T, Yasufuku K, Shibuya K, Fujisawa T. Endobronchial ultrasound-guided transbronchial needle aspiration for the treatment of central airway stenosis caused by a mediastinal cyst. *Eur J Cardiothorac Surg*. 2007;32:538-40.
3. Galluccio G, Lucantoni G. Mediastinal bronchogenic cyst's recurrence treated with EBUS-FNA with a long-term follow-up. *Eur J Cardiothorac Surg*. 2006; 29:627-9.
4. Takeda S, Miyoshi S, Minami M, Ohta M, Masaoka A, Matsuda H. Clinical spectrum of mediastinal cysts. *Chest*. 2003;124:125-32.
5. Patel SR, Meeker DP, Biscotti CV, Kirby TJ, Rice TW. Presentation and management of bronchogenic cysts in the adult. *Chest*. 1994;106:79-85.
6. St-Georges R, Deslauriers J, Duranceau A, Vaillancourt R, Deschamps C, Beauchamp G, et al. Clinical spectrum of bronchogenic cysts of the mediastinum and lung in the adult. *Ann Thorac Surg*. 1991;52:6-13.

María Meseguer Sisternes* and José Franco Serrano

Servicio de Neumología, Hospital Clínico Universitario de Valencia, Valencia, Spain

*Corresponding author.

E-mail address: mamesis@comv.es (M. Meseguer Sisternes).

Radiological Findings of Pulmonary Involvement of Type B Niemann-Pick Disease

Hallazgos radiológicos de afectación pulmonar por enfermedad de Niemann-Pick tipo B

To the Editor:

Niemann-Pick disease is a recessive, autosomal hereditary lysosomal storage disease. Deficient activity of acid sphingomyelinase causes build-up, mainly sphingomyelin, in central nervous system and reticuloendothelial system tissues. Depending on which organs are affected, there are various clinical subdivisions of Niemann-Pick disease. The most severe of the six disease subtypes is type A, which has an acute neuronopathic phenotype tending to cause death in early childhood. Type B is a heterogeneous disorder that presents in most patients without affecting the nervous system. Progressive pulmonary disease, hepatosplenomegaly, short stature and pancytopenia may be present where involvement is systemic.

Our patient is a seven-year old girl. At nine months old, she was examined in the hospital due to abdominal distension. Hepatosplenomegaly was observed and the patient underwent a fine-needle aspiration biopsy of the liver. The diagnosis was Niemann-Pick type B. She presented dry cough and a fever. Physical exploration revealed hepatomegaly and splenomegaly. Cardiovascular and neurological examinations were normal. Pulmonary auscultation revealed pronounced crackling stertor in the lung bases. The kidney and liver function tests were normal. Laboratory findings revealed mild anaemia. After a clinical examination, the patient was referred to our centre for a chest radiography and high-resolution computed tomography (HRCT). Postero-anterior radiography revealed diffuse reticulonodular infiltration at the base of both lungs. The HRCT tests were performed without intravenous contrast. A multi-slice spiral computed tomography scan was performed using a 16-slice CT system (Somatom Sensation 16, Siemens, AG, Erlanger, Germany). Gantry rotation time was 0.5 sn. We used a tube with 100kVp voltage and a tube with 40mA (effective) current. The slice thickness was 1mm, with a slice interval of 9mm. An edge-detection filter was used. The

chest HRCT detected areas with a ground-glass appearance in the left lung (in the anterior segment of the upper lobe and in the lingula). We observed peribronchovascular interstitial thickening and interlobular septal thickening in the lung bases. We also detected multiple pulmonary nodules in both lungs.

Niemann-Pick disease is a rare recessive and autosomal hereditary disease characterised by the accumulation of sphingomyelin due to a sphingomyelinase production deficiency. Excess sphingomyelin is deposited in the liver, the spleen, the lungs, the bone marrow or the brain.^{1,2} The radiographic appearance of this condition is not specific, although we do observe linear streaks associated with nodular infiltrations, producing a honeycomb effect that extends diffusely to all areas of the lungs, particularly at the base.¹⁻³ The high-resolution tomography image showed thickening of the interlobular septa, without nodules, predominantly in the inferior area of the lungs. This was associated with more abundant ground-glass opacities in the superior and medial areas.⁴ Although these regions are often separate from each other, they were intermixed at some locations. Intermixed regions are characterised by having a "crazy paving" appearance. Although this is not the most common profile, Niemann-Pick type B should be added to the list of diseases that can present this appearance.⁵ Progressive pulmonary infiltration is an important cause of morbidity and mortality. To date, no successful treatments for lung damage caused by Niemann-Pick disease have been recorded. Complete pulmonary lavage seems to be a potentially useful treatment.⁶

In our case, we observed a ground-glass appearance, peribronchovascular interstitial and interlobular septal thickening, and pulmonary nodules in both lungs. All of these findings were determined with the HRCT technique, and are important for determining the existence of interstitial lung disease.

In conclusion, we must consider the possibility of a lung condition with lipid storage disorders, especially in children. The most reliable radiological technique to confirm it is HRCT (Fig. 1).

References

1. Muntaner L, Galms A, Chabas A, Herrera M. Imaging features of type-B Niemann-Pick disease. *Eur Radiol*. 1997;7:361-4.

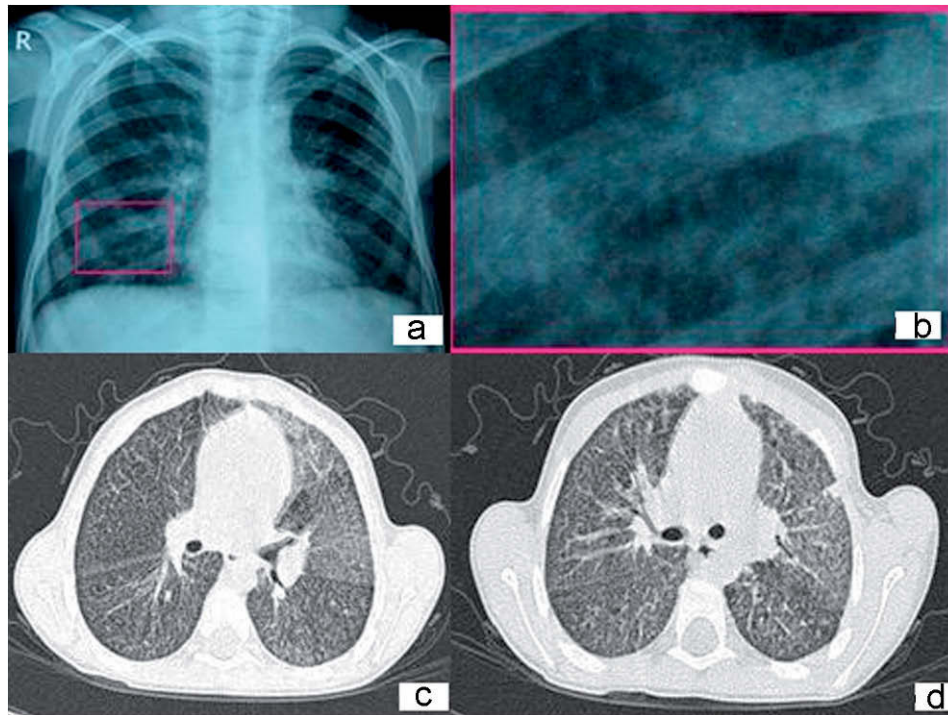


Figure 1. a) The postero-anterior radiography shows diffuse reticulonodular infiltrate in the base of both lungs. b) Close-up of reticulonodular infiltrate affecting the lower parts of the lung. c) High-resolution computed tomography (HRCT) showing a ground-glass section accompanied by septal interlobular-intralobular thickening and peribronchovascular interstitial thickening. d) HRCT of the superior areas of the lung showing subpleural nodules.

2. Coussement A, Aiem A, Forderer A, Albertini M. The pure visceral form of Niemann-Pick disease in childhood. Review of the literature and report of a case. *J. Radiol.* 1988;69:783-5.
3. Ferretti GR, Lantuejoul S, Brambilla E, Coulomb M. Pulmonary involvement in Niemann-Pick disease subtype B: CT findings. *J Comput Assist Tomogr.* 1996;20:990-2.
4. Alymlahi E, Dafiri R. Pulmonary involvement in Niemann-Pick type B disease. *J Postgrad Med.* 2004;50:289-90.
5. Mendelson DS, Wasserstein MP, Desnick RJ, Glass R, Simpson W, Skloot G, et al. Type B Niemann-Pick disease: Findings at chest radiography, thin-section CT, and pulmonary function testing. *Radiology.* 2005;238:339-45.
6. Nicolson AG, Wells AU, Hooper J, Hansell DM, Kelleher A, Morgan C. Successful treatment of endogenous lipoid pneumonia due to Niemann-Pick type B disease with whole-lung lavage. *Am. J Respir Crit Care Med.* 2002;165:128-31.

Huseyin Ozkurt,* Guzide Toksoy, and Muzaffer Basak

Departamento de Radiología, Hospital para la Docencia y la Investigación Sisli Etfal, Estambul, Turkey

*Corresponding author.

E-mail address: drhozkurt@yahoo.com (H. Ozkurt).