

than those visible on the chest x-ray, with irregular margins and perivascular distribution.^{2,3} Our patient presented multiple calcified nodules of variable size. The differential diagnosis included calcified metastasis, nodular amyloid, infectious granulomatous diseases, granulomas with hyalinisation, multiple hamartomas, multiple chondromas and pneumococcus.^{4,6} In general, an open lung biopsy is required to establish the diagnosis. An immunohistochemistry is usually also necessary for diagnosis.¹ To conclude, the PEH should be considered in the differential diagnosis of multiple calcified nodules.

References

1. Azcárate Perea L, Oliveros Acebes E, Moreno Mata N, Salomón Pérez R, Vilalta Castel E, González Aragonés F. Hemangioendoteloma epiteloide pulmonar. Arch Bronconeumol. 2009 ;45:466-8.
2. Díaz R, Segura A, Calderero V, Cervera I, Aparicio J, Jordá MV, et al. Central nervous system metastases of a pulmonary epithelioid haemangioendothelioma. Eur Respir J. 2004;23:483-6.

3. Sakamoto N, Adachi S, Monzawa S, Hamanaka A, Takada Y, Hunada Y, et al. High resolution CT findings of pulmonary epithelioid hemangioendothelioma: unusual manifestations in 2 cases. J Thorac Imaging. 2005;20:236-8.
4. Luburich P, Ayuso MC, Picado C, Serra-Batlés J, Ramirez JF, Solé M. CT of pulmonary epithelioid hemangioendothelioma. J Comput Assist Tomogr. 1994;18:562-5.
5. Ledson MJ, Convery R, Carty A, Evans CC. Epithelioid haemangioendothelioma. Thorax. 1999;54:560-1.
6. Marchiori E, Souza AS Jr, Franquet T, Müller NL. Diffuse high-attenuation pulmonary abnormalities: a pattern-oriented diagnostic approach on high-resolution CT. AJR Am J Roentgenol. 2005;184:273-82.

Edson Marchiori,^{a,*} Bruno Hochhegger,^a and Klaus L. Irion^b

^aFluminense Federal University, Rio de Janeiro, Brazil

^bLiverpool Heart and Chest Hospital-NHS Trust, Liverpool, United Kingdom

*Corresponding author.

E-mail address: restrepom@uthscsa.edu (E. Marchiori).

A New Example of the Scientific Bias Caused by the English Language: the American Guide for Treating Tobacco Use

Un nuevo ejemplo de sesgo científico del idioma inglés: la guía americana del tratamiento del tabaquismo

To the Editor,

If we carefully read the reference guide *Treating Tobacco Use and Dependence: 2008 Update* by Fiore and col¹, in Chapter 1, where the method followed for drawing this up is detailed, we find that one of the inclusion criteria for articles selected for different meta-analysis after the corresponding search, is that articles should be written in English. Systematic bias and error are constant hazards affecting the confidence and validity of meta-analytic studies, and the bias (documentary) of the English language² is one of the systematic revision errors. The bias of the English language consists in the fact that documents written in that language have a greater chance of being published, retrieved, and, therefore, quoted, in other languages, without this meaning that they are of higher quality. This systematic error means that any meta-analytic study that only takes into account studies published in a certain language is susceptible to bias. Furthermore, it is not rare for researchers who speak another language to publish studies with positive results in English-language journals, since they consider these more relevant, and to publish studies with negative results in local journals, which adds a further positive bias to that of publication.

If we analyze the world production of articles on smoking in the five year period 1999-2003, using the Science Citation Index (SCI), 79 countries contributed to this production; classified by language these formed 3 major groups, which form the international network collaborating on smoking: English-speaking countries (14 countries), followed by Spanish-speaking countries and French-speaking countries, with 9 and 8 countries in these last groups, respectively. However, 94.97% of the total number of articles published over this 5-year period were in English, 1.60% in Spanish, 1.51% in French, and 1.37% in German, less than 1% of the total number of studies were written in other languages.^{3,4} As to the publication of non-English-speaking authors in journals published in English, analysing this by means of the SCI, we found that out of

588 compiled documents of studies made by Spanish authors on smoking during the 1998-2007 decade, 76.19% (n = 448) were written in English, 137 (23.29%) in Spanish and 0.34 and 0.17% in French and German, respectively. This could be due to a desire for a greater relevance by publishing in English.⁵

At a time when English is considered the language to convey medical knowledge, and when the publication in said language is prioritized, it has been shown that there are high quality studies written in other languages, which have deserved to be included in non-English journals of merit selected by SCI (knowing the language limitations of this database⁶). In the American Tobacco Use Update¹, at no time is it mentioned that this was published only for the English-speaking world, and although we are aware that probably the results of the evidence of the meta-analyses will not vary significantly if studies written in other languages are included in them, it would indeed, have been possible to avoid bias in favour of positive results. The main biomedical databases are biased towards the English language,⁶ in spite of the fact that studies written in this language do not use better quality methods than those written in German, French or Spanish. Biases exist and arise in many different forms, and therefore we must be cautious when reading revisions, especially when trying to apply in clinical practice the results of a single trial. Systematic revisions and meta-analyses also have quality issues, and when published should include a discussion on their main sources of biases. Few do this, and therefore, they may cause confusion and mistakes. Similarly to clinical trials, meta-analyses may not appropriately report the methods followed when performing them and include poor quality studies, which increase their possibility of finding positive results.

References

1. Fiore MC, Jaén CR, Baker TB, Bailey WC, Benowitz NL, Curry SJ, et al. Treating tobacco use and dependence: 2008 update. Rockville, MD: US Department of Health and Human Services Public Health Service; 2008.
2. Egger M, Zellweger-Zähner, Schneider M, Junker C, Lengeler C, Antes G. Language bias in randomised controlled trials published in English and German. Lancet. 1997;350:326-9.
3. Villanueva Serrano S. Producción, colaboración e impacto de la actividad científica mundial en tabaquismo a través del Science Citation Index (1999-2003) [doctoral thesis]. Madrid: Universidad Complutense; 2007.

4. Granda Orive JI, Villanueva Serrano S, Aleixandre Benavent R, Valderrama Zurían JC, Alonso Arroyo A, García Río F, et al. Redes de colaboración científica internacional en tabaquismo. Análisis de coautorías a través del Science Citation Index durante el período 1999-2003. *Gac Sanit.* 2009;23: 222.e34-e43
5. Granda Orive JI, Alonso Arroyo A, Jareño Esteban J, Campos Téllez S, Aleixandre Benavent R, García Río F, et al. ¿Ha aumentado la producción española en tabaquismo en los últimos dos quinquenios?. *Arch Bronconeumol.* 2009;45: Espec Congr:140
6. Granda Orive JI. Algunas reflexiones y consideraciones sobre el factor de impacto. *Arch Bronconeumol.* 2003;39:409-17

José Ignacio de Granda-Orive,^{a,*} Segismundo Solano-Reina,^b
and Carlos Jiménez-Ruiz^c

^a *Unidad de Tabaquismo, Servicio de Neumología, Hospital Central de Defensa Gómez Ulla, Universidad Alcalá de Henares, Madrid, Spain*

^b *Unidad de Tabaquismo, CEP Hermanos Sangro, Hospital General Universitario Gregorio Marañón, Madrid, Spain*

^c *Unidad Especializada de Tabaquismo, Dirección General de Salud Pública y Alimentación, Madrid, Spain*

*Corresponding author.

E-mail address: igo01m@gmail.com (J.I. de Granda-Orive).

Primary Lung Sarcoma

Sarcoma pulmonar primario

Dear Editor,

Primary lung sarcoma (PLS) is a very rare lung tumour, found rarely in the literature and has different varieties: angiosarcoma, leiomyosarcoma, rhabdomyosarcoma, the sarcomatoid variant of mesothelioma and the primary Ewing's sarcoma/primitive neuroectodermal lung tumour,¹ which are different from pulmonary metastases from extrathoracic sarcomas.² Radiology techniques (computerised tomography and magnetic resonance) try to define the origin of the tumours, as well as the relationship with and invasion of neighbouring structures.³

We present the case of a 61-year-old smoker male. After showing common cold symptoms, he presented a nodule in the left lower lobe (posterior-anterior [Fig. 1a] and lateral [Fig. 1b] chest radiographs). A thoracic computerised tomography scan without intravenous contrast showed a mediastinal window with solid and homogenous nodule (Fig. 2a), with spiculated edges and pleural tail signa and a parenchymal window, as indicative signs

that the tumour was malignant (Fig. 2b). After having carried out a lobectomy and left lymphadenectomy, the definitive anatomopathologic diagnosis was an intermediate grade PLS with fusocellular and epithelioid areas, type malignant fibrous histiocytoma, which was infiltrating the visceral pleura at pT2 N0 M0 stage. It presented positive immunohistochemical reaction with S-100 protein, EMA (epithelial cells of ducts trapped due to neoplasm), enolase (epithelioid-like isolated tumour cells), Bcl-2, CD-34 and pan-CK (epithelial cells of ducts).

PLS is a rare malignant entity, that affects young people and often starts with chest pain, coughing and haemoptysis. Radiographs often show a lung mass in the pleural cavity. The anatomopathologic diagnosis is based on microscopic visualisation of the epithelioid and fusiform cells, as well as positive immunohistochemical reactions to epithelial membrane antigens and to cytokeratin and vimentine.⁴ Protein expression levels of SYT-SSX1 are related with a worse prognosis.⁵ Treatment is a combination of surgery and polychemotherapy. Economic resection of the lung is performed to prevent future relapses. 5-year survival rates are estimated at 40-57% and 10-year at 30%, being good prognostic factors for tumours smaller than 5cm. as well as a histology of epithelial predominance and peripheric localisation.⁶

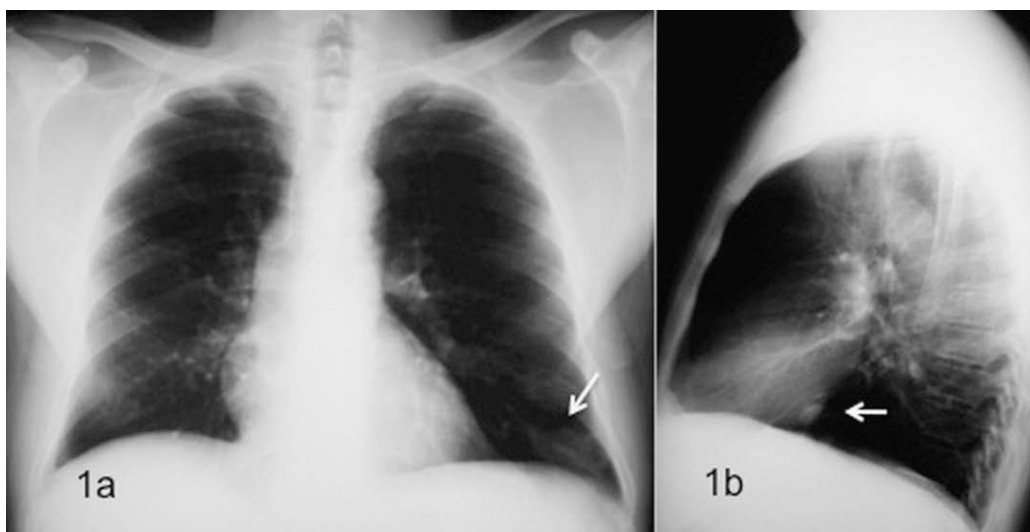


Figure 1. Posteroanterior (a) and lateral (b) chest radiographs, where a nodule (white arrows) can be seen in the left lower lobe.