

Journal Pre-proof

Certolizumab pegol-associated acute interstitial pneumonitis

Atif Saleem Siddiqui MD



PII: S0300-2896(24)00275-8

DOI: <https://doi.org/doi:10.1016/j.arbres.2024.07.013>

Reference: ARBRES 3629

To appear in: *Archivos de Bronconeumología*

Received Date: 23 May 2024

Accepted Date: 16 July 2024

Please cite this article as: Siddiqui AS, Certolizumab pegol-associated acute interstitial pneumonitis, *Archivos de Bronconeumología* (2024), doi: <https://doi.org/10.1016/j.arbres.2024.07.013>

This is a PDF file of an article that has undergone enhancements after acceptance, such as the addition of a cover page and metadata, and formatting for readability, but it is not yet the definitive version of record. This version will undergo additional copyediting, typesetting and review before it is published in its final form, but we are providing this version to give early visibility of the article. Please note that, during the production process, errors may be discovered which could affect the content, and all legal disclaimers that apply to the journal pertain.

© 2024 SEPAR. Published by Elsevier España, S.L.U. All rights are reserved, including those for text and data mining, AI training, and similar technologies.

Type of Article: Clinical Letter

Title : Certolizumab pegol-associated acute interstitial pneumonitis

Author:

Atif Saleem Siddiqui, MD

Pulmonary and Critical Care Medicine, Houston Methodist Hospital

Houston, Texas

6550 Fannin St.

Suite 2321

Houston, Texas, 77030

USA

Email: atifsaleem19@yahoo.com

Figure: 1

Table: 0

Keywords: Certolizumab; Acute interstitial pneumonitis; Dyspnea

Abbreviations:

CT: Computed tomography

BAL: Bronchoalveolar lavage

AFB: Acid fast bacillus

MTB: *Mycobacterium tuberculosis*

PCR: Polymerase chain reaction

Interstitial lung disease secondary to drugs is generally associated with considerable morbidity and death. Acute interstitial pneumonitis due to certolizumab pegol has rarely been described in the literature [1, 2, 3, and 4]. We describe a case of a 76-year-old male with a medical history of tobacco use, emphysema and rheumatoid arthritis (RA), recently complicated with pulmonary fibrosis [Figure 1A]. The patient started certolizumab pegol treatment 2 weeks after the pulmonary fibrosis diagnosis, due to a severe rheumatoid arthritis event.

He presented to the emergency department with shortness of breath and cough. On early assessment, his heart rate was 112/min, his respiratory rate was 24/min, oxygenation saturation was 65% on room air, temperature was 98.6 F, and normal blood pressure. Chest examination revealed more pronounced bilateral rales at the base. Initial laboratory data showed normal white cell count and serum electrolytes. His arterial blood gas showed a pH of 7.24, pCO₂ of 69 mmHg and po₂ of 55 mmHg on room air. The patient was intubated due to increased work of breathing upon admission. Blood, sputum and urine cultures were negative. Serum histoplasmosis antibodies, urine histoplasmosis antigen, serum coccidioidomycosis antibodies, and viral PCR panel were negative. Rheumatoid factor (RF) was 650 IU/ml. Computed tomography (CT) of the chest showed emphysema in the upper lobes, subpleural honeycombing, traction bronchiectasis and superimposed bilateral peripheral ground glass opacities with an organizing pneumonia pattern [Figure 1B]. The patient was treated with vancomycin and cefepime. Bronchoscopy with bronchoalveolar lavage (BAL) showed predominant lymphocytes. The results of BAL studies, including bacterial, fungal, and acid-fast bacillus (AFB) culture and *Mycobacterium tuberculosis* (MTB) polymerase chain reaction (PCR) were negative. In the

setting of persistent symptoms and a negative diagnostic workup, drug-induced interstitial pneumonitis was considered. We stopped certolizumab pegol as a therapeutic intervention because of a lack of improvement with appropriate antibiotics and negative cultures. He was treated with intravenous methylprednisolone 240 mg/day for 3 days. He was extubated after 72 hours. He was weaned off oxygen before discharge. He was discharged on a tapering prednisone regimen over a 4-week period. A CT of the chest, performed three months after discharge, showed emphysema in the upper lobes and subpleural honeycombing, with resolution of superimposed ground-glass opacities and organizing pneumonia [Figure 1C].

We did not rechallenge the patient with certolizumab pegol because of increased risk of death.

Certolizumab pegol is a recombinant humanized antihuman TNF-alpha neutralizing antibody. It has been shown to be more efficacious in the treatment of rheumatoid arthritis in combination with methotrexate [5]. Common respiratory side effects of certolizumab pegol include upper respiratory tract infection and cough. In previously described cases, the patients were on concomitant methotrexate. Furthermore, the temporal relationship was not clear. The patient described in this case was not on methotrexate that can cause interstitial pneumonitis .

Furthermore, there was a clear temporal relationship, as ground glass opacities developed two weeks after starting certolizumab pegol . However, rechallenge was not performed due to risk of mortality.

Clinicians need to have a reasonable suspicion of drug-induced pulmonary toxicity with certolizumab pegol in patients who present with respiratory symptoms. Corticosteroids may be considered for severe life-threatening disease. Early recognition of certolizumab pegol can prevent adverse outcomes.

Contribution: Author has contributed substantially to obtaining the results and preparation of the manuscript in accordance with ICMJE criteria

Declaration of Funding: None

Conflicts of interest: None

Journal Pre-proof

References:

1. Ian N. Glaspole, Ryan F. Hoy, Peter F. Ryan. A case of certolizumab-induced interstitial lung disease in a patient with rheumatoid arthritis, *Rheumatology*, Volume 52, Issue 12, December 2013, Pages 2302–2304
2. Jakob Lager, Ole Hilberg, Anders Løkke et al. Severe interstitial lung disease following treatment with certolizumab pegol: a case report. *European Respiratory Review* 2013 22: 414-416
3. Fiona Pearce, Simon R. Johnson, Philip Courtney. Interstitial lung disease following certolizumab pegol. *Rheumatology*, Volume 51, Issue 3, March 2012, Pages 578–580
4. Auleen Millar, Jennifer Mckew, Allister Taggart. Fatal fibrosing alveolitis with certolizumab. *Rheumatology*, Volume 51, Issue 5, May 2012, Pages 953–955
5. Schmitz S, Adams R, Walsh CD, et al. A mixed treatment comparison of the efficacy of anti-TNF agents in rheumatoid arthritis for methotrexate non-responders demonstrates differences between treatments: a Bayesian approach. *Ann Rheum Dis* 2012; 71: 225–230

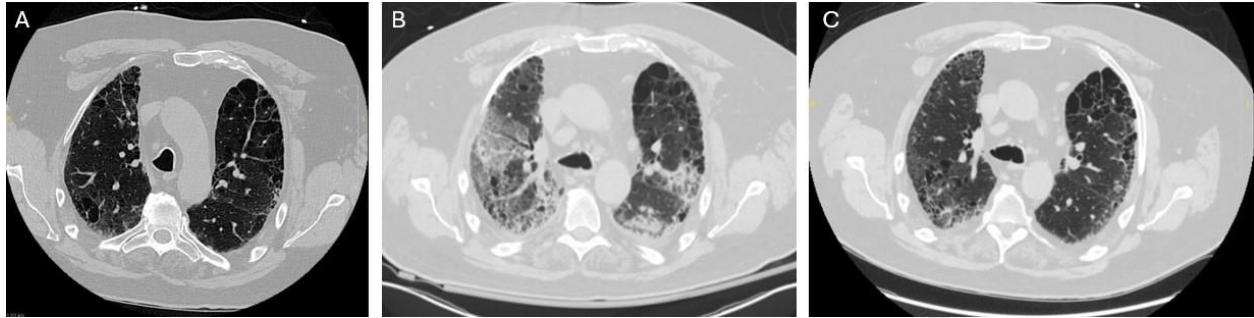
Figure Legends:

Figure 1: (A) Chest CT, performed 2 weeks before starting certolizumab pegol, showed centrilobular emphysematous changes in the upper lobes and subpleural reticular infiltrates. (B) Chest CT showed emphysema in the upper lobes, subpleural honeycombing, traction bronchiectasis bilateral peripheral ground glass opacities with an organizing pneumonia pattern. (C) A CT of the chest, performed three months after discharge, showed emphysema in the upper lobes and subpleural honeycombing, with resolution of superimposed ground-glass opacities and organizing pneumonia.