

Clinical Image

Changes in Ventilation–Perfusion Mismatch Associated With Inhaled Nitric Oxide in a Patient with Pneumonia That Met Criteria for Acute Respiratory Distress Syndrome



Cambios en la alteración de la ventilación–perfusión asociados a la inhalación de óxido nítrico en un paciente con neumonía que cumplía criterios de síndrome de distrés respiratorio agudo

Anna Sánchez-Corral^{a,b}, Marina García-de-Acilu^{a,c}, Manel Santafè^a, Oriol Roca^{a,c,d,*}

^a Critical Care Department, Vall d'Hebron University Hospital, Vall d'Hebron Research Institute, Barcelona, Spain

^b Department of Cell Biology, Physiology and Immunology, Universitat Autònoma de Barcelona, Bellaterra, Spain

^c Departament de Medicina, Universitat Autònoma de Barcelona, Bellaterra, Spain

^d Ciber Enfermedades Respiratorias (CIBERES), Instituto de Salud Carlos III, Madrid, Spain

A 59-year-old male was admitted to ICU for subarachnoid and lobar hemorrhage. The patient developed acute respiratory failure secondary to aspiration pneumonia that met criteria for acute respiratory distress syndrome (ARDS) with hemodynamic instability requiring noradrenaline at 0.9 $\mu\text{g}/\text{kg}/\text{min}$. Despite deep sedation and neuromuscular blockade, the patient remained hypoxemic. In supine position, the patient was ventilated in volume-assisted control with a tidal volume of 7.8 ml/kg of predicted body weight and PEEP of 10 cm of H_2O at 24 breaths/min. In this situation, the plateau pressure was 24 cm of H_2O and the compliance of the respiratory system was 36 ml/cm H_2O . The ratio between partial pressure of oxygen and the fraction of inspired oxygen ($\text{PaO}_2/\text{F}_i\text{O}_2$) was 84 mmHg. Prone positioning could not be performed due to the increased intracranial pressure. Subsequently, respiratory monitoring was complemented with thoracic electrical impedance tomography (EIT). Surprisingly, it revealed a relatively homogeneous ventilation with decreased perfusion of the right lung (Fig. 1a). In view of these findings, inhaled nitric oxide (iNO) therapy was initiated at 5 ppm and increased up to 10 ppm. After one hour of iNO therapy at 10 ppm, $\text{PaO}_2/\text{F}_i\text{O}_2$ rose to 128 mmHg and was associated with a more homogeneous distribution of perfusion (Fig. 1b) measured by EIT. No adverse effects associated with iNO therapy were observed. This case illustrates that iNO can be considered in selected cases of severe hypoxemia. EIT perfusion analysis is a monitoring tool that may be useful in these clinical situations.

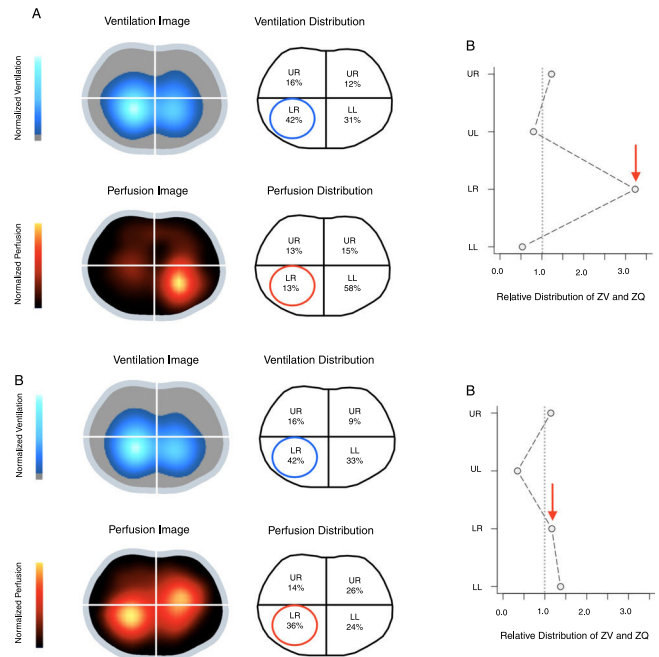


Fig. 1. Electrical impedance tomography (EIT) ventilation and perfusion images obtained before (a) and after (b) inhaled nitric oxide therapy at 10 ppm. Color scale adjusted by linear normalization. LL: lower left; LR: lower right; UL: upper left; UR: upper right; ZV: ventilation estimated by EIT; ZQ: perfusion estimated by EIT. (a) Baseline: perfusion reduction in the RL lobe with no changes in ventilation. (b) After 1 h of iNO therapy at 10 ppm: increase in perfusion in the RL lobe with an improvement in the ventilation–perfusion ratio.

Acknowledgement

The authors would like to thank Dr. Caio Morais for his technical assistance in preparing the figures.

* Corresponding author.
E-mail address: oroca@vhebron.net (O. Roca).