

resection of small, intraparenchymal lesions, achieving adequate margins using conventional or minimally invasive surgery.

References

1. MacMahon H, Naidich DP, Goo JM, Lee KS, Leung ANC, Mayo JR, et al. Guidelines for management of incidental pulmonary nodules detected on CT images: from the Fleischner Society 2017. *Radiology*. 2017;284:228–43.
2. Suzuki K, Nagai K, Yoshida J, Ohmatsu H, Takahashi K, Nishimura M, et al. Video-assisted thoracoscopic surgery for small indeterminate pulmonary nodules: indications for preoperative marking. *Chest*. 1999;115:563–8.
3. Zaman M, Bilal H, Woo CY, Tang A. In patients undergoing video-assisted thoracoscopic surgery excision, what is the best way to locate a subcentimetre solitary pulmonary nodule in order to achieve successful excision? *Interact Cardiovasc Thorac Surg*. 2012;15:266–72.
4. Gnofiotti A, Davini F, Vaggelli L, de Francisci A, Caldarella A, Gigli PM, et al. Thoracoscopic localization techniques for patients with solitary pulmonary nodule: hookwire versus radio-guided surgery. *Eur J Cardiothorac Surg*. 2007;32:843–7.
5. Kondo R, Yoshida K, Hamanaka K, Hashizume M, Ushiyama T, Hyogotani A, et al. Intraoperative ultrasonographic localization of pulmonary ground-glass opacities. *J Thorac Cardiovasc Surg*. 2009;138:837–42.
6. McConnell PI, Feola GP, Meyers RL. Methylene blue-stained autologous blood for needle localization and thoracoscopic resection of deep pulmonary nodules. *J Pediatr Surg*. 2002;37:1729–31.
7. Sortini D, Feo CV, Carcoforo P, Carrella G, Pozza E, Liboni A, et al. Thoracoscopic localization techniques for patients with solitary pulmonary nodule and history of malignancy. *Ann Thorac Surg*. 2005;79:258–62.

Samuel Garcia-Reina^{a,*}, Esther Fernández^a, Sergio Lafuente Carrasco^b, Victor Margelí^c, Carles Gómez^c, Gloria Moragas^b, Pedro E. Lopez de Castro^a, Antoni Rosell^d

^a Servicio de Cirugía Torácica, Dirección Clínica del Tórax, Universitat Autònoma de Barcelona, Facultat de Medicina, Hospital Universitari Germans Trias i Pujol, Badalona, Spain

^b Servicio de Medicina Nuclear, Hospital Universitari Germans Trias i Pujol, Badalona, Spain

^c Servicio de Radiología, Hospital Universitari Germans Trias i Pujol, Badalona, Spain

^d Dirección Clínica del Tórax, Universitat Autònoma de Barcelona, Facultat de Medicina, Hospital Universitari Germans Trias i Pujol, Badalona, Spain

* Corresponding author.

E-mail address: sgarcia.germanstrias@gencat.cat (S. Garcia-Reina).

<https://doi.org/10.1016/j.arbr.2021.09.005>

1579-2129/ © 2021 SEPAR. Published by Elsevier España, S.L.U. All rights reserved.

Respiratory Manifestations in Primary Immunodeficiencies: Findings From a Pediatric and Adult Cohort



Manifestaciones respiratorias en las inmunodeficiencias primarias: hallazgo de una cohorte pediátrica y adulta

Dear Editor,

Primary immunodeficiencies (PIDs) are a heterogeneous group of more than 400 inherited immune system disorders, with overall prevalence 1/1000–1/5000.¹ At any age, recurrent-to-persistent respiratory infections are often the first presenting sign of PIDs.² Poor defense from opportunistic or non-opportunistic pathogens, as well as non-infectious complications may significantly impact morbidity and mortality of the conditions, even when early detected.³

In PIDs, type, outcome and severity of the underlying defect might influence type and severity of patients' respiratory phenotypes, but only few studies documented this.⁴

In this report, we compared the respiratory manifestations and the chest imaging findings from a cohort of pediatric and adult patients from a tertiary level hospital, a major referral for PID, located in Campania region, in Southern Italy. In order to describe the respiratory phenotypes in different PID groups and to investigate their prevalence, we conducted a retrospective study over a three-year period, from mid-2018 to mid-2020 and created a database of 269 patients with PID including 182 children (mean age, 9 ± 4 years; 67% of the total) and 87 adults (mean age, 20 ± 6.5 years; 33% of the total). According to the underlying diagnosis, patients were allocated to three groups: cellular immunity defects [Group 1, *n* = 48, 17.9% of the total, including Ataxia–Teleangiectasia (A-T), partial DiGeorge syndrome (pDGS), or Severe Combined Immune-deficiencies (SCID) before treatment]; humoral immunity defects [Group 2, *n* = 203, 75.5% of the total, including Common Variable Immune-deficiency (CVID), X-linked Agammaglobulinemia (XLA), or selective IgA Deficiency (slgAD)]; innate immunity defects [Group 3, *n* = 18, 6.6% of the total, including Chronic

Granulomatous Disease (CGD), *STAT1* gain of function, hyper IgE Syndrome, *MYD88* Deficiency, or congenital neutropenia]. We analyzed variables including gender, type of PID, age at diagnosis, age at onset of respiratory symptoms, diagnostic delay (the time elapsed between the onset of respiratory symptoms and the diagnosis of PID), history of upper (i.e. rhinosinusitis and/or otitis) or lower (i.e. bronchitis and/or pneumonia) airway infections, chest imaging phenotypes (at X-ray or Computed Tomography or Magnetic Resonance Imaging).⁵ In our study population, Groups 1 and 3 included only children, while Group 2 was composed of both pediatric and adult patients with humoral immunity defects.

Comparisons between groups were performed applying t-test for numerical variables and chi-test for categorical variables.

The age at onset of respiratory symptoms was significantly higher in Group 2 than Groups 1 and 3 (*P* < .001; Fig. 1A). In more than half of the cases, a diagnosis of cellular immunity defect was established, in nearly 90%, of cases in the first decade (Fig. 1B). A wide variability of age at diagnosis was found in cases with humoral immunity defects, while patients with defects of innate immunity were diagnosed always before adolescence. The diagnostic delay was lower in patients with cellular immunity defects than in other groups (*P* < .01; Fig. 1C). Rhinosinusitis was more common in Group 2, with a significant difference when compared to Groups 1 and 3 (*P* < .05), and otitis was more frequent in Group 1. No significant difference in the prevalence of lower airway infections was found among all groups (Fig. 1D).

In order to investigate whether a different localization of airway infections in each disease group was associated with a specific immunological defect, we compared the prevalence within subgroups. In Group 1, upper airway infections were more frequent in A-T patients, while lower airway infections were more prevalent among SCID patients (Fig. 1E–F). Within the pediatric patients from Group 2, we compared the prevalence among XLA, CVID and slgAD, and found that rhinosinusitis was more prevalent in the CVID subgroup (*P* < .05) (Fig. 1G). Within Group 3, patients with CGD or other innate immunity disorders showed higher prevalence of pneumonia in the CGD subgroup (Fig. 1H).

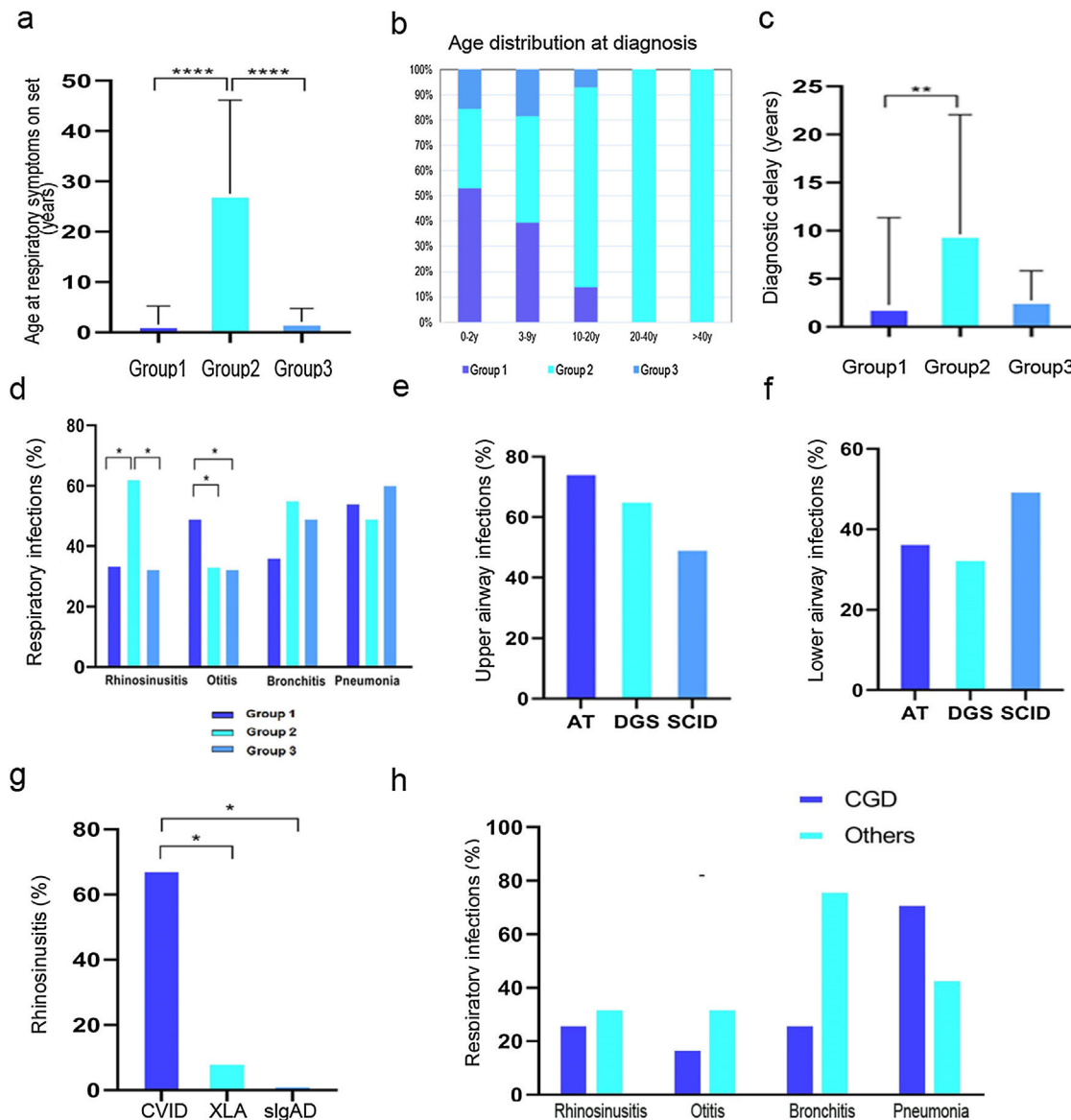


Fig. 1. (a) Age of onset of respiratory symptoms. (b) Age distribution at diagnosis according to different IEL. (c) Diagnostic delay. (d) Distribution of respiratory infections among the three groups. (e) Upper respiratory tract infections within Group 1. (f) Lower respiratory tract infections within Group 1. (g) Prevalence of rhinosinusitis in Group 2. (h) Distribution of respiratory infections within Group 3. **P*-value $\leq .05$, ***P*-value $\leq .01$, ****P*-value $\leq .0001$.

Of 269 patients, 197 (72.3%) underwent chest imaging examinations at the time of database creation. Four major categories of radiological changes were analyzed: consolidation, bronchiectasis, interstitial lung disease and Granulomatous and Lymphocytic Interstitial Lung Disease (GLILD).⁶

Consolidation was more common among patients with cellular and innate immunity defects than in those with humoral immunity defects ($P < .05$). Prevalence of bronchiectasis was significantly higher in patients with humoral immunity defects compared to cellular immunity defects ($P < .05$). As the only group including both pediatric and adult patients is Group 2, we compared the general characteristics, clinical manifestations and chest imaging findings between the two age subgroups (Table 1). As expected, adults with humoral immunity defects had a straightforward delay in the diagnosis of PID (6.1 versus 1.3 years in the pediatric population; $P < .00001$), while children showed a fairly higher rate of otitis than adults (55% versus 6.8%, respectively; $P < .00001$). Finally, no noteworthy difference was found in the prevalence of radiological findings between the two age subgroups, except for GLILD

that was found in 28 CVID patients of which 93% were adults (Table 1).

Overall, our report reveals, as expected, that in cases with the most severe PID, such as cellular or innate immunity defects, respiratory symptoms start early.⁷ This resulted in a prompt immunological diagnosis. Patients with humoral immunity defects usually present with mild upper respiratory tract infections which might be, indeed, overlooked, thus delaying the referral to the immunology center. The association with other non-immunological features may also reduce the diagnostic delay in selected cases (A-T or DGS). Moreover, the finding that rhinosinusitis is the most prevalent respiratory manifestation in CVID (Group 2) or A-T patients (Group 1) might be explained by the long-lasting T-cell defect in both disorders, rather than by the severity of T-cell impairment or the selective humoral immunity defects. While we did not find any significant difference in lower respiratory tract infections distribution among all groups, rhinosinusitis associated with GLILD appeared a distinctive feature of the respiratory phenotype of CVID. Early recurrent sinopulmonary

Table 1
General Characteristics, Clinical Manifestations and Chest Imaging Findings of Group 2 Including Pediatric and Adult Patients With Humoral Immunity Defects; the Comparison Between the Two Age Groups, Calculated Using Either t-test or chi-test, Are Shown on the Right Column.

	Whole Group	Children	Adults	P
<i>General characteristics</i>				
Patients, N	203	116	87	N.A.
Gender, % males	52	79	44	.017
Mean age at last clinical follow-up, years	30	16	44	<.00001
Diagnostic delay, years	9.6	1.3	6.1	<.00001
<i>Clinical manifestations</i>				
Rhinosinusitis, %	62	63	60	.78
Otitis, %	34	55	6.8	<.00001
Bronchitis, %	50	48	60.9	.24
Pneumonia, %	56	43	57	.059
<i>Chest imaging findings</i>				
Patients who underwent imaging, N	145	93	52	.002
Collapse/consolidation, %	33	30	38	.41
Bronchiectasis, %	24	22	28	.52
Interstitial lung disease, %	9	8.6	9	.92
GLILD, %	19	2	50	<.00001

Abbreviations: GLILD, granulomatous lymphocytic interstitial lung disease.

infections are extremely common in CVID, and a high proportion of cases may develop chronic lung disease with bronchiectasis.³ A host of other systemic manifestations, including autoimmune disorders and lymphoproliferation may also occur which significantly worsen patients' morbidity and mortality. Prognosis of CVID is largely affected by GLILD, a lymphoproliferative disorder characterized by progressive lung damage including airway disease and the need for continuous chest treatment.^{8,9}

Although the hallmarks of respiratory manifestations in the different groups of PID are already known, our report, through a stratified sampling method on a single-center cohort including both pediatric and adult patients, highlights that rhinosinusitis and GLILD are almost exclusively found in CVID, suggesting that the contextual presence of a cell-mediated defect of long duration in association with the humoral defect is necessary for its development. Hopefully, the precocious identification of the lung disease may help improve the final outcome of the disease and more importantly may significantly impact the quality of life of patients with PID.

Funding

This research did not receive any specific grant from funding agencies in the public, commercial, or not-for-profit sectors.

Conflicts of Interest

The authors declare to have no conflict of interest directly or indirectly related to the manuscript contents.

References

1. Tangye SG, Al-Herz W, Bousfiha A, Chatila T, Cunningham-Rundles C, Etzioni A, et al. Human inborn errors of immunity: 2019 update on the classification from the international union of immunological societies expert committee. *J Clin Immunol*. 2020;40:24–64.
2. Hampson FA, Chandra A, Srean NJ, Condliffe A, Kumararatne DS, Exley AR, et al. Respiratory disease in common variable immunodeficiency and other primary immunodeficiency disorders. *Clin Radiol*. 2012;67:587–95.

3. Baumann U, Routes JM, Soler-Palacín P, Jolles S. The lung in primary immunodeficiencies: new concepts in infection and inflammation. *Front Immunol*. 2018;9:1–13.
4. Nonas S. Pulmonary manifestations of primary immunodeficiency disorders. *Immunol Allergy Clin N Am*. 2015;35:753–66.
5. Montella S, Maglione M, Bruzzese D, Mollica C, Pignata C, Aloj G, et al. Magnetic resonance imaging is an accurate and reliable method to evaluate non-cystic fibrosis paediatric lung disease. *Respirology*. 2012;17:87–91.
6. Rao N, Mackinnon AC, Routes JM. Granulomatous and lymphocytic interstitial lung disease: a spectrum of pulmonary histopathologic lesions in common variable immunodeficiency – histologic and immunohistochemical analyses of 16 cases. *Hum Pathol*. 2015;46:1306–14.
7. Aloj G, Giardino G, Valentino L, Maio F, Gallo V, Esposito T, et al. Severe combined immunodeficiencies: new and old scenarios. *Int Rev Immunol*. 2012;31:43–65.
8. Soler-Palacín P, de Gracia J, González-Granado LI, Martín C, Rodríguez-Gallego C, Sánchez-Ramón S. Primary immunodeficiency diseases in lung disease: warning signs, diagnosis and management. *Respir Res*. 2018;19:1–13.
9. Meerburg JJ, Hartmann IJC, Goldacker S, Baumann U, Uhlmann A, Andrinopoulou ER, et al. Analysis of granulomatous lymphocytic interstitial lung disease using two scoring systems for computed tomography scans—a retrospective cohort study. *Front Immunol*. 2020;11:589148.

Roberta Romano^a, Melissa Borrelli^a, Emilia Cirillo^a,
Giuliana Giardino^a, Giuseppe Spadaro^b, Ludovica Crescenzi^b,
Ilaria Mormile^b, Laura Venditto^a, Claudio Pignata^{a,*},
Francesca Santamaria^{a,*}

^a Department of Translational Medical Sciences – Section of Pediatrics, University of Naples Federico II, Naples, Italy

^b Department of Translational Medical Sciences – Center for Basic and Clinical Immunology Research, University of Naples Federico II, Naples, Italy

* Corresponding authors.

E-mail addresses: pignata@unina.it (C. Pignata), santamar@unina.it (F. Santamaria).

◇ Both share correspondence co-authorship.

<https://doi.org/10.1016/j.arbres.2021.01.019>

0300-2896/ © 2021 SEPAR. Published by Elsevier España, S.L.U. All rights reserved.