

Scientific letter

**Usefulness of Pulmonary Artery Catheter
in the Evaluation of Alveolepleural Fistulas**

**Utilidad del catéter de arteria pulmonar para localizar fistulas
alveolo-pleurales**

Dear Editor,

An alveolepleural fistula (APF) represents an abnormal communication between alveoli and pleural space. In most patients these fistulas spontaneously resolve¹. If air leak persists beyond 5–7 days, it is considered an APF with prolonged air leak². As a novel approach, we describe a technique in which a pulmonary artery catheter (PAC) was used to localize a fistula with prolonged air leak – as an alternative to existing devices.

Case presentation: A 33-year-old immunosuppressed woman with a history of autoimmune hepatitis was admitted with a lung abscess and pleural effusion. Despite antibiotic treatment, the patient progressed to respiratory failure requiring mechanical ventilation (MV). A chest CT scan demonstrated multiple right lung cavitary lesions and pleural effusion (Fig. 1A). A diagnostic/therapeutic thoracentesis was performed, and purulent fluid was obtained, prompting chest tube insertion. Shortly after successful chest tube placement, a persistent air leak was observed (Grade 4C). This air leak persisted in time, despite attempts to minimize tidal volumes and PEEP. After seven days, the air leak continued so a decision was made to find the exact location of the fistula.

This procedure was performed in the intensive care unit as the patient was being mechanically ventilated. A regular single-use bronchoscope (2.0 mm working channel, Ambu aScope) and a 7 Fr pulmonary artery catheter (Swan Ganz – Edwards Lifesciences) were used. A 3-0 suture was used to ensnare the bronchoscope to the PAC (Fig. 1B). To support ventilation during the diagnostic/therapeutic bronchoscopy procedure, we used an 8.5 mm orotracheal ET tube with an elbow shaped adapter to allow for access. No signs of bronchial fistula were found in central airways or in proximal lobar segments. Then, the PAC was advanced inserted into each lobar bronchus and the balloon was inflated with 2 ml of air, confirming complete bronchial occlusion and preventing air from entering the evaluated lobe. We allowed for 2 min with balloon inflated in each lobe (RUL, then RML, then RLL sequentially) while monitoring for any change in air leak pattern in the drainage system for each potential area of concern (Fig. 1C). As the balloon was inflated at the middle lobe bronchus (RB4 + RB5), the air leak slowed down to eventually stop. To further confirm these findings, 60 ml of air were jetted distally – using one of the distal PAC ports (Fig. 1D). This maneuver resulted in air leak visualization at the chamber. As the balloon was deflated then air leak was observed again and persisted in time. No changes in leak volume were observed when occluding other lobar bronchi. The procedure was concluded in satisfactory fashion after successful identification of the affected area. The case was discussed in a multidisciplinary forum. Various therapeutic approaches had been

considered, although given refractory hypoxemia within 48 h of bronchoscopy, and rapid clinical decline due to sepsis the patient was not deemed candidate for any treatment modality and expired on at hospital day 15.

The most frequent causes for APF with prolonged air leak include lung volume reduction surgery, pulmonary resections, and bronchoscopic biopsies^{1–3}. Less frequent etiologies include necrotizing pneumonia, pleural drainage procedures and barotrauma due to mechanical ventilation⁴. The mortality rate for mechanically ventilated patients among those with prolonged air leak ranges from 25% to 81%⁵.

There is no current consensus regarding best approaches to diagnose and address APFs. Conventional treatment mandates pleural space drainage with or without wall suction, general supportive care and treatment of other underlying conditions⁶.

If the patient requires MV support, airway pressure should be minimized in order to reduce shear forces at the fistula. This can be achieved by reducing the respiratory rate, tidal volume and the positive expiratory pressure. Anecdotally, high frequency oscillatory ventilation has been used among this patient population⁷.

If these measures fail, then surgical and endoscopic options are to be considered. Importantly, the presence of collateral ventilation plays a role in deciding best approach. Other factors to consider include local equipment availability, proceduralists expertise, and expected outcomes. Of note, it is paramount to attempt fistula localization by sequential segmental/lobar balloon occlusion.

Endoscopic intervention with endobronchial valves, silicone spigots, occlusion materials/glues or bronchial stent placement have shown some efficacy in situations where collateral ventilation is minimal and there is significant leak reduction during the bronchial occlusion test⁸.

A technique to localize the fistula using a bronchial occlusion balloon has been previously described. Fogarty balloons have been used in the past. Other alternatives to localize a fistula include oxygen insufflation with an endoscope placed in the airways and observation of its effect on the leak in the water seal⁹. Alternatively, instillation of methylene blue in the pleural cavity through the drain tube and the posterior endoscopic detection of the stained tissue may be considered.

Previous work demonstrated the safety and usefulness of PAC catheter use for bronchoscopy management of massive haemoptysis or glues instillation^{10,11}. We hereby describe the off label use of the device and the first case report on the use of PAC to localize an alveolepleural fistula.

Unlike bronchial occlusion balloons, these PAC are readily available devices in most institutions, with a distal access port that enables air insufflation. Some advantages over other commercial available devices include cost, multiple ports for instillation, and widespread availability. In particular other commercially available devices may have disadvantages over the PAC: 1) fogarty occlusion balloons have no distal port (for air insufflation), CRE balloons may exert unwanted radial stress on bronchial walls, and other commercially available products may not be readily available in hospitals without advanced bronchoscopic service lines.

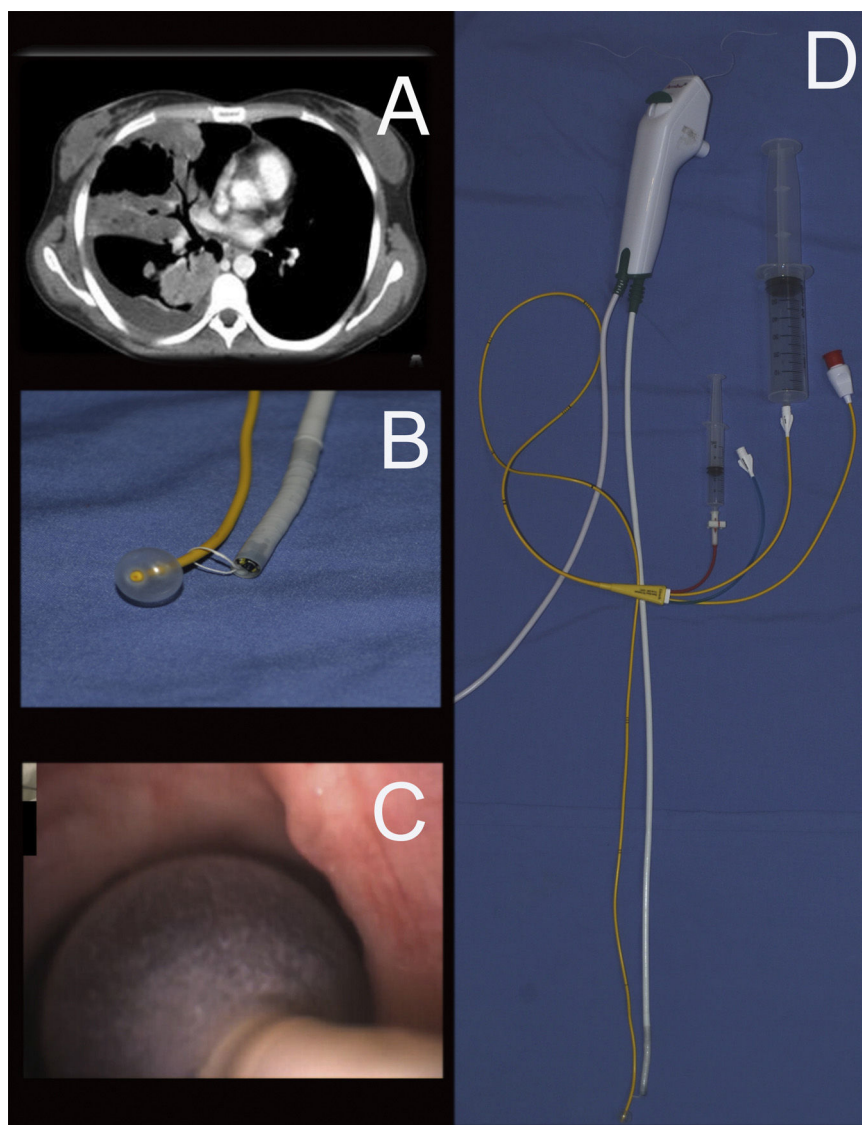


Fig. 1. (A) Chest CT scan: cavitary lesions in the lung and right pleural effusion. (B) Surgical linen tie and fastening the balloon with the linen handle. (C) PAC in airways. (D) Complete set with syringe balloon and 60 ml syringe.

In conclusion, a PAC is an easy to use, convenient, readily available, financially viable tool that is likely useful for the localization and isolation of an alveolo-pleural fistula using the occlusion method and which allows the confirmation of the localization by syringe insufflation.

Funding

We don't receive funding for this work from any of the following organizations: National Institutes of Health (NIH); Wellcome Trust; Howard Hughes Medical Institute (HHMI); and other(s).

Conflict of interest

The authors declare that the research was conducted in the absence of any commercial or financial relationships that could be construed as a potential conflict of interest.

Acknowledgment

We are grateful to Daniel Buljubasich for assistance in editing this manuscript.

References

1. Rivera C, Bernard A, Falcoz PE, Thomas P, Schmidt A, Bernard S, et al. Characterization and prediction of prolonged air leak after pulmonary resection: a nationwide study setting up the index of prolonged air leak. *Ann Thorac Surg.* 2011;92:1062. <http://dx.doi.org/10.1016/j.athoracsur.2011.04.033>.
2. Cerfolio RJ, Tummala RP, Holman WL, Zorn G, Kirklín J, McGiffin D, et al. A prospective algorithm for the management of air leaks after pulmonary resection. *Ann Thorac Surg.* 1998;66:1726–31. [http://dx.doi.org/10.1016/s0003-4975\(98\)00958-8](http://dx.doi.org/10.1016/s0003-4975(98)00958-8).
3. Garcha PS, Santacruz JF, Jaber WS, Machuzak M, Gildea T. Pneumothorax post flexible bronchoscopy. *ATS J.* 2011;183:A2351.
4. Miller JC, Boyce TG. Hydropneumothorax as a complication of necrotizing pneumonia in a young girl. *Clin Case Rep.* 2019;7:1559–61. <http://dx.doi.org/10.1002/ccr3.2294>.

5. Pierson DJ, Horton CA, Bates PW. Persistent bronchopleural air leak during mechanical ventilation. *Chest*. 1986;90:321–3, <http://dx.doi.org/10.1378/chest.90.3.321>.
6. Dugan KC, Laxmanan B, Murgu S, Hogarth K. Management of persistent air leaks. *Chest*. 2017;152:417–23, <http://dx.doi.org/10.1016/j.chest.2017.02.020>.
7. Carlon GC, Ray C, Klain M, McCormack P. Highfrequency positive-pressure ventilation in management of a patient with bronchopleural fistula. *Anesthesiology*. 1980;50:160–2.
8. Watanabe S, Watanabe T, Urayama H. Endobronchial occlusion method of bronchopleural fistula with metallic coils and glue. *Thorac Cardiovasc Surg*. 2003;51:106–8, <http://dx.doi.org/10.1055/s-2003-38981>.
9. Rodriguez Vial M, Lan C, Cornwell L, Omer S, Casal RF. Endobronchial oxygen insufflation: a novel technique for localization of occult bronchopleural fistulas. *Ann Am Thorac Soc*. 2013;10:157–9, <http://dx.doi.org/10.1513/AnnalsATS.201212-1260T>.
10. Loubriel B, Díaz J, Casal J, Rodriguez-Cintrón W. Sticking to life: closure of a bronchopleural fistula with fibrin glue in a patient with recurrent pneumothoraces. *J Bronchol*. 14:215–6. doi:10.1097/LBR.0b013e3180679e46.
11. Correia S, Dionisio J, Duro da Costa J. Modified technique of endobronchial balloon tamponade for persistent hemothysis. *J Bronchol Intervent Pulmonol*. 2014;21, <http://dx.doi.org/10.1097/LBR.000000000000102>.

^a Department of Pulmonary Medicine, Hospital Provincial del Centenario, Rosario, Argentina

^b Department of Critical Care Medicine, Hospital Provincial del Centenario, Rosario, Argentina

^c Pneumology, Argentina

^d Bronchoscopy and Interventional Pulmonology, Pulmonary, Critical Care Medicine Division, Spectrum Health Medical Group Associate Director, Pulmonary and Critical Care Fellowship Program – Michigan State University, United States

* Corresponding author.

E-mail address: navarretehpc@gmail.com

(R. Navarrete).

<https://doi.org/10.1016/j.arbres.2020.10.006>

0300-2896/ © 2020 SEPAR. Published by Elsevier España, S.L.U. All rights reserved.

Rodolfo Navarrete^{a,*}, Luis Pablo Cardonnet^b,
Lisandro Roberto Bettini^b, Gonzalo Morosano^c,
Gustavo Cumbo Nacheli^d

Can we Train the Immune System of Patients With Cystic Fibrosis?



¿Podemos entrenar el sistema inmunológico de los pacientes con Fibrosis Quística?

Dear Editor,

The importance of exercise in cystic fibrosis (CF) is well known since regular training is able to reduce lung function decline and to improve exercise tolerance and quality of life.¹ Moreover, exercise can enhance muco-ciliary clearance by inhibiting epithelial sodium channel (ENaC) conductance, decreasing Na re-absorption and favouring airway fluid secretion.² Therefore, current international guidelines recommend it as a physiotherapy adjunct to improve the efficacy of airway clearance techniques (ACTs).³

Beyond that, little is known about the effect of physical activity on inflammation and immune defence mechanisms in CF patients; only few studies are available, focusing mainly on pulmonary physiotherapy techniques.⁴ Differently, some evidences are available in other diseases: in chronic obstructive pulmonary disease (COPD) training programs have demonstrated to exert a positive effect on lymphocyte proliferative response.⁵ Studies on mice models showed that moderate exercise could induce a shift in immune response from a Th1 to a Th2 response.⁶ This change seemed to be associated with reduced viral or bacterial load, inflammation, infection-related morbidity and mortality.^{6,7}

We conducted a prospective interventional single-centre pilot study in the Cystic Fibrosis Unit of our Hospital from February to July 2019, to investigate whether an exercise program can exert a modulator effect on immune system of adults with CF and chronic bronchial infection (CBI).

Inclusion criteria were: stable adult CF patients with CBI, body mass index (BMI) > 19, forced expiratory volume in one second (FEV₁) between 30% and 90% of predicted value, exclusion of immunological or autoimmune disorders. Written informed consent to participate in the study was obtained from participants. Ethics approval was granted by the Ethics Committee of our Hospital.

Exercise training program: A 12-week individualized training program in a dedicated gym under the supervision of a professional personal trainer was planned, with 4 sessions per week of

45–60 min each (adapted to individual physical capability), focused on cardiovascular resistance and strength. A minimum of 3 sessions/week was required to patients. Individual starting capacity for the exercise training program was based on the evaluation of physical fitness during the first week of training and the exercise test at first visit. Patients were instructed how to perform the exercises at the start of the study and their progression was evaluated by the personal trainer once a week. The personal routine was mostly organized in order to train between 60% and 75% of maximal initial effort, based on baseline exercise test, and to have 50% of training dedicated to cardiovascular resistance and 50% to strength, but personalization of the training program was set by the trainer according to individual characteristics.

Within 7 days before the training, protocol included clinical and functional assessment, complete lung function tests (forced spirometry, diffusion capacity of the lungs for carbon monoxide –DLCO– and plethysmography), cardiopulmonary exercise test (CPET), blood and sputum collection. The same procedures were scheduled one week after the end of the training in order to avoid the effects of acute immune response.

For statistical analysis, data normality was checked using Kolmogorov–Smirnov and Pearson omnibus normality tests. For data comparison, Paired *t* test was used to compare parametric data, and the Wilcoxon–Mann–Whitney test was used to compare non-parametric data. Significance was set at *P* < 0.05. GraphPad Prism 8.0 package (GraphPad Software, Inc, USA) was used.

Six patients were recruited, two female and four males, aged 20–33 years (mean 26.17 ± 5.23), all with class I or II CFTR mutations and 3 with pancreatic insufficiency (F508del was present in 5 out of 6 patients, being homozygosis in only 1 patient). Four patients were on chronic treatment with fluticasone (100 to 500mcg/daily) in combination with salmeterol, while 2 patients only used salbutamol on demand. Mean FEV₁ was 57.2 ± 23.6% of predicted, DLCO/VA was 97.7 ± 17.7%, Total Lung Capacity (TLC) 104.2 ± 10.5%.

CBI was due to methicillin-sensitive *Staphylococcus aureus* (MSSA) and *Pseudomonas aeruginosa* (PA) in 5/6 and 4/6 patients respectively. Three patients had both MSSA and PA chronic infection. The target for completion of the training was of 4 sessions per week during the 12 weeks of the study (100%). A specific questionnaire demonstrated a mean completion of the training of