

14. Shibata S, Ajiro M, Hagiwara M. Mechanism-based personalized medicine for cystic fibrosis by suppressing pseudo exon inclusion. *Cell Chem Biol.* 2020, <http://dx.doi.org/10.1016/j.chembiol.2020.08.013>.
15. Gao D, Morini E, Salani M, Krauson JA, Ragavendran A, Erdin S, et al. A deep learning approach to identify new gene targets of a novel therapeutic for human splicing disorders. *BioRxiv.* 2020, <http://dx.doi.org/10.1101/2020.02.03.932103>.
16. Lee M, Roos P, Sharma N, Atalar M, Evans TA, Pellicore MJ, et al. Systematic computational identification of variants that activate exonic and intronic cryptic splice sites. *Am J Hum Genet.* 2017;100:751–65, <http://dx.doi.org/10.1016/j.ajhg.2017.04.001> [End of the form].
17. Bergougnoux A, Délétang K, Pommier A, Varilh J, Houriez F, Altieri JP, et al. Functional characterization and phenotypic spectrum of three recurrent disease-causing deep intronic variants of the CFTR gene. *J Cyst Fibros.* 2019;18:468–75, <http://dx.doi.org/10.1016/j.jcf.2018.10.012>.
18. Morris-Rosendahl DJ, Edwards M, McDonnell MJ, John S, Alton EFWF, Davies JC, et al. Whole-genome sequencing of CFTR reveals a high prevalence of the intronic variant c.3874-4522A>G in cystic fibrosis. *Am J Respir Crit Care Med.* 2020;201:1438–41, <http://dx.doi.org/10.1164/rccm.201908-1541LE>.
19. Harutyunyan M, Huang Y, Mun KS, Yang F, Arora K, Naren AP. Personalized medicine in CF: from modulator development to therapy for cystic fibrosis patients with rare CFTR mutations. *Am J Physiol Lung Cell Mol Physiol.* 2018;314:L529–43, <http://dx.doi.org/10.1152/ajplung.00465.2017>.

Antonio Álvarez^{a,d,e,*} Karina Loo^{a,d,e}
 Paula Fernández-Alvarez^{b,e} Silvia Gartner^{c,e}
 Eva Polverino^{a,d,e} Mario Culebras^{a,d,e} David Clófent^{a,d,e}
 Elena García Arumí^{b,e} Eduardo F. Tizzano^{b,e,1}
 Javier de Gracia^{a,d,e,1}

Extracorporeal membrane oxygenation (ECMO) as bridge therapy to surgery in a patient with acute respiratory distress syndrome (ARDS) due to rupture of a pulmonary hydatid cyst[☆]



Membrana de oxigenación extracorpórea (ECMO) como terapia puente a la cirugía en paciente con síndrome de distrés respiratorio agudo (SDRA) debido a la rotura de un quiste hidatídico pulmonar

To the Editor,

Indications for extracorporeal membrane oxygenation (ECMO), such as short-term life support in patients with severe respiratory or heart failure refractory to conventional treatment, have expanded considerably in the past 20 years.¹ ECMO may be used in acute respiratory distress syndrome (ARDS) and other forms of potentially reversible respiratory failure as a bridge to recovery, definitive surgical intervention,² or transplantation.³ The use of ECMO has also been described in the setting of serious respiratory infections, such as those caused by influenza A (H1N1) virus⁴ and, more recently, severe acute respiratory syndrome coronavirus type 2.⁵ However, scant data are available on its potential use in complications due to parasitic infections.^{6,7} We report the case of a patient with a diagnosis of bilateral pulmonary hydatid cysts undergoing antiparasitic treatment prior to surgery. One of the cysts ruptured, and the patient required vital support with ECMO as a bridge to definitive surgery.

The patient was a 21-year-old Peruvian man, allergic to metami-zole and diazepam, with no toxic habits or medical history of

^a Department of Respiratory Medicine – Adult Cystic Fibrosis Unit, Vall d'Hebron Barcelona Hospital Campus, Universitat Autònoma de Barcelona, Passeig Vall d'Hebron 119-129, 08035 Barcelona, Spain

^b Department of Clinical and Molecular Genetics, Vall d'Hebron Barcelona Hospital Campus, Universitat Autònoma de Barcelona, Passeig Vall d'Hebron 119-129, 08035 Barcelona, Spain

^c Department of Pediatrics – Pediatric Cystic Fibrosis Unit, Vall d'Hebron Barcelona Hospital Campus, Universitat Autònoma de Barcelona, Passeig Vall d'Hebron 119-129, 08035 Barcelona, Spain

^d CIBER Enfermedades Respiratorias (Ciberes), Passeig Vall d'Hebron 119-129, 08035 Barcelona, Spain

^e Vall d'Hebron Institut de Recerca (VHIR), Passeig Vall d'Hebron 119-129, 08035 Barcelona, Spain

* Corresponding author.

E-mail address: aalvarez@vhebron.net (A. Álvarez).

¹ Senior authors from Clinical and Molecular Genetics and Respiratory Departments.

<https://doi.org/10.1016/j.arbres.2020.11.002>

0300-2896/ © 2020 SEPAR. Published by Elsevier España, S.L.U. All rights reserved.

interest, who attended the emergency department with a 3-day history of cough and bloody expectoration, without any other accompanying symptoms. On chest X-ray, 2 masses with well-defined edges were observed in both lower lobes, along with signs of pulmonary hyperinflation (Fig. 1a). Chest computed tomography showed 2 pulmonary cystic lesions: one measuring 10.5 × 9.8 cm in the right lower lobe and the other measuring 6.2 × 6.1 cm in the left lower lobe. Radiological findings were suggestive of uncomplicated pulmonary hydatid cysts. Blood tests were positive for anti-*Echinococcus granulosus* antibodies, so we decided to start antiparasitic treatment with albendazole (400 mg/12 h) and praziquantel (1200 mg/12 h) prior to surgery. The patient's lung function tests showed a restrictive ventilatory pattern.

While waiting for surgery, the patient spontaneously presented with pain in the left hemithorax and cough, followed by expectoration of blood and a small amount of pus. Physical examination of the patient revealed tachypnea (>25 rpm), tachycardia (>130 bpm), hypotension (103/57 mmHg), and SatO₂ 92% with oxygen supply via nasal prongs at 2L per minute. The laboratory tests showed leukocytosis 11,420/μL, with 6.2% eosinophils and CRP of 4.36 mg/dL. Chest X-ray showed an air-fluid level in the basal region of the left hemithorax consistent with complicated hydatid cyst communicating with the airway (Fig. 1B). Within a few hours, the patient presented generalized deterioration and acute respiratory failure and required admission to the intensive care unit (ICU) and urgent orotracheal intubation. Despite protective pulmonary ventilation, the patient worsened progressively with respiratory acidosis, hypercapnia 70 mmHg, Pao₂/Fio₂ < 100 mmHg, severe ventilation difficulty, and a tendency toward arterial hypotension. Given the persistence of the poor respiratory condition consistent with ARDS caused by rupture of the left hydatid cyst, we decided to administer support therapy with veno-venous ECMO (Fig. 1c). The patient received empirical antibiotic treatment with piperacillin/tazobactam and linezolid, and the microbiological cultures carried out ruled out bacterial superinfection. After hemodynamic and respiratory stabilization of the patient was achieved, his subsequent progress was satisfactory, with decreased ventilatory and ECMO support. ECMO was

[☆] Please cite this article as: Gómez-Hernández MT, Martínez EJ, Fuentes MG, Paz M, Rodríguez I, Novoa NM, et al. Membrana de oxigenación extracorpórea (ECMO) como terapia puente a la cirugía en paciente con síndrome de distrés respiratorio agudo (SDRA) debido a la rotura de un quiste hidatídico pulmonar. *Arch Bronconeumol.* 2021;57:503–504.

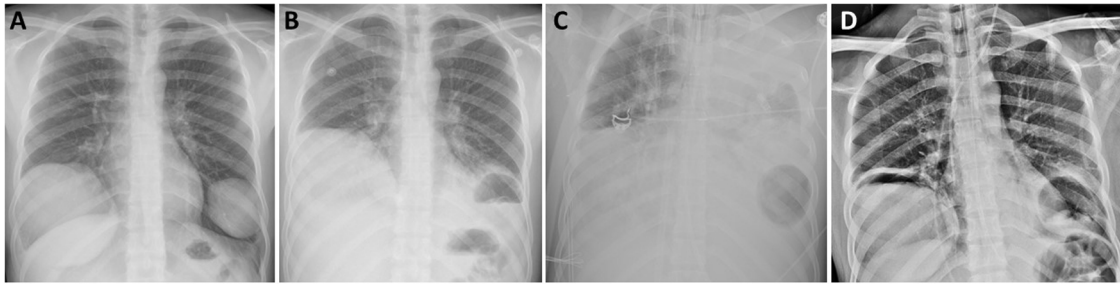


Fig. 1. Chest X-ray at diagnosis showing 2 uncomplicated cystic lesions (A); following rupture of the left lung hydatid cyst (B); air-fluid level after placement of ECMO, showing opacification of the entire left hemithorax and air in the left lung base (C); and after withdrawal of ventilatory support and ECMO (D).

withdrawn completely 10 days after placement, and the patient was extubated 3 days later. He was discharged from the ICU to the hospital ward for rehabilitation treatment based on respiratory physiotherapy prior to the scheduled surgical procedure. One week later, surgical resection of both lung lesions was performed by bilateral thoracotomy without muscle section, consisting of right lower lobectomy and atypical resection of the left anterior-basal segment. During the postoperative period, the only complication was delirium with disorientation and altered level of consciousness, so an assessment by the neurology department was requested. Clinical and radiological evaluation with magnetic resonance imaging of the head established a diagnosis of diffuse microbleeds in a critically ill patient, probably associated with ECMO therapy, that did not require any specific treatment. The patient was discharged on postoperative day 7 after resolution of the neurological syndrome and referred to the infectious diseases department for monitoring of his medical treatment and follow-up.

ARDS associated or not associated with anaphylactic shock following rupture of a pulmonary hydatid cyst is very rare, although several cases have been described.^{5,8,9} However, management with ECMO has only been described in one case so far.⁶ In this setting, veno-venous ECMO support provides good oxygenation and ventilation, and helps minimize ventilatory support and the barotrauma associated with mechanical ventilation.¹⁰ However, ECMO therapy is not free of complications, the most frequent being those of a hemorrhagic or thrombotic nature.¹¹

This case highlights the usefulness of ECMO as a bridge to definitive surgical treatment in the acute management of patients with ARDS due to rupture of a pulmonary hydatid cyst.

References

- Makdisi G, Wang I-W. Extra corporeal membrane oxygenation (ECMO) review of a lifesaving technology. *J Thorac Dis.* 2015;7:E166–176.
- Unai S, Khullar V, Elgharably H, Navia JL. ECMO as a bridge to reoperative cardiac surgery in a patient with cardiogenic shock and severe aortic insufficiency due to an acute aortic valve homograft failure. *Heart Surg Forum.* 2019;22:E281–282.
- Biscotti M, Sonett J, Bacchetta M. ECMO as bridge to lung transplant. *Thorac Surg Clin.* 2015;25:17–25.
- Vaquero S, de Haro C, Peruga P, Oliva JC, Artigas A. Systematic review and meta-analysis of complications and mortality of veno-venous extracorporeal membrane oxygenation for refractory acute respiratory distress syndrome. *Ann Intensive Care.* 2017;7:51.
- Zhan W-Q, Li M-D, Xu M, Lu Y-B. Successful treatment of COVID-19 using extracorporeal membrane oxygenation, a case report. *Eur Rev Med Pharmacol Sci.* 2020;24:3385–9.
- Becker SL, Fähndrich S, Trudzinski FC, Gärtner B, Langer F, Becker TK, et al. Extracorporeal membrane oxygenation (ECMO) as salvage treatment for pulmonary *Echinococcus granulosus* infection with acute cyst rupture. *Int J Infect Dis IJID Off Publ Int Soc Infect Dis.* 2017;64:47–9.
- Lee H-J, Baek J-H, Chae M-H, Joo H, Lee H-J, Chung M-H, et al. A case of vivax malaria complicated by adult respiratory distress syndrome and successful management with extracorporeal membrane oxygenation. *Korean J Parasitol.* 2013;51:551–5.
- Fanne RA, Khamaisi M, Mevorach D, Leitersdorf E, Berkman N, Laxer U, et al. Spontaneous rupture of lung echinococcal cyst causing anaphylactic shock and respiratory distress syndrome. *Thorax.* 2006;61:550.
- Shameem M, Akhtar J, Bhargava R, Ahmed Z, Khan NA, Baneen U. Ruptured pulmonary hydatid cyst with anaphylactic shock and pneumothorax. *Respir Care.* 2011;56:863–5.
- Peek GJ, Mugford M, Tiruvoipati R, Wilson A, Allen E, Thalanany MM, et al. Efficacy and economic assessment of conventional ventilatory support versus extracorporeal membrane oxygenation for severe adult respiratory failure (CESAR): a multicentre randomised controlled trial. *Lancet Lond Engl.* 2009;374:1351–63.
- Thomas J, Kostousov V, Teruya J. Bleeding and thrombotic complications in the use of extracorporeal membrane oxygenation. *Semin Thromb Hemost.* 2018;44:20–9.

María Teresa Gómez-Hernández* Ernest J. Martínez, Marta G. Fuentes, Marta Paz, Israel Rodríguez, Nuria M. Novoa, Marcelo F. Jiménez,

Departamento de Cirugía Torácica, Hospital Universitario de Salamanca, Salamanca, Spain

Unidad de Cuidados Intensivos, Hospital Universitario de Salamanca, Salamanca, Spain

Departamento de Cirugía Torácica, Hospital Universitario de Salamanca, Salamanca, Spain

Unidad de Cuidados Intensivos, Hospital Universitario de Salamanca, Salamanca, Spain

Departamento de Cirugía Torácica, Hospital Universitario de Salamanca, Salamanca, Spain

Corresponding author

E-mail address: mtgh@usal.es (M.T. Gómez-Hernández).

<https://doi.org/10.1016/j.arbr.2021.05.005>

1579-2129/ © 2020 SEPAR. Published by Elsevier España, S.L.U. All rights reserved.