

Clinical Image

Tracheal Stenosis Due to IgG4-Related Fibrosing Mediastinitis[☆]

Estenosis traqueal por mediastinitis fibrosante relacionada con enfermedad por IgG4

Laura Arroyo Pareja,^a Ana Triviño,^{a,*} Carolina España^b

^a Servicio de Cirugía Torácica, Hospital Universitario Puerta del Mar, Cádiz, Spain

^b Servicio de Neumología, Hospital Universitario Puerta del Mar, Cádiz, Spain



We report the case of a 62-year-old woman undergoing study for progressive dyspnea. In the chest CT scan, concentric tracheal stenosis was visualized, caused by a right paratracheal mass measuring 5 × 2 cm.

Fiberoptic bronchoscopy revealed 75% stenosis with normal tracheal mucosa. The percutaneous fine needle aspiration performed endoscopically showed respiratory epithelial cells without atypia.

We performed rigid bronchoscopy (RB) to obtain a new biopsy. The histopathological and immunohistochemical studies found tracheal mucosa with fibrosis and lymphoplasmacytic infiltration consistent with IgG4-related fibrosing mediastinitis (FM).

After obtaining the diagnosis, treatment with corticosteroids began. Subsequently, RB was programmed for placement of a Dumon[®] tracheal stent measuring 18 × 40 mm.

FM is a rare entity that can be classified as idiopathic or secondary. IgG4-related FM has recently been linked to some cases defined until now as idiopathic. This disease must be included in the differential diagnosis of fibrosing mediastinitis¹ and mediastinal and tracheal neoplasms, because, as in our patient, these entities can mimic even malignant tracheal disease.

Although treatment can consist of corticosteroids, our patient required placement of a tracheal stent due to critical stenosis of the airway (Fig. 1).

Reference

1. Takanashi S, Akiyama M, Suzuki K, Otomo K, Takeuchi T. IgG4-related fibrosing mediastinitis diagnosed with computed tomography-guided percutaneous needle biopsy: two case reports and a review of the literature. *Medicine (Baltimore)*. 2018;97:e10935.

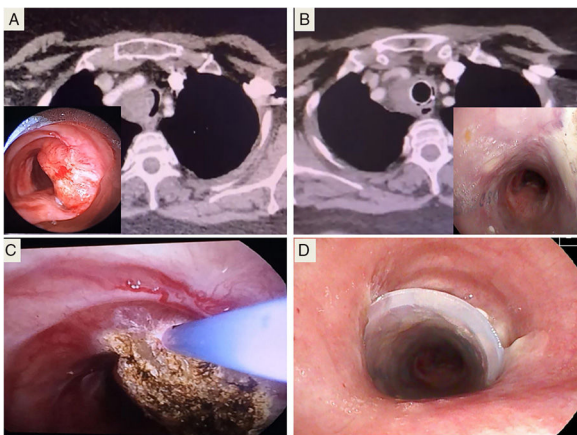


Fig. 1. (A) Bronchoscopy and CT image of tracheal stenosis. (B) Outcome after treatment with corticosteroids and stenting, after 4 months. (C) Argon plasma coagulation, after biopsy. (D) Placement of Dumon[®] stent.

[☆] Please cite this article as: Arroyo Pareja L, Triviño A, España C. Estenosis traqueal por mediastinitis fibrosante relacionada con enfermedad por IgG4. *Arch Bronconeumol*. 2019;55:533.

* Corresponding author.

E-mail address: atrivi.17@hotmail.com (A. Triviño).