

Clinical Image

Multiple Pulmonary and Hepatic Arteriovenous Malformations in a Patient With Rendu-Osler-Weber Disease

Malformaciones arteriovenosas pulmonares y hepáticas múltiples en un paciente con enfermedad de Rendu-Osler-Weber

Emine Izgi, Fadime Guven, Hayri Ogul*

Department of Radiology, Faculty of Medicine, Ataturk University, Erzurum, Turkey

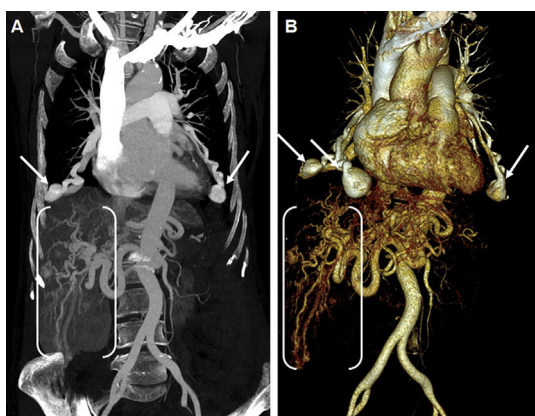


Fig. 1. Coronal MIP image (A) and anterior view volume rendering 3D (B) thoracoabdominal CT angiographies showing multiple pulmonary (arrows) and hepatic arteriovenous malformations (between brackets).

A 63-year-old female presented with shortness of breath. Thoracoabdominal computed tomography (CT) angiography demonstrated multiple pulmonary and hepatic arteriovenous malformations (Fig. 1). Rendu-Osler-Weber disease is characterized by multiple mucocutaneous telangiectasias and visceral arteriovenous malformations.

Osler-Weber-Rendu is an autosomal dominant disease. It is characterized by multiple mucocutaneous telangiectasias, recurrent epistaxis, and visceral arteriovenous malformations. Vascular structures of the lung and gastrointestinal tract frequently involve.¹ With the advent of multidetector CT, hepatic and pulmonary involvement with Rendu-Osler-Weber is commonly recognized.¹

In liver involvement of Rendu-Osler-Weber disease, there is shunting from the hepatic artery to the portal or hepatic veins.² These vascular anastomoses can be diagnosed by CT or catheter angiography. Transcatheter embolization of hepatic or pulmonary arteries can be performed in lung or liver involvement of patients with Rendu-Osler-Weber disease. Transplantation can be performed in patients with liver or pulmonary insufficiency.³

References

- Ogul H, Aydın Y, Özgökçe M, Orsal E, Kantarci M, Eroglu A. Pulmonary arteriovenous malformations and hepatic involvement in a patient with Osler-Rendu-Weber disease. *Ann Thorac Surg.* 2012;94:e155.
- García-Tsao G, Korzenik JR, Young L, Henderson KJ, Jain D, Byrd B, et al. Liver disease in patients with hereditary hemorrhagic telangiectasia. *N Engl J Med.* 2000;343:931–6.
- Lacombe P, Lacout A, Marcy PY, Binsse S, Sellier J, Bensalah M, et al. Diagnosis and treatment of pulmonary arteriovenous malformations in hereditary hemorrhagic telangiectasia: an overview. *Diagn Interv Imaging.* 2013;94:835–48.

* Corresponding author.
E-mail address: drhogul@gmail.com (H. Ogul).