

## Systemic-to-Pulmonary Artery Fistula as a Late Complication of Biliary Surgery<sup>☆</sup>



### Fístula arterio-arterial sistémico-pulmonar como complicación tardía de cirugía biliar

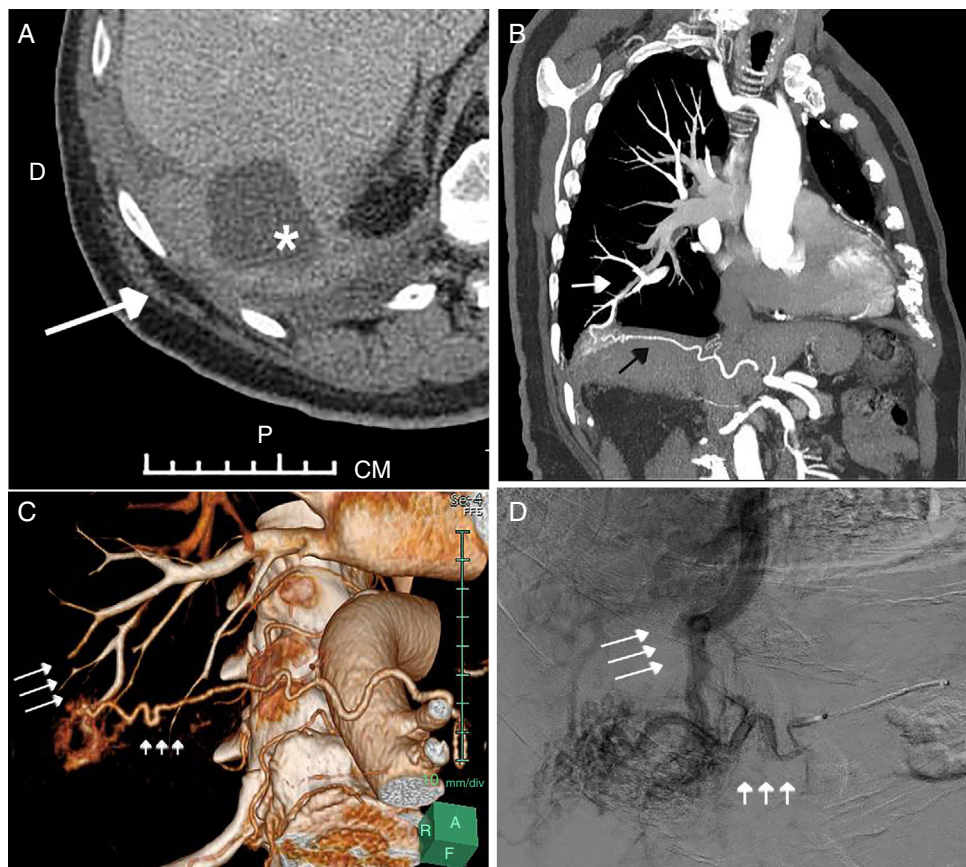
To the Editor:

Anastomosis between the systemic and pulmonary circulation can be congenital or acquired. Approximately 15% of systemic-pulmonary fistulas (SPF) are congenital, and associated with heart disease or hypoplasia of the pulmonary artery.<sup>1</sup> Acquired SPF, the most common kind, may be due to inflammation, infection, trauma, surgery, or cancer, among others. SPF mostly occur between a bronchial artery and subsegmental branches of the pulmonary artery. Exceptionally, arterio-arterial anastomosis can occur between abdominal systemic arteries (hepatic artery or inferior phrenic artery) and pulmonary arteries.<sup>2</sup> We report the case of SPF between an abdominal systemic artery (right inferior phrenic artery) and a pulmonary artery as a late complication of a biliary surgery.

Our patient was a 79-year-old man who consulted due to repeated, self-limiting episodes of hemoptysis. Significant history

included laparoscopic cholecystectomy compounded with a right subphrenic abscess (resolved with drainage and antibiotics) 2 years previously (Fig. 1A). Hemoptysis originating in the upper airway and digestive tract was ruled out by fiberoptic bronchoscopy and gastrointestinal endoscopy, but in a computed tomography (CT) scan of the chest with contrast medium, an opacity was identified in the right postero-basal segment in contact with the diaphragmatic surface that was surrounded by characteristically tortuous vessels. Given these findings, suggestive of a vascular malformation, we decided to perform a CT angiogram of the chest, which confirmed the existence of an SPF between a hypertrophic right inferior phrenic artery and a subsegmental branch of the pulmonary artery of the right lower lobe (Fig. 1B and C). This SPF was treated by selective embolization with Onyx<sup>®</sup> (an ethylene vinyl alcohol copolymer) of the systemic feeding artery of the right inferior phrenic artery (Fig. 1D). There have been no subsequent complications nor have any new episodes of hemoptysis occurred to date.

SPF are abnormal anastomosis between systemic arteries and pulmonary vessels; they may be congenital or, more frequently, acquired. The latter usually occur in the presence of pleural adhesions as a result of various long-standing inflammatory processes of the chest, such as bronchiectasis (particularly in patients with cystic fibrosis), tuberculosis, or chronic empyema. These processes



**Fig. 1.** (A) Axial abdominal CT image showing a mass in the anterior mediastinum (asterisk). Note the presence of inflammatory changes in the right costophrenic sinus (arrow). (B) Maximum intensity projection (MIP) coronal reconstruction of the CT angiogram of the chest and upper abdomen showing a communication between a hypertrophic right inferior phrenic artery (black arrow) and a subsegmental pulmonary artery in the right lower lobe (white arrow). (C) Volume rendering of CT angiogram of the systemic-pulmonary fistula (short arrows indicate right inferior phrenic artery, while long arrows indicate the pulmonary artery). (D) Angiogram showing retrograde filling of pulmonary arteries (long arrows) from a tortuous, hypertrophic right inferior phrenic artery (short arrows).

<sup>☆</sup> Please cite this article as: Fra Fernández S, Gorospe Sarasúa L, Olavarría Delgado A, Velasco Álvarez D. Fístula arterio-arterial sistémico-pulmonar como complicación tardía de cirugía biliar. Arch Bronconeumol. 2019;55:227–228.

are often associated with pleural fibrosis and the resulting decrease in pulmonary blood flow, which cause hypertrophy of the systemic arteries. Although several cases of SPF due to surgical interventions have been described (aortocoronary bypass surgery, thoracotomies, and video-assisted thoracoscopic surgery), very few cases have been reported in association with abdominal surgery.<sup>1,3</sup> In most cases, SPF are asymptomatic, although one of the most common presenting symptoms is hemoptysis. Other less common symptoms have been described, such as dyspnea or chronic chest pain, and complicated cases with pulmonary hypertension or endocarditis have also been documented. This disease can be diagnosed with CT angiogram or arteriography, and several treatment options are available: surgery, endovascular treatment (embolization), or observation. In patients like ours, with repeated episodes of moderate hemoptysis, embolization is often the first-choice treatment.<sup>4</sup>

In conclusion, the SPF secondary to biliary surgery are exceptional. For this reason, when a fistula in an inferior phrenic artery is observed in a patient with hemoptysis, the index of suspicion should be high, and the patient's history and previous tests should be reviewed to correctly identify its cause.

## References

1. Shimmyo T, Omori T, Hirano A, Masuda M. Secondary systemic artery to pulmonary artery and pulmonary vein fistulas following the video-assisted thoracic surgery for pneumothorax: a case report. *Surg Case Rep*. 2018;4:1.
2. Webb WR, Jacobs RP. Transpleural abdominal systemic artery-pulmonary artery anastomosis in patients with chronic pulmonary infection. *Am J Roentgenol*. 1977;129:233–6.
3. Riehl G, Chaffanjon P, Frey G, Sessa C, Brichon PY. Postoperative systemic artery to pulmonary vessel fistula: analysis of three cases. *Ann Thorac Surg*. 2003;76:1873–7.
4. Zaga Ortega JA, Ramírez Delphino E, Carrillo Díaz A, Quispe Atuncar L. Recurrent hemoptysis due to systemic-pulmonary anastomosis of the inferior right phrenic artery. Treatment by percutaneous embolization. *Arch Bronconeumol*. 2002;38:95–8 [Article in Spanish].

Sara Fra Fernández,<sup>a,\*</sup> Luis Gorospe Sarasúa,<sup>b</sup>  
Andreina Olavarría Delgado,<sup>b</sup> Diurbis Velasco Álvarez<sup>c</sup>

<sup>a</sup> *Servicio de Cirugía Torácica, Hospital Universitario Ramón y Cajal, Madrid, Spain*

<sup>b</sup> *Servicio de Radiodiagnóstico, Hospital Universitario Ramón y Cajal, Madrid, Spain*

<sup>c</sup> *Servicio de Neumología, Hospital Universitario Ramón y Cajal, Madrid, Spain*

\* Corresponding author.

E-mail address: [sarafrfernandez@gmail.com](mailto:sarafrfernandez@gmail.com) (S. Fra Fernández).

1579-2129/

© 2018 SEPAR. Published by Elsevier España, S.L.U. All rights reserved.