

described during the treatment of brain lesions, this phenomenon has been observed in up to 15% of patients with melanoma who receive immunotherapy, but it is rare in lung cancer,⁶ with a prevalence in the latter of less than 2%,⁵ apparently caused by T cells infiltrating the tumor, with the resulting edema and/or necrosis. The absence of true progression can only be confirmed non-invasively with radiological studies,⁷ so it is sometimes very difficult to decide whether to continue or suspend treatment. This has led to the WHO or RECIST criteria for the definition of therapeutic response being replaced by new immune-mediated response criteria, such as the immune-related response criteria (irRC), the immune-related response evaluation criteria in solid tumors (irRECIST1.1), and the immune RECIST (iRECIST).^{8–10} The main contribution of these new response criteria (which define pseudoprogression and unconfirmed progression) is to underline that patients may be responding favorably to treatment despite a temporary increase in the tumor burden, or even after the appearance of new lesions. Definitive confirmation as to whether a possible pseudoprogression is true disease progression requires an increase in tumor volume confirmed in 2 imaging studies conducted at least 4–8 weeks apart.¹¹

In summary, it appears that immunotherapy is changing the treatment of lung cancer,^{12,13} but its use has brought with it new side effects and new challenges in the assessment of radiological response, which will require new training for professionals involved in the treatment and follow-up of these patients. Despite the fact that pseudoprogression seems to be rare in patients with non-small cell lung cancer treated with immunotherapy, the possibility of performing invasive techniques should always be evaluated, since a dense inflammatory cell infiltrate in biopsy material can help differentiate pseudoprogression from progression.¹⁴ Another factor to take into account is that pseudoprogression is not generally associated with a significant clinical deterioration of the patient, a situation which would usually indicate real progression.⁵

References

- Borghaei H, Paz-Ares L, Horn L, Spigel DR, Steins M, Ready NE, et al. Nivolumab versus docetaxel in advanced nonsquamous non-small-cell lung cancer. *N Engl J Med*. 2015;373:1627–39.
- Antonia SJ, Villegas A, Daniel D, Vicente D, Murakami S, Hui R, et al., PACIFIC Investigators. Durvalumab after chemoradiotherapy in stage III non-small-cell lung cancer. *N Engl J Med*. 2017;377:1919–29.
- Kazandjian D, Suzman DL, Blumenthal G, Mushti S, He K, Libeg M, et al. FDA approval summary: Nivolumab for the treatment of metastatic non-small cell lung cancer with progression on or after platinum-based chemotherapy. *Oncologist*. 2016;21:634–42.
- Awada G, Klastersky J. Supportive care in the era of immunotherapies for advanced non-small-cell lung cancer. *Curr Opin Oncol*. 2018;30:98–104.
- Solinas C, Porcu M, Hlavata Z, de Silva P, Puzzone M, Willard-Gallo K, et al. Critical features and challenges associated with imaging in patients undergoing cancer immunotherapy. *Crit Rev Oncol Hematol*. 2017;120:13–21.
- Rusch VW, Chaff J, Hellmann M. KEYNOTE-024: unlocking a pathway to lung cancer cure? *J Thorac Cardiovasc Surg*. 2018;155:1777–80.
- Chiou VL, Burotto M. Pseudoprogression and immune-related response in solid tumors. *J Clin Oncol*. 2015;33:3541–3.
- Wolchok JD, Hoos A, O'Day S, Weber JS, Hamid O, Lebbé C, et al. Guidelines for the evaluation of immune therapy activity in solid tumors: immune-related response criteria. *Clin Cancer Res*. 2009;15:7412–20.
- Bohnsack O, Hoos A, Ludajic K. Adaptation of the immune related response criteria: IRRECIST. *Ann Oncol*. 2014;25 Suppl. 4:iiv369.
- Seymour L, Bogaerts J, Perrone A, Ford R, Schwartz LH, Mandrekas S, et al., RECIST working group. iRECIST: guidelines for response criteria for use in trials testing immunotherapeutics. *Lancet Oncol*. 2017;18:e143–52.
- Wang GX, Kurra V, Gainor JF, Sullivan RJ, Flaherty KT, Lee SI, et al. Immune checkpoint inhibitor cancer therapy: spectrum of imaging findings. *Radiographics*. 2017;37:2132–44.
- Forde PM, Chat JE, Smith KN, Anagnostou V, Cottrell TR, Hellmann MD, et al. Neoadjuvant PD-1 blockade in resectable lung cancer. *N Engl J Med*. 2018;378:1976–86.
- Gandhi L, Rodríguez-Abreu D, Gadgeel S, Esteban E, Felip E, de Angelis F, et al., KEYNOTE-189 Investigators. Pembrolizumab plus chemotherapy in metastatic non-small-cell lung cancer. *N Engl J Med*. 2018;378:2078–92.
- Izumida T, Kawagishi Y, Tsuji H. Pseudoprogression in lung adenocarcinoma during treatment with nivolumab. *BMJ Case Rep*. 2017;2017, pii:bcr-2017-219919.

Alberto Cabañero,^{a,*} Luis Gorospe,^b Maria Eugenia Olmedo,^c Laura Mezquita^d

^a Servicio de Cirugía Torácica, Hospital Universitario Ramón y Cajal, Madrid, Spain

^b Servicio de Radiodiagnóstico, Hospital Universitario Ramón y Cajal, Madrid, Spain

^c Servicio de Oncología Médica, Hospital Universitario Ramón y Cajal, Madrid, Spain

^d Department of Adult Medicine, Institut de Cancérologie Gustave Roussy, Paris, France

* Corresponding author.

E-mail address: alberto.cabanero@salud.madrid.org (A. Cabañero).

1579-2129/

© 2018 SEPAR. Published by Elsevier España, S.L.U. All rights reserved.

Electromagnetic Navigation Placement of Intratumoral Gold Fiducials for Stereotactic Radiation Therapy in Lung Cancer[☆]



Colocación de fiduciales de oro intraneoplasia pulmonar mediante navegación electromagnética para tratamiento con radioterapia estereotáctica

To the Editor,

Remarkable advances have been made in the treatment of lung cancer in recent years with the use of drugs aimed at therapeutic targets that have helped improve the prognosis of patients with disseminated disease. However, resectable lung tumors are

being identified in increasing numbers of patients who cannot undergo surgery due to functional impairment, advanced age, or severe limiting comorbidities. Stereotactic body radiation therapy (SBRT) is a potentially curative alternative in the subgroup of patients with stage I lung cancers who are not candidates for surgery.^{1,2} SBRT uses a combination of fixed, reproducible anatomical structures as a reference for the administration of higher doses of radiation per fraction to the target lesion. For successful treatment and minimization of potential side effects, it is essential that the lesion is precisely identified. This underlying premise has supported the decision to implant fiducials within the tumor, as an essential preliminary step before delivering SBRT.

We report 2 cases of stage I lung cancer, unsuitable for surgery, in whom, after a multidisciplinary assessment by the chest tumor committee of our hospital, it was agreed to proceed with the implantation of fiducials using electromagnetic navigation (EMN) for subsequent treatment with SBRT. Our 2 patients constitute the first reported use of this technique in Spain.

[☆] Please cite this article as: de Vega Sánchez B, Disdier Vicente C, Ponte CM, Cantalapiedra del Pie R. Colocación de fiduciales de oro intraneoplasia pulmonar mediante navegación electromagnética para tratamiento con radioterapia estereotáctica. *Arch Bronconeumol*. 2019;55:169–171.

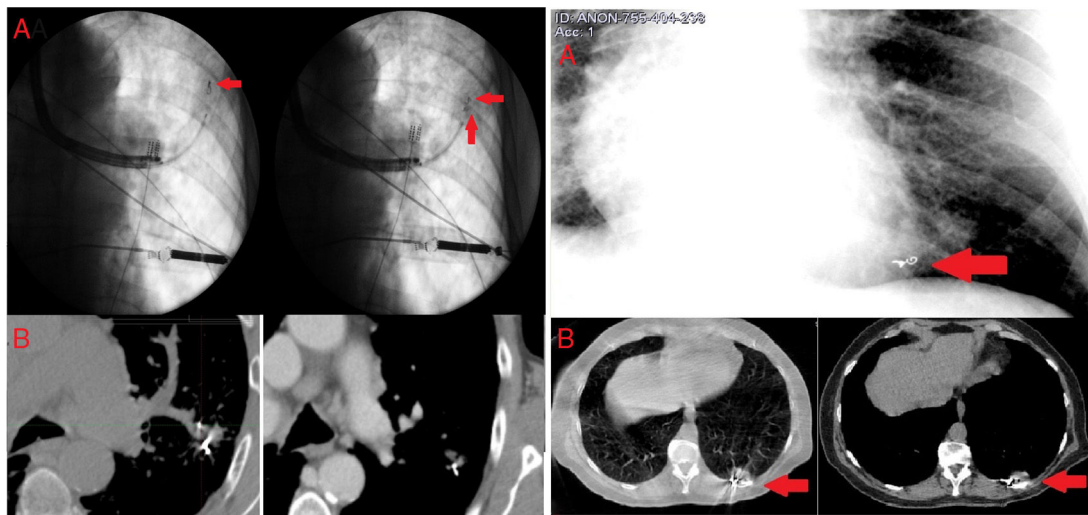


Fig. 1. Left (case 1). (A) Fluoroscopy view of the introduction of the endobronchial brush catheter preloaded with the fiducial via the extendible working channel (left). Placement of second intratumoral fiducial (right). (B) Chest CT after endoscopic implantation, confirming presence of the intratumoral fiducial, with migration of the second. Right (case 2). (A) Low-radiation fluoroscopy view of 2 intratumoral fiducials during bronchoscopy. (B) Chest CT after endoscopic implantation, confirming presence of 2 intratumoral fiducials with no migration.

The first was a 75-year-old man diagnosed with stage T1bN0M0² squamous cell lung cancer in the left upper lobe. The patient's lung function tests (showing moderate airflow obstruction, serious lung diffusion deterioration, and marked desaturation on the 6-minute walk test) and comorbidities (pulmonary hypertension group IV) were decisive factors in the choice of SBRT as optimal cancer treatment. The size of the lesion (17×19 mm), its peripheral location, and a bronchus sign on radiology led us to decide on the use of EMN to guide the bronchoscopic placement of intratumoral fiducial markers.

Standard flexible bronchoscopy was performed for aspiration of secretions under deep sedation with a continuous infusion of single-agent propofol. In a second procedure (after creation of the electromagnetic field), the lesion was accessed by EMN, with an estimated distance from the epicenter of 16 mm. An endobronchial brush catheter (Olympus disposable cytology brush BC-202D-3010[®]) manually pre-loaded with a gold Visicoil[®] fiducial (0.35×10 mm) was advanced through the extendible working channel, and the fiducial was correctly placed in the lesion under fluoroscopic control. A second Visicoil[®] fiducial (0.35×10 mm) was placed in the same way, without complications (Fig. 1, left, A). Ten days later (waiting time required to generate airway edema and fibrosis, required for the correct anchoring of the fiducial marker³), a chest computed tomography was performed, confirming that 1 fiducial remained in place, while the other had migrated (Fig. 1, left, B).

The second case was a 60-year-old woman with a diagnosis of synchronous double lung cancer: small-cell lung cancer in the right upper lobe (lesion 1) and peripheral pulmonary nodule located in the left lower lobe, with a histological diagnosis of stage T1cN0M0² lung adenocarcinoma (lesion 2). The patient first received systemic chemotherapy with carboplatin, etoposide, and cisplatin, and as lesion 1 had shown complete tumor response, we decided to continue treatment with SBRT to lesion 2, due to its size (24×19 mm), peripheral location, and a bronchus sign on radiology.

The procedure was the same as described for the first case with respect to sedation, outpatient setting, and technique; using EMN, we were able to arrive within an estimated 19 mm from the epicenter of the lesion. Subsequently, 2 fiducials (Visicoil

[®] 0.50×10 mm and Visicoil[®] 0.35×10 mm) were placed via 2 manually preloaded endobronchial brush catheters under fluoroscopy control, without complications. Follow-up chest computed tomography carried out 10 days after the procedure confirmed the presence of both intratumoral fiducials, with no migration (Fig. 1, right).

Given the functional limitations of these patients, the chest tumor committee of our hospital decided to administer SBRT; and in view of the characteristics of the lesions (size, site, and bronchus signs), intratumoral fiducials were implanted using EMN. Several different techniques have been described for the implantation of fiducials in lung tumors, using transthoracic, intravascular, and endoscopic routes. However, the latter has a better safety profile, with fewer documented complications (lower incidence of pneumothorax, pulmonary infarctions and/or hematomas when compared with other techniques). The boom in technological advances has seen the development of several types of endoscopic approaches: standard transbronchial puncture, radial/linear endobronchial ultrasound-guided transbronchial puncture, and, more recently EMN, the latter being a safe alternative with lower complication rates than with previously described techniques.⁴⁻⁷

Intratumoral placement of fiducials is of great importance in SBRT, because tumor movement can be appropriately monitored during delivery of the treatment, thus reducing treatment margins and minimizing possible secondary tissue damage in adjacent healthy structures.

Acknowledgements

We thank the members of the Chest Tumor Committee of Clinical Hospital of Valladolid.

References

- Schroeder C, Hejal R, Linden PA. Coil spring fiducial markers placed safely using navigation bronchoscopy in inoperable patients allows accurate delivery of CyberKnife stereotactic radiosurgery. *J Thorac Cardiovasc Surg.* 2010;140:1137-42.

2. Goldstraw P, Chansky K, Crowley J, Rami-Porta R, Asamura H, Eberhardt WE, et al. The IASLC Lung Cancer Staging Project: proposals for revision of the TNM stage groupings in the forthcoming (eighth) edition of the TNM classification for lung cancer. *J Thorac Oncol*. 2016;11:39–51.
3. Imura M, Yamazaki K, Shirato H, Onimaru R, Fujino M, Shimizu S, et al. Insertion and fixation of fiducial markers for setup and tracking of lung tumors in radiotherapy. *Int J Radiat Oncol Biol Phys*. 2005;63:1442–7.
4. Anantham D, Feller-Kopman D, Shanmugham LN, Berman SM, DeCamp MM, Gangadharan SP, et al. Electromagnetic navigation bronchoscopy-guided fiducial placement for robotic stereotactic radiosurgery of lung tumors: a feasibility study. *Chest*. 2007;132:930–5.
5. Belanger AR, Zagar T, Akulian JA. Convex endobronchial ultrasound-guided fiducial placement for malignant central lung lesions: a case series. *J Bronchology Interv Pulmonol*. 2016;23:46–50.
6. Steinfurt DP, Siva S, Kron T, Chee RR, Ruben JD, Ball DL, et al. Multimodality guidance for accurate bronchoscopic insertion of fiducial markers. *J Thorac Oncol*. 2015;10:324–30.
7. Khandhar SJ, Bowling MR, Flandes J, Gildea TR, Hood KL, Krinsky WS, et al., for the NAVIGATE Study Investigators. Electromagnetic navigation bronchoscopy to access lung lesions in 1,000 subjects: First results of the prospective, multicenter NAVIGATE study. *BMC Pulm Med*. 2017;17:59.

Blanca De Vega Sánchez,^{a,*} Carlos Disdier Vicente,^{a,b}
Carmen Maria Ponte,^c Rocio Cantalapiedra del Pie^c

^a *Unidad de broncoscopias y técnicas pleurales, Servicio de Neumología, Hospital Clínico Universitario de Valladolid, Valladolid, Spain*

^b *Centro de Investigación Biomédica en Red de Enfermedades Respiratorias (CIBERES), Valladolid, Spain*

^c *Servicio de Oncología Radioterápica, Hospital Recoletas Campo Grande, Valladolid, Spain*

* Corresponding author.

E-mail address: blancadevegasanchez@gmail.com

(B. De Vega Sánchez).

1579-2129/

© 2018 SEPAR. Published by Elsevier España, S.L.U. All rights reserved.