

María Montes Ruiz-Cabello,^a Emilio Guirao Arrabal,^{b,*}
Manuel Gallardo Medina,^a David Vinuesa García^c

^a Unidad de Neumología, Hospital Universitario San Cecilio, Granada, Spain

^b Unidad de Medicina Interna, Hospital Universitario San Cecilio, Granada, Spain

^c Unidad de Enfermedades Infecciosas, Hospital Universitario San Cecilio, Granada, Spain

* Corresponding author.

E-mail address: emilio.guirao@gmail.com (E. Guirao Arrabal).

1579-2129/

© 2018 SEPAR. Published by Elsevier España, S.L.U. All rights reserved.

Clinical Deterioration Due to *Exophiala dermatitidis* in a Patient With Cystic Fibrosis[☆]



Deterioro clínico por *Exophiala dermatitidis* en un paciente con fibrosis quística

To the Editor,

An increase in respiratory isolates of *Exophiala dermatitidis* has been described in recent years in patients with cystic fibrosis (CF). We report the case of a CF patient with chronic *E. dermatitidis* bronchial infection.

This was a 21-year-old woman who had been diagnosed with genotype F508del/3849+1G>A CF at the age of 3 months. Chest computed tomography (CT) revealed multiple cylindrical, cystic, and string-of-pearls bronchiectasis in both lungs. Spirometry showed moderate-severe pulmonary obstruction with a forced expiratory volume in 1 second (FEV₁) of 1680 ml (53% predicted). Pancreatic insufficiency and intermittent bronchial infection caused by methicillin-sensitive *Staphylococcus aureus*, *Pseudomonas aeruginosa*, and *Achromobacter xylosoxidans* were detected. The patient had shown declining lung function, and in recent years only *E. dermatitidis* was isolated from sputum microbiology studies. Given her clinical deterioration and the absence of bacterial growth, we performed a bronchoscopy, obtaining bronchial aspirate (BAS) and bronchoalveolar lavage (BAL) samples. Selective media, Sabouraud agar and blood agar, were seeded quantitatively and incubated for 5 days. MALDI-TOF mass spectrometry was used for the identification of the different pathogens. *E. dermatitidis* grew from both BAL and BAS, and antibiotic sensitivity testing was performed with amphotericin B and voriconazole using the Etest[®] method, obtaining MICs of 0.1 and 0.023, respectively. Treatment with oral voriconazole 300 mg/12 h began, but adverse effects (hallucinations and altered liver profile) led the dose to be reduced to the maximum tolerable level of 100 mg/12 h. During follow-up, the patient has shown important clinical improvement and reduced exacerbations, despite persistent isolation of the fungus.

The prevalence of *E. dermatitidis* in CF patients varies between 2% and 15%.¹ This may be due to the lack of standardized procedures for the detection of this organism in sputum samples. *E. dermatitidis* is a slow-growing opportunistic fungus that is not ubiquitous, and as such is generally an uncommon contaminant in microbiology laboratories. It is mostly detected in patients with CF, so isolation in a non-CF patient should prompt suspicion.²

It was first described in 1990,³ and some cases have been published since then. In 2010, the first case of pigmented sputum

was described, with the black flecks being attributed to fungal hyphae.⁴ In 2017, Grenouillet et al. published 2 cases of patients with bronchiectasis and chronic persistent *E. dermatitidis* colonization which led to the diagnosis of CF.²

For the definitive diagnosis of this fungus, the sample must be cultured in Sabouraud agar, incubated at room temperature or 30 °C, and repeated isolates must be obtained. Cultures must be observed for 3–4 weeks, although colonies are usually detected in less than 7 days.⁵ The colonies are small at first, and over time increase in size and acquire a characteristic intense olive black or dark brown color (Fig. 1). However, *E. dermatitidis* isolation is sometimes complicated, and the use of appropriate media, such as erythritol-chloramphenicol agar (ECA) can increase the recovery rate.⁶ Molecular techniques (LAMP or reverse hybridization) can be powerful alternatives to culture media, increasing the rate of detection in sputum samples.⁶

In patients with CF, chronic or intermittent *E. dermatitidis* isolation usually has no clinical repercussions, although some cases have been reported, such as that of a child with CF who presented symptoms of dyspnea due to *E. dermatitidis* pneumonia.⁷ Two prospective studies in a Swedish cohort of 98 CF patients over 12 years of age found *E. dermatitidis* or elevated serum levels of IgG antibodies to *E. dermatitidis* to be associated with pancreatic insufficiency, more frequent colonization by non-tuberculous mycobacteria, increased inflammatory markers, requirements for more frequent intravenous antibiotic treatment, and lower FEV₁.⁸ Although the clinical impact of this pathogen is still pending investigation, its presence in the respiratory tract must be monitored as it is currently considered to be an emerging opportunistic pathogen in CF.⁹

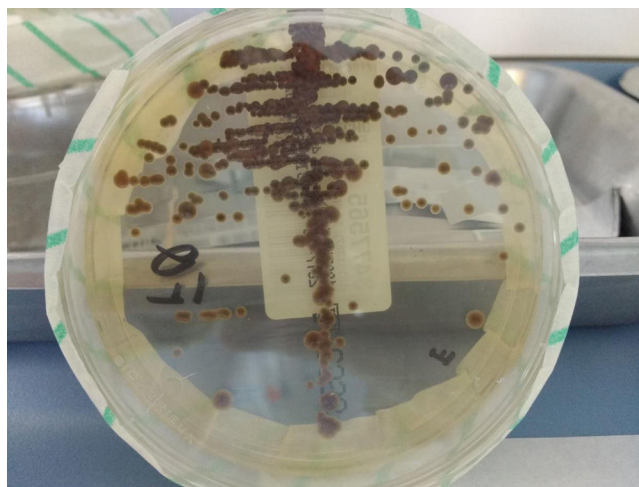


Fig. 1. *Exophiala dermatitidis* colonies in Sabouraud agar with chloramphenicol.

[☆] Please cite this article as: Martín Ramírez A, Erro Iribarren M, Buendía Moreno B, María Girón R. Deterioro clínico por *Exophiala dermatitidis* en un paciente con fibrosis quística. Arch Bronconeumol. 2019;55:162–163.

References

1. Oliver A, Alarcón T, Caballero E, Cantón R. Diagnóstico microbiológico de la colonización-infección broncopulmonar en el paciente con fibrosis quística. *Enferm Infecc Microbiol Clin.* 2009;27:89–104.
2. Grenouillet F, Cimon B, Pana-Katali H, Person C, Gagnet-Brun M, Malinge MC. *Exophiala dermatitidis* revealing cystic fibrosis in adult patients with chronic pulmonary disease. *Mycopathologia.* 2018;183:71–9.
3. Haase G, Skopnik H, Kusenbach G. *Exophiala dermatitidis* infection in cystic fibrosis. *Lancet.* 1990;336:188–9.
4. Griffard EA, Guajardo JR, Cooperstock MS, Scoville CL. Isolation of *Exophiala dermatitidis* from pigmented sputum in a cystic fibrosis patient. *Pediatr Pulmonol.* 2010;45:508–10.
5. García-Martos P, Márquez A, Gené J. Infecciones humanas por levaduras negras del género *Exophiala*. *Rev Iberoam Micol.* 2002;19:72–9.
6. Chen M, Kondori N, Shuwen D, Gerrits van den Ende AHG, Lackner M, Liao W, et al. Direct detection of *Exophiala* and *Scedosporium* species in sputa of patients with cystic fibrosis. *Med Mycol.* 2017. <http://dx.doi.org/10.1093/mmy/myx108>.
7. Kusenbach G, Skopnik H, Haase G, Friedrichs F, Döhmen H. *Exophiala dermatitidis* pneumonia in cystic fibrosis. *Eur J Pediatr.* 1992;151:344–6.
8. Kondori N, Lindblad A, Welinder-Olsson C, Wennerås C, Gilljam M. Development of IgG antibodies to *Exophiala dermatitidis* is associated with inflammatory responses in patients with cystic fibrosis. *J Cyst Fibros.* 2014;13:391–9.
9. Lebecque P, Leonard A, Huang D, Reychler G, Boeras A, Leal T, et al. *Exophiala (Wangiella) dermatitidis* and cystic fibrosis. Prevalence and risk factors. *Med Mycol.* 2010;48 Suppl. 1:S4–9.

Alexandra Martín Ramírez,^{a,b,*} Marta Erro Iribarren,^{b,c}
Buenaventura Buendía Moreno,^{a,b} Rosa María Girón^{b,c}

^a Servicio de Microbiología y Parasitología, Hospital Universitario de la Princesa, Madrid, Spain

^b Instituto de Investigación Sanitaria de la Princesa, Madrid, Spain

^c Servicio de Neumología, Hospital Universitario de la Princesa, Madrid, Spain

* Corresponding author.

E-mail address: sandra.martin.ramirez@gmail.com

(A. Martín Ramírez).

1579-2129/

© 2018 SEPAR. Published by Elsevier España, S.L.U. All rights reserved.

Adult Cystic Fibrosis: A Possible Cause of Bronchiectasis in COPD Patients[☆]



Fibrosis quística del adulto, una causa de bronquiectasias a considerar en el paciente con EPOC

To the Editor,

Cystic fibrosis (CF) is an autosomal recessive genetic disease caused by an alteration in the cystic fibrosis transmembrane conductance regulator (CFTR) gene.¹ This alteration determines abnormal ion transport, primarily in the epithelial cells of the gastrointestinal tract and respiratory system.² Early neonatal screening detection using immunoreactive trypsin testing has shown benefits in the long term, and for this reason, the disease is usually diagnosed in children. However, recent studies indicate a prevalence of CF diagnosis in adults of up to 10%.^{3,4} The diagnosis is established in the presence of clinical criteria or a family history of CF and the demonstration of abnormal CFTR function from the result of a sweat test or the presence of 2 mutations causing the disease.⁴

We report the case of a 52-year-old man, former smoker of 35 pack-years, with a family history of respiratory disease, mother with asthma, and father with pulmonary emphysema, and no other significant history. He was admitted to the intensive care unit with hypercapnic encephalopathy with no clear triggering factor, and required intubation and invasive mechanical ventilation. He had a history prior to admission of several years of habitual cough and expectoration, and Medical Research Council (MRC) grade 1–2 dyspnea that had worsened in recent months. On discharge he was referred to the respiratory medicine department for an extended study, which found MRC grade 2 dyspnea with no other relevant findings. Lung function tests were requested, according to the 2002 SEPAR guidelines, which revealed a forced vital capacity (FVC) of 2150 cc (51.7%), a forced expiratory volume in 1 second (FEV₁) of 650 cc (19.4%), FEV₁/FVC ratio of 30.5%, diffusing capacity of the lung for carbon monoxide corrected by the alveolar volume (KCO) of 56%, and 6-minute walking test distance of 576 m (98.5% predicted)

but with desaturation of 76%. Arterial blood gas showed chronic global respiratory failure, as follows: pH 7.41, partial pressure of carbon dioxide (PaCO₂) 52 mmHg, partial pressure of oxygen (PaO₂) 52 mmHg, and oxygen saturation (SaO₂) 86%, so home non-invasive mechanical ventilation continued. A chest computed tomography (CT) was also requested, and showed centrilobular emphysematous involvement of the pulmonary parenchyma, areas of bronchiectasis mainly in the upper fields and the perihilar and basal regions, with cystic formations (cystic bronchiectasis) and pseudonodular areas in the lingula and lower lobes associated with mucoid impaction (Fig. 1). Given these findings, the patient was diagnosed with chronic obstructive pulmonary disease (COPD), chronic respiratory failure, and bronchiectasis pending classification. Several additional tests were requested to determine the etiology of the bronchiectasis (immunodeficiencies, alpha-1 antitrypsin, Mantoux, etc.).⁵ Of interest was a positive sweat test of 84 mEq chloride per liter, which was followed up with a genetic study. The patient was not a carrier of any of the 52 mutations that were studied, although complete sequencing of the gene was not performed. Accordingly, we diagnosed our patient with adult CF.

Bronchiectasis is the third leading cause of chronic obstructive respiratory disease in adult patients. As it is not a disease in itself but rather the consequence of other processes, it is of great importance to establish its etiology in order to choose the most appropriate treatment.⁵ Despite the fact that the prevalence of bronchiectasis is approximately 50% in moderate-severe COPD,⁶ it should not be assumed to be a direct result of COPD, and a differential diagnosis with other associated disorders should be performed.

There are approximately 70 000 individuals with CF worldwide.⁷ In recent decades, notable improvements in medical management, particularly with regard to pulmonary involvement, have led to an increase in life expectancy in these patients,^{8–10} and now 40%–50% of CF patients are adults.³

Most patients present the classic CF symptoms in childhood, and diagnosis is made in the first year of life.¹¹ Patients who are diagnosed in adulthood often have one of the so-called “mild” mutations and have retained some chloride channel activity.¹ These patients have what is known as non-classic CF, and often present fewer symptoms with the involvement of fewer organs or systems.

In spite of advances in the treatment of CF, respiratory manifestations continue to dominate the characteristic symptoms of CF patients, as was the case with our patient, and respiratory problems account for 95% of the morbidity and mortality of

[☆] Please cite this article as: Benito Bernáldez C, Almadana Pacheco V, Valido Morales AS, Rodríguez Martín PJ. Fibrosis quística del adulto, una causa de bronquiectasias a considerar en el paciente con EPOC. *Arch Bronconeumol.* 2019;55:163–164.