

## Hepatopulmonary Syndrome and Diffuse Interstitial Lung Disease: An Unusual Combination\*



### Síndrome hepatopulmonar y enfermedad pulmonar intersticial difusa: una asociación poco conocida

Dear Editor,

Hepatopulmonary syndrome (HPS) is characterized by a triad of impaired in arterial oxygenation caused by intrapulmonary vascular dilatations (IPVD) in the setting of advanced liver disease.<sup>1</sup> The most common respiratory symptom is progressive dyspnea.<sup>2,3</sup> Platypnea-orthodeoxia (increased dyspnea and reduced oxygen saturation in an orthostatic position) can occur in up to 25% of patients.<sup>1</sup> Other signs suggestive of HPS are telangiectasia, nail clubbing, and peripheral cyanosis.<sup>4</sup> Echocardiography with agitated saline contrast is the method most widely used for detecting and confirming IPVD.<sup>1,3</sup> Liver transplantation (LT) is the current treatment of choice, since medical options have not demonstrated effectiveness.<sup>5</sup> HPS has been reported to coexist with other respiratory diseases that worsen gas exchange in up to 30% of cases.<sup>6</sup> However, the association with diffuse interstitial pulmonary disease (ILD) has been rarely reported in the literature. HPS in a patient with ILD complicates the diagnostic process and may limit the treatment options for both entities.<sup>7–10</sup> On the basis of these premises, we reviewed 3 cases of HPS coexisting with ILD, in order to describe the characteristics of clinical presentation and course (Table 1, Fig. 1).

**Case 1.** A 71-year-old woman with no history of smoking or alcohol use, diagnosed with idiopathic pulmonary fibrosis, confirmed by biopsy consistent with usual interstitial pneumonia in 2011. Increased liver enzymes were detected in a routine laboratory test, and the patient was referred to the gastroenterology department. A liver biopsy delivered a diagnosis of non-alcoholic steatohepatitis. Three months after this diagnosis, the patient's dyspnea, hypoxemia, and carbon monoxide diffusion worsened. High-resolution computed tomography (HRCT) showed no progression in her fibrosis score and no decline was observed in forced vital capacity. After confirmation of the presence of HPS, the patient presented progressive clinical deterioration and died after 4 months.

**Case 2.** A 70-year-old man with a history of chronic alcohol use, diagnosed with alcoholic cirrhosis at the age of 65 years, admitted to the gastroenterology department due to upper gastrointestinal bleeding. He reported a 3-month history of dyspnea on medium exertion. Chest X-ray showed radiological signs of ILD. HRCT showed a pattern of non-specific interstitial pneumonia (NSIP). Given his respiratory failure, he was prescribed home oxygen therapy on discharge and completed follow-up as an outpatient. Autoimmunity and specific immunoglobulin G for avian antigens and fungi were negative. Lung biopsy could not be performed due to worsening of the patient's clinical situation and blood gases, and he was readmitted the following month. HPS was confirmed during this admission, and the patient's progress was poor, requiring high oxygen flows. He died 19 days later.

**Case 3.** A 70-year-old former smoker with no history of alcoholism, with suspected non-alcoholic steatohepatitis followed up in another hospital. He reported a 20-month history of dyspnea on minimal exertion, and a 2-year history of morning arthralgia in the hands and ankles. He also had a history of ischemic heart disease for which cardiological examinations had been performed, none of

**Table 1**

Clinical, functional, and radiological description of patients included in the series.

Case	1	2	3
Age	71	70	70
Sex (M/F)	F	M	M
Smoking history	Never smoker	Former smoker	Former smoker
Pack-years	N/A	40	30
Etiology of liver disease	NASH	Alcoholic cirrhosis	NASH
Child–Pugh score	B	C	A
mMRC dyspnea	3	3	3
Nail clubbing	Yes	No	No
Telangiectasias	Yes	Yes	Yes
Platypnea/orthodeoxia	Yes	Yes	Yes
Velcro crackles	Yes	Yes	Yes
FVC (% pred)	93	30	ND
TLC (% pred)	86	ND	ND
DLCO (% pred)	51	ND	ND
PaO <sub>2</sub> (mmHg)	50	52	49
Oxygen saturation (%)	83	87	81
PA-aO <sub>2</sub> (mmHg)	61	54	63
HRCT pattern	UIP	NSIP	NSIP
Pathology	UIP	N/A	Interstitial fibrosis/diffuse alveolar damage
Survival since HPS diagnosis (days)	125	19	14
Bronchoalveolar lavage			
Macrophages	76%	82%	
Lymphocytes	13%	5%	ND
Segmented	11%	13%	
Eosinophils	0	0	
Cause of death	Respiratory failure	Respiratory failure	ILD exacerbation

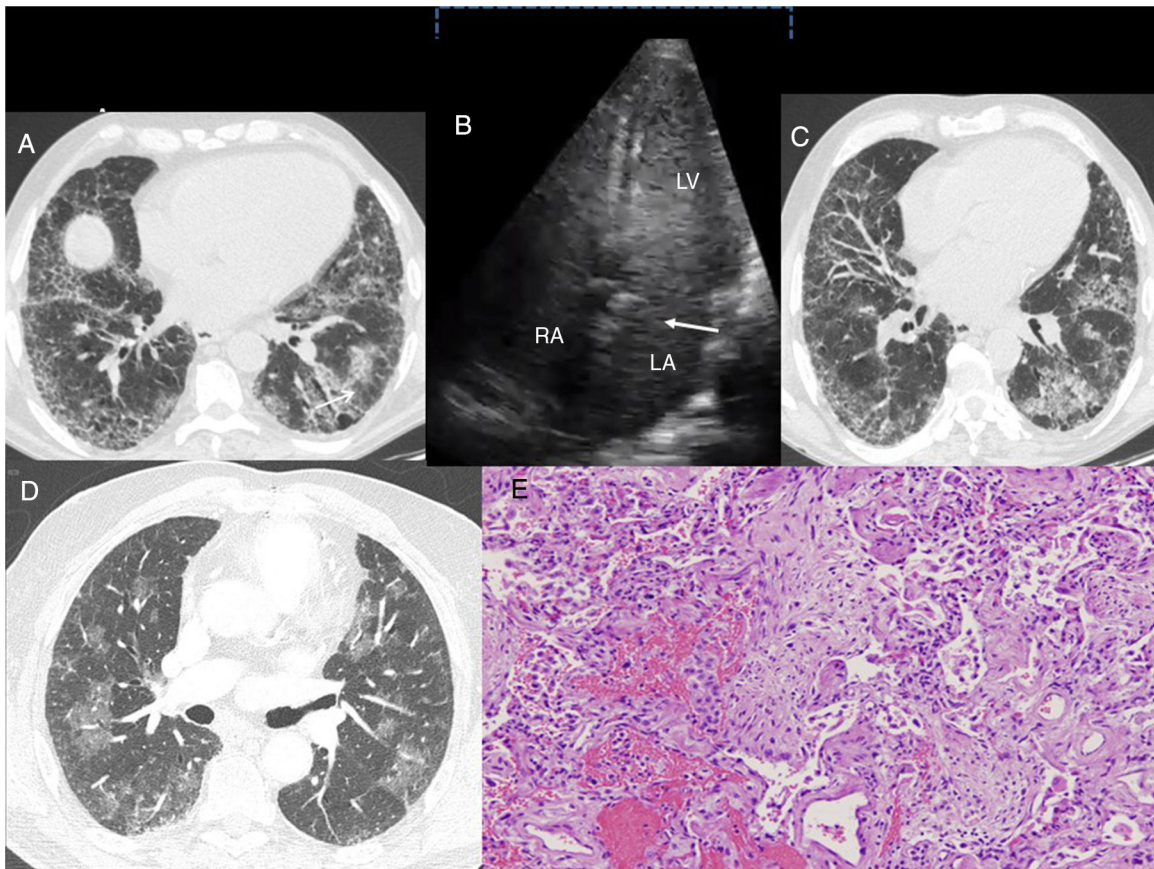
Oxygenation changes as a diagnostic criterion of HPS were defined on the basis of the difference in basal alveolar and arterial oxygen (PA-aO<sub>2</sub>) ( $\geq 15$  mmHg in individuals under the age of 64 years and  $\geq 20$  mmHg in patients older than 64 years).<sup>1</sup>

DLCO: alveolar diffusion of carbon monoxide; F: female; FVC: forced vital capacity; HRCT: high-resolution computed tomography; M: male; mMRC: *modified Medical Research Council*; N/A: Not applicable; NASH: non-alcoholic steatohepatitis; ND: not done; PaO<sub>2</sub>: blood pressure of oxygen; TLC: total lung capacity.

which showed any changes. He was admitted to the emergency department for worsening dyspnea and acute respiratory failure. A chest X-ray performed 11 months before admission showed a bilateral interstitial pattern. HRCT was performed, revealing a pattern suggestive of NSIP. Clinical laboratory tests were positive for antinuclear antibodies (1/320), anti-citrullinated cyclic peptide antibodies (46 U/ml), and rheumatoid factor (46 IU/ml). Symptoms progressed steadily, with severe hypoxemia requiring admission to the intermediate respiratory care unit, where echocardiogram was performed, confirming HPS. The patient died after 14 days, and the autopsy reported the presence of acute alveolar damage and cirrhosis of the liver.

These cases illustrate 3 different clinical scenarios in which the coexistence of HPS and ILD prompt several observations. Firstly, HPS can be a cause of disproportionate hypoxemia in ILD patients. In this setting, a greater reduction in carbon monoxide diffusion than expected might indicate an associated vascular problem or the presence of emphysema. As a result, this parameter may be less sensitive for evaluating ILD progress or response to specific treatment. Secondly, the presence of HPS can limit the diagnostic process of ILD, due to the risk involved in performing a lung biopsy in these patients. Moreover, if the patient has a previous diagnosis of idiopathic pulmonary fibrosis (as in our first case), the available antifibrotic treatments would be contraindicated due to severe liver disease. Finally, ILD can worsen the prognosis of HPS, by limiting the access of these patients to LT. Risk of death in HPS patients is double that of patients with cirrhosis without HPS.<sup>1</sup> For this reason, prompt inclusion in an LT program after diagnosis is

\* Please cite this article as: Rodríguez-Pons L, Prats M, Guasch-Arriaga I, Portillo K. Síndrome hepatopulmonar y enfermedad pulmonar intersticial difusa: una asociación poco conocida. Arch Bronconeumol. 2018;54:582–584.



**Figure 1.** (A) Case 1: chest HRCT axial slice (lung window), showing reticular interstitial involvement, with septal thickening and ground-glass opacities in the lung bases and traction bronchiectasis (arrow). (B) Case 1: Echocardiogram with agitated saline contrast showing the late passage of bubbles to the left atrium after 3–6 beats (arrow). RA: right atrium; LA: left atrium; LV: left ventricle. (C) Case 2: chest HRCT axial slice (lung window), showing subpleural reticulation with apex-base gradient, accompanied by distortion of the lung architecture and traction bronchiectasis. Areas of ground glass opacities with septal thickening are also observed. (D) Case 3: Chest HRCT axial slice (lung window) showing bilateral, patchy pulmonary ground glass opacities. E. Case 3. Histological image showing foci of bleeding with little reactive change in the alveolar epithelium. Inflammation and pneumocytic hyperplasia are also seen alternating with areas of lax fibrosis replacing the pulmonary parenchyma. These findings are compatible with acute alveolar damage (hematoxylin-eosin stain, 100 $\times$ ).

recommended.<sup>1,4</sup> Five-year survival after LT lies around 76%,<sup>2,11</sup> while in patients who are not candidates for this procedure, mean survival is 24 months.<sup>2</sup> The main causes of death in HPS are derived from the complications of the liver disease itself.<sup>6</sup> As a result, the coexistence of the ILD may have resulted in the lower survival observed in our series compared to previous reports.

The pathogenesis of this association is unknown. However, fibrosing lung diseases and cirrhosis are characterized by the presence of epithelial/endothelial damage with abnormal scarring that leads to fibroproliferation and tissue remodeling,<sup>10</sup> involving several common inflammatory cytokines and growth factors (TNF- $\alpha$ , IL-1, TGF- $\beta$  and VEGF).<sup>2,6,10</sup> A recent study pointed to telomere shortening as one of the possible mechanisms involved.<sup>12</sup>

In conclusion, the coexistence of HPS and ILD raises a number of difficulties in the diagnostic and therapeutic approach of both entities, and affects progress. Further studies are needed to explore the particularities of this association in order to be able to create strategies to improve prognosis.

#### Acknowledgement

The authors thank Dr J. L. Mate-Sanz for sharing and analyzing the histological images.

#### References

- Krowka MJ, Fallon MB, Kawut SK, Fuhrmann V, Heimbach JK, Ramsay MA, et al. International liver transplant society practice guidelines: diagnosis and management of hepatopulmonary syndrome and portopulmonary hypertension. *Transplantation*. 2016;100:1440–52.
- Martínez-Palli G, Rodríguez-Roisin R. Hepatopulmonary syndrome: a liver-induced oxygenation defect. *Eur Respir Mon*. 2011;54:246–64.
- Rodríguez-Roisin R, Krowka MJ. Hepatopulmonary syndrome: a liver-induced lung vascular disorder. *N Engl J Med*. 2008;358:2378–87.
- Zagolín M, Medel JN, Valera J. Síndrome hepatopulmonar e hipertensión portopulmonar: dos entidades a diferenciar. *Rev Chil Enf Respir*. 2008;24:291–303.
- Krowka MJ. The liver-lung vascular connection. *BRN Rev*. 2017;3:204–19.
- Rodríguez-Roisin R, Bartolome SD, Huchon G, Krowka MJ. Inflammatory bowel diseases, chronic liver diseases and the lung. *Eur Respir J*. 2016;47:638–50.
- Martínez G, Barbera J, Navasa M, Roca J, Visa J, Rodríguez-Roisin R. Hepatopulmonary syndrome associated with cardiorespiratory disease. *J Hepatol*. 1999;30:882–9.
- Tercé G, Stervino-Weméau L, Leroy S, Hachulla-Lemaire AL, Wallaert B. Hepatopulmonary syndrome and diffuse interstitial lung disease. *Respir*. 2010;27:1114–8.
- Gupta S, Castel H, Rao RV, Picard M, Lilly L, Faughnan ME, et al. Improved survival after liver transplantation in patients with hepatopulmonary syndrome. *Am J Transpl*. 2010;10:354–63.
- Shahangian S, Shino MY, Barjaktarevic I, Susanto I, Belperio JA, Fishbein MC, et al. Interstitial lung disease in patients with hepatopulmonary syndrome: a case series and new observations. *Lung*. 2014;192:421–7.
- Swanson KL, Wiesner RH, Krowka MJ. Natural history of hepatopulmonary syndrome: impact of liver transplantation. *Hepatology*. 2005;41:1122–9.

12. Gorgy AI, Jonassaint NL, Stanley SE, Koteish A, DeZern AE, Walter JE, et al. Hepatopulmonary syndrome is a frequent cause of dyspnea in the short telomere disorders. *Chest*. 2015;148:1019–26.

Laura Rodríguez-Pons,<sup>a</sup> Marisol Prats,<sup>a,b</sup> Ignasi Guasch-Arriaga,<sup>b,c</sup> Karina Portillo<sup>a,b,d,\*</sup>

<sup>a</sup> *Servei de Pneumologia, Hospital Universitari Germans Trias i Pujol, Badalona, Barcelona, Spain*

<sup>b</sup> *Departament de Medicina, Universitat Autònoma de Barcelona, Barcelona, Spain*

<sup>c</sup> *Servei de Radiodiagnòstic, Hospital Universitari Germans Trias i Pujol, Badalona, Barcelona, Spain*

<sup>d</sup> *Barcelona Research Network (BRN), Barcelona, Spain*

\* Corresponding author.

E-mail address: [karisoe@yahoo.es](mailto:karisoe@yahoo.es) (K. Portillo).

1579-2129/

© 2018 SEPAR. Published by Elsevier España, S.L.U. All rights reserved.

## Interstitial Pulmonary Edema and Acetazolamide in High-Performance Sport: A Case Report<sup>☆</sup>



### *Edema pulmonar intersticial en el deporte de alta competición y acetazolamida: a propósito de un caso*

Dear Editor,

Interstitial pulmonary edema is a functional lung disorder that limits diffusing capacity. It causes changes in the alveolocapillary barrier,<sup>1,2</sup> and has been described in athletes who perform long-duration, high-intensity activities, particularly divers,<sup>3</sup> all types of swimmers,<sup>4</sup> and mountaineers.<sup>5</sup> It is also very well characterized in race horses.<sup>6</sup> Its prevalence in sport is unknown, although it is in all likelihood underestimated, and it is now called “swimming-induced pulmonary edema” (SIPE)<sup>4</sup> because of its association with various water sports. The condition is caused by overload of the pulmonary capillary bed due to exercise that demands high cardiac output, by the need to redistribute that volume due to the temperature of the water, by the position of the chest, and sometimes by unnecessary overhydration.<sup>7</sup> It is also reasonable to suppose that the presence of certain inflammatory processes that modify lung tissue permeability<sup>8</sup> coupled with overtraining might facilitate the development of pulmonary edema in these athletes.

We report the case of an Olympic-class swimmer, 21 years of age, with mild intermittent asthma in childhood for which she now only occasionally requires preventive treatment for exercise-induced asthma. She presented with incongruous symptoms, despite correct treatment for her asthma. The patient complained of a marked sensation of dyspnea that was “different” from her usual asthma, with progressive onset, associated with the intensity of exercise, causing clear limitation at a moderate swimming speed. The syndrome also involved greater peripheral upper limb fatigue than would usually correspond to the type of effort made, which would resolve after a brief rest, only to reappear when the same type of effort was made. Previous clinical history and physical examination were normal, with no symptoms suggestive of respiratory tract infection, and no exposure to environmental pollutants or allergens. Forced spirometry was performed, showing lower values than expected in a swimmer<sup>9</sup> and an obstructive pattern with a positive bronchodilator (initial test in [Table 1](#)). Standard core treatment began with a combination of budesonide/formoterol 320/9 µg in dry powder, twice a day, administered in a schedule adjusted to her training sessions, i.e., first dose before the morning session and second dose before the evening session. After 3 months of treat-

ment, the swimmer’s symptoms and performance limitation were somewhat less intense, but continued to affect her training sessions. Spirometry before and after the training session at that time showed some bronchoconstriction on exertion (test B in [Table 1](#)). Auscultation after the session only revealed heavy, intense breathing with an elongated expiration; pulse oximetry showed values between 95% and 98%. Given the suspicion of a possible overload of the vascular bed due to interstitial pulmonary edema and the difficulty of evaluating and monitoring changes in DLCO, a post-exertion pulmonary parenchyma ultrasound was performed, in which the B-lines (comet tail signs) typical of pulmonary edema were observed.<sup>10</sup> proBNP levels were evaluated before and after exertion, showing values of 8.3 and 8.5 pg/ml, respectively, considered normal. Believing that this could be a case of exercise-limiting pulmonary edema, we requested permission from the Spanish Anti-doping Agency to use a short, 1-week course of a carbonic anhydrase,<sup>11</sup> acetazolamide, for preventive and diagnostic purposes: the presence of diuretics in a urine sample in a doping test is considered an adverse result under section S5, as this substance might be used to improve performance or change an outcome (e.g., losing weight to change category), or to mask the use of other prohibited substances.<sup>12</sup> During the waiting period, the swimmer discontinued preventive treatment; her symptoms remained the same and greater bronchoconstriction was seen on spirometry. Acetazolamide 250 mg p.o. was administered in a single morning dose for 1 week, as planned, with no combined preventive treatment. As can be seen in test C of [Table 1](#), on completion of this period, post-exertion spirometric values even showed bronchodilation in the post-training procedure, with a total absence of signs or symptoms of respiratory distress and a normal post-exercise ultrasound.

Based on the available information, and in the absence of a DLCO determination that would be decisive, we can validate the presence of exercise-induced mild interstitial edema in this swimmer, that resolved with the administration of acetazolamide. This case is an illustration of the usefulness of spirometry as a simple, practical tool to support the clinical history in this serious disorder, especially in the practice of open-water swimming<sup>13</sup>; it also highlights the need to decide if a patient is a candidate for a medication that is considered a positive doping agent, and thus requires a request for therapeutic authorization. We know that lung diffusion improves with training,<sup>14</sup> and that it is one of factors that can determine differences in sports performance.<sup>15,16</sup> Each case must be studied separately to determine if SIPE is a specific adaptation problem caused by associated physiopathological factors rather than inflammatory processes, or if it is a response to definitive functional limitation in some individuals. A therapeutic intervention must never be targeted solely at sports performance. In this respect, the sports authorities should be cautious in deciding whether to permit an athlete to use a substance, depending on whether its use is considered to be a preventive measure for a pathological response or a measure for overcoming a limitation to exertion. This

<sup>☆</sup> Please cite this article as: Drobnic F, García-Alday I, Banquells M, Bellver M. Edema pulmonar intersticial en el deporte de alta competición y acetazolamida: a propósito de un caso. *Arch Bronconeumol*. 2018;54:584–585.