

Javier Miguel Martín Guerra,* Miguel Martín Asenjo,
Luis Ángel Sánchez Muñoz, Carlos Jesús Dueñas Gutiérrez

* Corresponding author.

E-mail address: javi6vega@hotmail.com (J.M. Martín Guerra).

Servicio de Medicina Interna, Hospital Clínico Universitario de
Valladolid, Valladolid, Spain

1579-2129/

© 2018 Published by Elsevier España, S.L.U. on behalf of SEPAR.

Response to Omalizumab in a Patient With Chronic Eosinophilic Pneumonia and Poor Response to Corticosteroids[☆]



Respuesta a omalizumab en paciente con neumonía eosinófila crónica y mala respuesta al tratamiento con corticoides

To the Editor,

We report the case of a 55-year-old woman, former smoker since September 2012 (18 pack-years), with a history of allergic rhinoconjunctivitis and bronchial asthma. No infiltrates were observed in a chest X-ray performed in 2012. Skin prick tests showed sensitization to cat dander and grass and olive pollen.

She was admitted in 2014 for an acute episode of dyspnea, breath sounds, and non-productive cough without fever. Chest X-ray revealed an alveolointerstitial pattern predominantly in the lung bases. Chest computed tomography showed bilateral patchy ground glass infiltrates. Bronchoscopy was performed with trans-bronchial biopsy and bronchoalveolar lavage: neutrophils: 11%; eosinophils: 85.9%; lymphocytes: 0.6%. Biopsy showed a histological pattern of pulmonary eosinophilia suggestive of chronic eosinophilic pneumonia (CEP), with a focal pattern typical of organizing pneumonia. Lung function tests highlighted a restrictive pattern with carbon monoxide diffusion changes: FVC 1830 – 59%; FEV₁ 1410 – 54% and FEV₁/FVC 77%. DLCO 32%; KCO 63%; TLC 61%; and RV 86%. All immunological tests were negative; IgE 493 UI/ml. In the 6-min walk test, initial saturation was 97%, distance walked 440 m, and final saturation 85%.

CEP was diagnosed, with no known occupational or environmental risks, although a relationship with the administration of anti-inflammatories (celecoxib) could not be ruled out. This drug was discontinued, and treatment began with corticosteroids, resulting in both clinical and radiological worsening.

Given the poor response to treatment with corticosteroids, a surgical biopsy was performed, and the pathology study reported squamous-like interstitial pneumonia with eosinophils, consistent with CEP. The patient was placed on the lung transplantation waiting list. Lung function tests prior to the introduction of omalizumab

were: FVC 1430 – 47%; FEV₁ 1120 – 43%; FEV₁/FVC 78%; DLCO 24%; KCO 55%; TLC 44%; RV 81%.

In a review of the literature, 2 cases^{1,2} of CEP with a favorable response to omalizumab were identified, so treatment began with this drug, producing clinical improvement and functional stabilization, so we decided to gradually withdraw the corticosteroids. Twenty-four months after starting omalizumab, the patient has shown a remarkable improvement in her symptoms without corticosteroids, confirming the reversal of her previous functional decline noted from the introduction of this drug (Fig. 1). The patient was taken off the lung transplantation waiting list when the adverse effects of steroid treatment had resolved. When mepolizumab came on the market, this therapeutic option was proposed to the patient, but she refused it in view of her good progress.

CEP is an idiopathic disease characterized by an abnormal accumulation of eosinophils in the interstitial and alveolar space. Standard treatment is systemic corticosteroids. Response is usually so rapid and favorable, that if no response is observed, alternative diagnoses must be considered.

Our patient presented a poor response to high-dose corticosteroids, so a surgical biopsy was performed, which confirmed the initial diagnosis. We identified 2 cases of CEP with response to omalizumab in the literature^{1,2} involving patients with elevated IgE and poor response to corticosteroids (or a requirement for high doses). In both cases, treatment with omalizumab reversed deterioration, and produced improvements in lung function tests.

Omalizumab is a humanized anti-IgE antibody, usually indicated for the treatment of persistent allergic asthma. Numerous effects that go far beyond IgE immunomodulation have also been described.^{3–11} Omalizumab reduces basophil Fc epsilon RI alpha receptor expression.^{3–5} It also induces a decrease in triptase, Th2 cytokines (IL-4 and IL-13), and chemokines (IL-8 and RANTES), irrespective of IgE levels. Similarly, it reduces cytokine expression (IL-5, IL-10, and IL-13) in dendritic cells,^{6,7} and interferes with their ability to activate CD4. It also reduces eosinophil numbers^{8,9} in both sputum and lung tissue, monocytes,⁹ fraction of expired nitric oxide (FENO),^{9,10} and endothelin-1 concentrations in exhaled breath condensate.¹⁰ Moreover, stimulation of IgE increases the deposit of collagen I, III, and IV, and fibronectin by the Erk1/2 MAPK

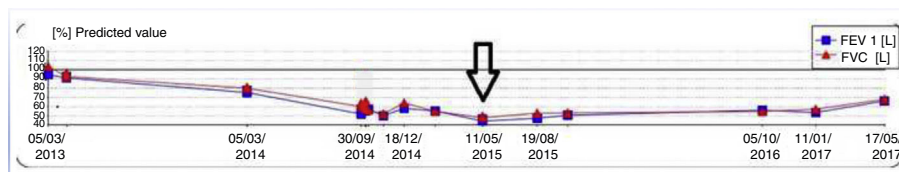


Fig. 1. Functional progress of our patient. The arrow indicates the time of starting omalizumab.

[☆] Please cite this article as: Laviña-Soriano E, Ampuero-López A, Izquierdo-Alonso JL. Respuesta a omalizumab en paciente con neumonía eosinófila crónica y mala respuesta al tratamiento con corticoides. Arch Bronconeumol. 2018;54:393–394.

pathway, thereby increasing airway remodeling. By blocking this action, muscle proliferation and the deposit of pro-inflammatory substances can be reduced.¹¹

Our patient's progress not only demonstrates the favorable effect of omalizumab, but also suggests that it is more than just an IgE immunomodulator, and that its effects on eosinophilic inflammation are also important. These findings are supported by the results of basic research, and have been confirmed by reports of favorable responses, such as in our patient, in other conditions such as Churg-Strauss disease or chronic rhinosinusitis, in which eosinophilic inflammation is a key component.¹²

References

1. Kaya H, Gümüüş S, Uçar E, Aydoğan M, Muşabak U, Tzkoparan E, et al. Omalizumab as a steroid-sparing agent in chronic eosinophilic pneumonia. *Chest*. 2012;142:513-6.
2. Domingo C, Pomares X. Can Omalizumab be effective in chronic eosinophilic pneumonia? *Chest*. 2013;143:274.
3. Beck LA, Marcotte GV, MacGlashan D, Toglas A, Saini S. Omalizumab-induced reductions in mast cell FcεpsilonR1 expression and function. *J Allergy Clin Immunol*. 2004;114:527-30.
4. Lin H, Boesel KM, Griffith DT, Prussin C, Foster B, Romero FA, et al. Omalizumab rapidly decreases nasal allergic response and FcεpsilonR1 on basophils. *J Allergy Clin Immunol*. 2004;113:297-302.
5. Oliver JM, Tarleton CA, Gilmartin L, Archibeque T, Qualls CR, Diehl L, et al. Reduced FcεpsilonR1-mediated release of asthma-promoting cytokines and chemokines from human basophils during omalizumab therapy. *Int Arch Allergy Immunol*. 2010;151:275-84.
6. Schroeder JT, Bieneman AP, Chichester KL, Hamilton RG, Xiao H, Saini SS, et al. Decreases in human dendritic cell-dependent T(H)2-like responses after acute in vivo IgE neutralization. *J Allergy Clin Immunol*. 2010;125:896.e6-901.e6.
7. Chand HS, Schuyler M, Joste N, Hensler C, Tesfaigzi, Masten B, et al. Anti-IgE therapy results in decreased myeloid dendritic cells in asthmatic airways. *J Allergy Clin Immunol*. 2010;125:1157-1158.e5.
8. Djukanovic R, Wilson SJ, Kraft M, Jarjour NN, Steel M, Chung KF, et al. Effects of treatment with anti-immunoglobulin E antibody omalizumab on airway inflammation in allergic asthma. *Am J Respir Crit Care Med*. 2004;170:583-93.
9. Takaku Y, Soma T, Nishihara F, Nakagome K, Kobayashi T, Hagiwara K, et al. Omalizumab attenuates airway inflammation and interleukin-5 production by mononuclear cells in patients with severe allergic asthma. *Int Arch Allergy Immunol*. 2013;161 Suppl. 2:S107-17.
10. Zietkowski Z, Skiepkó R, Tomasiak-Lozowska MM, Bodzenta-Lukaszyk A. Anti-IgE therapy with omalizumab decreases endothelin-1 in exhaled breath condensate of patients with severe persistent allergic asthma. *Respiration*. 2010;80:534-42.
11. Roth M, Zhong J, Zumkeller C, Sığ CT, Goulet S, Tamm M. The role of IgE-receptors in IgE-dependent airway smooth muscle cell remodelling. *PLOS ONE*. 2013;8:e56015.
12. Sattler C, García G, Humbert M. Novel targets of omalizumab in asthma. *Curr Opin Pulm Med*. 2017;23:56-61.

Eduardo Laviña-Soriano,* Ana Ampuero-López,
José Luis Izquierdo-Alonso

Servicio de Neumología, Hospital Universitario de Guadalajara,
Guadalajara, Spain

* Corresponding author.

E-mail address: jizquierdo@sescam.org (E. Laviña-Soriano).

1579-2129/

© 2017 SEPAR. Published by Elsevier España, S.L.U. All rights reserved.

A 60-Year-Old Male Smoker With Chronic Obstructive Pulmonary Disease and Hypereosinophilia*



Varón de 60 años de edad con enfermedad pulmonar obstructiva crónica y eosinofilia

To the Editor,

In clinical practice, a diagnosis of pulmonary eosinophilia is suspected in patients with respiratory symptoms (dyspnea, cough or wheezing), migratory pulmonary infiltrates on chest X-ray, and eosinophilia in peripheral blood, or preferably, in the lung.^{1,2} Hypereosinophilic syndrome (HES) is a rare entity with different forms, one of the most exceptional of which is myeloproliferative HES. We report a case of FIP1L1/PDGFRα-positive myeloproliferative HES diagnosed in a patient with pulmonary eosinophilia.

A 60-year-old man, smoker of 50 pack-years, attended the respiratory medicine clinic with a 2-month history of worsening of his habitual cough and expectoration, and no other symptoms. He had been diagnosed 2 years previously with grade II COPD (forced expiratory volume in 1 s [FEV₁] 79%), well managed after giving up smoking and receiving treatment with fluticasone/salmeterol 25/250 mcg.

No lymphadenopathies were observed on physical examination, and auscultation revealed some rhonchi, and a respiratory rate of 16 breaths/min and heart rate of 90 beats/min. No other significant findings were noted.

Blood tests showed leukocytosis 12 590 cells/mm with eosinophils 8560 (61%). Other blood counts, coagulation, and biochemistry results were normal. Lung function tests: FEV₁ 2610 l (87%), forced vital capacity (FVC) 4090 l (109%), FEV₁/FVC 63.78%. Bronchodilator test and methacholine challenge were negative. Chest X-ray showed radiological signs of COPD. Chest and abdomen CT showed centriacinar and paraseptal emphysema, micronodules in the upper lung lobes, middle lobe and lingula, and thickening of the bladder, with suspected malignancy (Fig. 1). Echocardiogram was normal. Given these findings, the patient was referred to the urology department, where he was diagnosed with transitional cell carcinoma, and treated accordingly. The high number of eosinophils in blood prompted us to undertake a detailed differential diagnosis. Tests for parasites, helminths (*Ascaris lumbricoides*, *Taenia solium*, hydatidosis, *Toxocara canis*, *Leishmania*) and fungi, and stool culture were all negative. Hepatitis A, B and C and human immunodeficiency virus serologies, and *Mycobacterium* and *Bordetella* testing were also negative. In view of these findings, fiberoptic bronchoscopy was performed, and bronchial aspirate, bronchoalveolar lavage (BAL), and transbronchial biopsy (TBB) were obtained. Bronchial aspirate was negative for malignant cells. The BAL cell count was: lymphocytes 6%, polymorphonuclear cells 69%, and eosinophils 20%. Pathology study of TBB reported bronchial mucosa and pulmonary parenchyma with eosinophil infiltration, confirming pulmonary eosinophilia. The immunological study, including antinuclear antibodies, anti-neutrophil cytoplasmic antibodies, and rheumatoid factor, was also negative.

The hematology department was consulted, in view of the patient's persistently high blood and pulmonary eosinophil levels (11.330/μl and 20%, respectively). A bone marrow biopsy was performed which showed marked eosinophilia with predominantly mature cells. Flow cytometry revealed a predominance of CD3. A

* Please cite this article as: Sánchez-Jareño M, Yuste Jiménez V, Villasante C, Canales MÁ, Álvarez-Sala R. Varón de 60 años de edad con enfermedad pulmonar obstructiva crónica y eosinofilia. *Arch Bronconeumol*. 2018;54:394-395.