

Clinical image

Tracheobronchopathia Osteochondroplastica. A Chance Finding<sup>☆</sup>



Traqueobroncopatía osteocondroplásica, un hallazgo casual

Luis Alfonso Sota Yoldi,<sup>a,\*</sup> Roberto Fernández Mellado,<sup>b</sup> Laura Vigil Vigil<sup>c</sup>

<sup>a</sup> Servicio de Neumología, Fundación Hospital de Jove, Gijón, Asturias, Spain

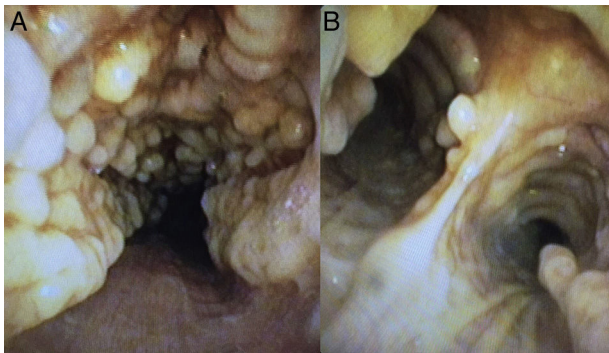
<sup>b</sup> Servicio de Neumología, Hospital El Bierzo, Ponferrada, León, Spain

<sup>c</sup> Servicio de Neumología, Hospital Universitario de Cabueñes, Gijón, Asturias, Spain

We report the case of a 78-year-old woman with an incidental finding of a pulmonary nodule measuring 18 mm in the right upper lobe in a chest computed tomography study performed to determine possible myasthenia gravis. The patient had no respiratory symptoms. A bronchoscopy was performed, revealing significant

irregular nodular involvement of the anterolateral wall of the trachea and main bronchi, with a stony consistency, not impinging on the pars membranosa in any way (Fig. 1). Given these characteristic findings, tracheobronchopathia osteochondroplastica was diagnosed.

Tracheobronchopathia osteochondroplastica is a rare benign disease of unknown etiology that affects the trachea and, to a lesser extent, the main bronchi. It is caused by the formation of cartilaginous or bony submucous nodules that project into the lumen of the airway, with no involvement of the posterior wall.<sup>2</sup> Visualization of these lesions on bronchoscopy is sufficient to confirm diagnosis, without the need for a histology study.<sup>1,2</sup> However, biopsies are performed if bone or calcification of the submucosa is seen. The disease course is benign and slow, and complications are unusual.



**Fig. 1.** Bronchoscopy image of the trachea (A) and the main carina (B), showing irregular cartilaginous protrusions in the lumen, with no involvement of the pars membranosa.

**References**

1. Devaraja K, Sagar P, Chirom AS. Tracheobronchopathia osteochondroplastica: awareness is the key for diagnosis and management. *BMJ Case Rep.* 2017. <http://dx.doi.org/10.1136/bcr-2017-220567>.
2. Barros Casas D, Fernández-Bussy S, Folch E, Flandes Aldeyturriaga J, Majid A. Non-malignant central airway obstruction. *Arch Bronconeumol.* 2014;50:345–54.

<sup>☆</sup> Please cite this article as: Sota Yoldi LA, Fernández Mellado R, Vigil Vigil L. Traqueobroncopatía osteocondroplásica, un hallazgo casual. *Arch Bronconeumol.* 2018;54:280.

\* Corresponding author.

E-mail address: [lsotayol@hotmail.com](mailto:lsotayol@hotmail.com) (L.A. Sota Yoldi).