

Clinical Image

The Utility of Dual-Energy Computed Tomography in the Diagnosis of Pulmonary Thromboembolism Caused by Post-Vertebroplasty Cement: A Case Report[☆]



Utilidad de la tomografía computarizada con doble energía, en el diagnóstico del tromboembolismo pulmonar por cemento posvertebroplastia: a propósito de un caso

Carlos Pérez-Serrano, Ivan Vollmer,* Rosario J. Perea

Servicio de Radiodiagnóstico, Centro de Diagnóstico por la Imagen Clínic (CDIC), Hospital Clínic, Barcelona, Spain

We report the case of a 73-year-old woman who had suffered a fall 2 months previously, sustaining a vertebral fracture in T11–T12 requiring vertebroplasty. Fifteen days later, she fell again, requiring thoracolumbar arthrodesis from T9 to L2. Nine days later, she developed sudden onset dyspnea with severe respiratory failure,

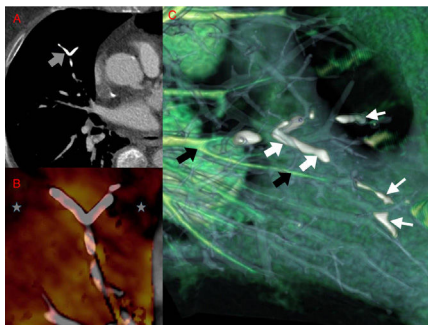


Fig. 1. Dual-energy computed tomography after the administration of intravenous iodinated contrast medium. (A) Axial image revealing a high-density branched linear image in a subsegmentary artery in the medial segment of the middle lobe (gray arrow) suggestive of cement embolism. (B) Iodine perfusion map revealing areas of hypoperfusion (gray stars) distal to the dense linear lesion described previously. (C) Vascular map showing vessels containing iodine colored green (black arrows) and filling defects attributable to the cement in white (thick white arrows). Note how this kind of reconstruction can be used to identify a greater number of small caliber vessel defects (thin white arrows).

so an emergency CT pulmonary angiogram was performed, given suspected pulmonary thromboembolism (PTE).

The CT pulmonary angiogram showed high-density images in the subsegmentary pulmonary branches (Fig. 1A) and in the azygos vein (adjacent to the treated vertebrae). Perfusion reconstructions with iodine and vascular mapping were used to differentiate areas of hypoperfusion (Fig. 1B) and cement embolism from endovascular iodine (Fig. 1C).

The incidence of pulmonary embolism caused by cement after vertebroplasty ranges from 2.1% to 26%.^{1,2} It generally occurs with minimal respiratory symptoms that may develop during the procedure, or more commonly, days, weeks or even months later.²

Treatment is usually limited to respiratory observation and anti-coagulation with low molecular weight heparin, since the presence of intravascular cement can activate the coagulation pathways.^{1,2} Surgical treatment with endovascular embolectomy may also be considered in some cases.¹

References

1. Wang LJ, Yang HL, Shi YX, Jiang WM, Chen L. Pulmonary cement embolism associated with percutaneous vertebroplasty or kyphoplasty: a systematic review. *Orthop Surg.* 2012;4:182–9.
2. Rothermich MA, Buchowski JM, Bumpass DB, Patterson GA. Pulmonary cement embolization after vertebroplasty requiring pulmonary wedge resection. *Clin Orthop Relat Res.* 2014;472:1652–7.

[☆] Please cite this article as: Pérez-Serrano C, Vollmer I, Perea RJ. Utilidad de la tomografía computarizada con doble energía, en el diagnóstico del tromboembolismo pulmonar por cemento posvertebroplastia: a propósito de un caso. *Arch Bronconeumol.* 2018;54:155.

* Corresponding author.

E-mail address: vollmer@clinic.ub.es (I. Vollmer).