

Clinical Image

Endobronchial Actinomycosis Associated With an Inorganic Foreign Body[☆]



Actinomicosis sobre cuerpo extraño inorgánico endobronquial

Cristina Benito Bernáldez,* Estefanía Luque Crespo, Virginia Almadana Pacheco

Servicio de Neumología, Hospital Universitario Virgen Macarena, Sevilla, Spain

We report the case of a 79-year-old man with a history of laryngeal cancer who underwent total laryngectomy in 2010 with tracheotomy and subsequent placement of a voice prosthesis in 2012. He attended the emergency room for chest pain and dyspnea. CT-angiogram of the chest revealed incomplete obliteration of the left principal bronchus (LPB), and an image of a metallic foreign body in the interior of the airway was identified, along with distal alveolar infiltrate in the left lung base (Fig. 1).

Fiberoptic bronchoscopy showed a foreign body (voice prosthesis) occupying the LPB surrounded by a significant granulomatous reaction, which could be extracted with biopsy forceps (Fig. 1).

Histopathological examination of the bronchial biopsy revealed a nonspecific inflammatory process with presence of foreign material and abundant colonies of actinomyces.

Endobronchial actinomycosis is very rare and has occasionally been described in association with the aspiration of a foreign body.¹ In our case, the foreign body was inorganic – only 3 cases of this association have been reported in the literature.² The patient reported that he had aspirated the voice prosthesis over 24 months previously, without symptoms. The patient did not require antibiotic treatment after the foreign body had been completely extracted by bronchoscopy.²

References

1. Maki K, Shinagawa N, Nasuhara Y, Oizumi S, Domen H, Haga H, et al. Endobronchial actinomycosis associated with a foreign body – successful short-term treatment with antibiotics. *Inter Med.* 2010;49:1293–6.
2. Singh S, Singh S, Jyotimallika J. Endobronchial actinomycosis associated with nonorganic foreign body aspiration after years of latency. *J Bronchol Intervent Pulmonol.* 2015;22:180–2.

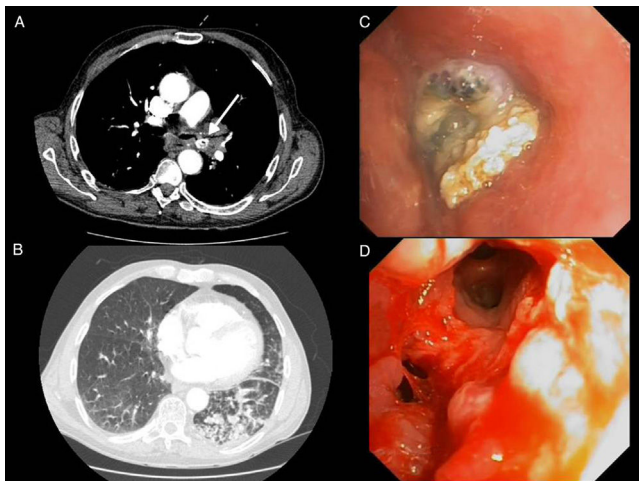


Fig. 1. Chest CT-angiogram showing foreign body in left principal bronchus (A) and distal alveolar infiltrate in the left lung base (B). Bronchoscopic images showing foreign body occupying left principal bronchus, surrounded by significant granulomatous reaction (C), and image after extraction of the foreign body, with a completely clear bronchial lumen (D).

[☆] Please cite this article as: Benito Bernáldez C, Luque Crespo E, Almadana Pacheco V. Actinomicosis sobre cuerpo extraño inorgánico endobronquial. *Arch Bronconeumol.* 2017;53:689.

* Corresponding author.

E-mail address: cristina.be.be@hotmail.com (C. Benito Bernáldez).