

Clinical Image

Thoracic Aortic Aneurysm Rupture: What Lies Beneath[☆]



Rotura de aneurisma de aorta torácica: lo que la verdad esconde

Marta Nataya Solís Marquínez,^{a,*} Juan Francisco López Caleyá,^a Laura Martín Rodrigo^b

^a Servicio de Medicina Interna, Hospital Universitario de Cabueñes, Gijón, Asturias, Spain

^b Servicio de Medicina Interna, Fundación-Hospital de Jove, Gijón, Asturias, Spain

We report the case of a 69-year-old man with a vascular stent for thoracoabdominal aortic aneurysm who consulted due to syncope followed by reduced level of consciousness. He was hemodynamically stable, with good distal perfusion and mild desaturation with tachypnea. Head computed tomography (CT) ruled out bleeding and chest X-ray (Fig. 1A) revealed increased density in the right lung base. Clinical laboratory tests showed leukocytosis with left shift and elevated acute phase reactants. He was diagnosed with bacterial pneumonia and treatment began with levofloxacin. A few hours later, antigenuria results positive for *Streptococcus pneumoniae* were received. Laboratory results worsened, and in view of suspected sepsis with multiple organ failure, antibiotic therapy was extended. The patient subsequently presented sudden respiratory

decline, absence of left radial and pedal pulses, and cardiac arrest. Resuscitation maneuvers and blood transfusion were performed due to suspected bleeding from a ruptured aneurysm. Chest radiograph (Fig. 1B) revealed opacities in the right hemithorax, and the CT angiogram of the aorta (Fig. 1C, D) identified an aneurysmal endoleak with active bleeding into the pleural space with massive right hemithorax. No surgical alternatives could be offered, and the patient subsequently died.

This is a case in which hemodynamic stability without anemia and radiological and microbiological findings were consistent with bacterial pneumonia, concealing the final diagnosis of endoprosthetic leak.

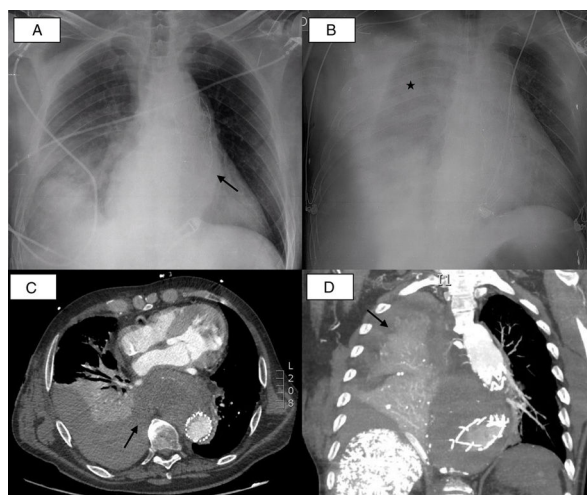


Fig. 1. (A) Anteroposterior chest X-ray at admission: cardiomegaly, aortic elongation with stent (arrow) and area of increased density in the right thoracic base probably related to infectious disease. (B) Anteroposterior chest X-ray after clinical worsening: significant pleural effusion with opacities in the right hemithorax (asterisk). (C) Chest CT in axial plane. (D) Chest CT in sagittal plane: endoleak can be seen in the descending thoracic aorta with extravasation in the form of active bleeding into the right pleural cavity causing significant hemothorax (arrows), collapsing the entire right lower lobe and the posterior segment of the upper lobe (aortopleural fistula).

[☆] Please cite this article as: Solís Marquínez MN, López Caleyá JF, Martín Rodrigo L. Rotura de aneurisma de aorta torácica: lo que la verdad esconde. Arch Bronconeumol. 2017;53:583.

* Corresponding author.

E-mail address: natayasolis@gmail.com (M.N. Solís Marquínez).