

Clinical Image

Massive Retrosternal Goitre With Critical Tracheal Narrowing

Bocio retroesternal masivo con estrechamiento traqueal crítico

Marta Sousa*, Manuela Fernandes, Bárbara Rodrigues

Centro Hospitalar Tondela-Viseu, Viseu, Portugal

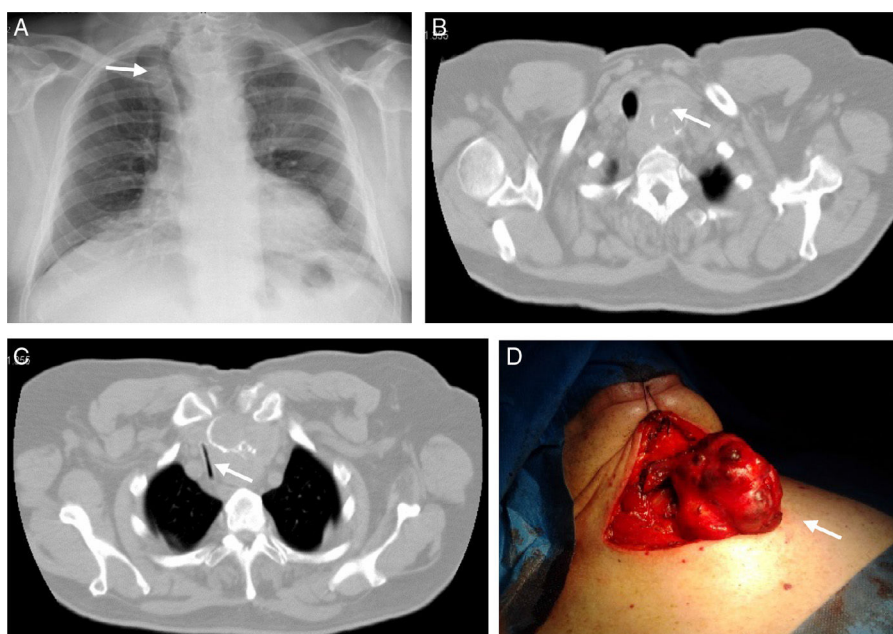


Fig. 1. (A) Chest radiograph revealing an enlargement of the superior mediastinum with right deviation of the trachea, (B) Chest computed tomography scan showing a multinodular diving goitre, with compression and critical narrowing of the trachea (C). (D) Total thyroidectomy – resected goitre.

A 75 year-old man was referred to pulmonology for persistent episodes of dyspnoea, productive cough and wheezing lasting 5 years. He was treated with mucolytics, bronchodilators and corticosteroids, with no significant clinical improvement. On physical examination, bilateral wheezing with prolonged expiration were noted on pulmonary auscultation. A chest radiograph revealed an enlargement of the superior mediastinum with right deviation of the trachea (Fig. 1, Panel A, arrow). A chest computed tomography scan showed a multinodular diving goitre (Panel B, arrow), with compression and critical narrowing of tracheal lumen (Panel C, arrow). The patient underwent total thyroidectomy

(Panel D, arrow). After surgery, complete resolution of respiratory symptoms was observed, with no tracheal sequelae. This case highlights the importance of including extrinsic airway compression in the differential diagnosis of persistent episodes of wheezing, as described in the literature.¹ It is also interesting to note that respiratory symptoms usually resolve after surgery, and there is less risk of post-thyroidectomy tracheomalacia than previously thought.²

References

1. Mokoka MC, Ullah K, Curran DR, O'Connor TM. Rare causes of persistent wheeze that mimic poorly controlled asthma. *BMJ Case Rep.* 2013;2013.
2. Findlay JM, Sadler GP, Bridge H, Mihai R. Post-thyroidectomy tracheomalacia: minimal risk despite significant tracheal compression. *Br J Anaesth.* 2011;106:903–6.

* Corresponding author.

E-mail address: martadias.sousa@gmail.com (M. Sousa).