

Obstructive Fibrinous Tracheal Pseudomembrane Following Silicone Stent Insertion[☆]



Seudomembrana traqueal fibrinosa obstructiva tras la inserción de una endoprótesis de silicona

To the Editor,

Obstructive fibrinous tracheal pseudomembrane (OFTP) is believed to be a complication of tracheal intubation. Here, we describe a unique case of OFTP after silicone stent insertion. In this case, an hourglass-shaped stent was inserted to mitigate airway obstruction in a patient diagnosed with post-intubation tracheal stenosis. Although silicone stents are considered safe, they are associated with numerous complications. To our knowledge, pseudomembrane formation after silicone stent insertion has never been reported.

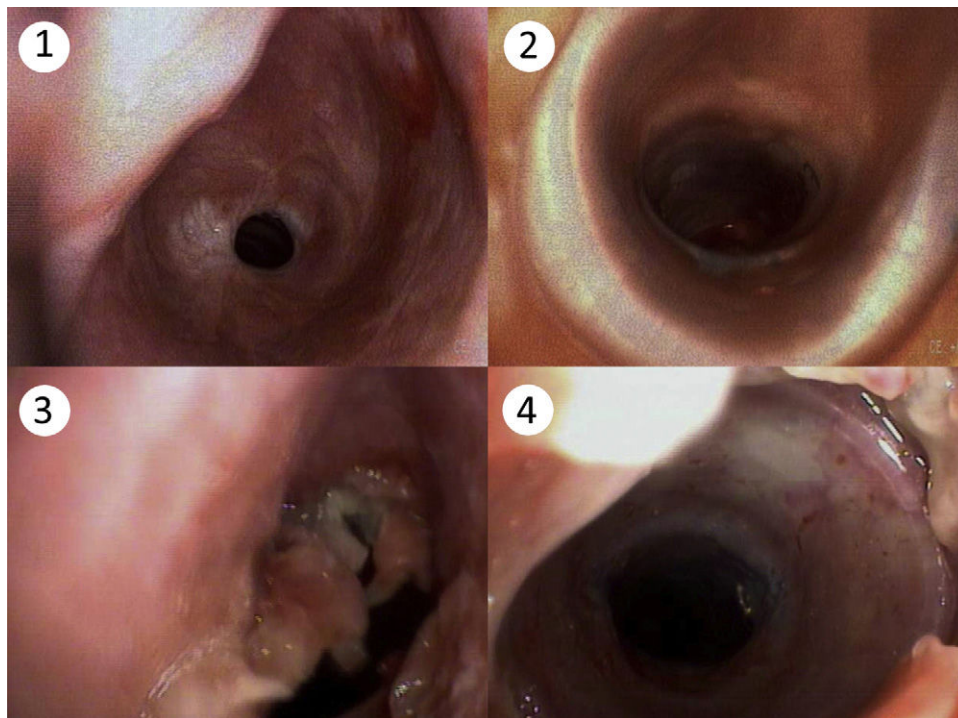
A 48-year-old man, a former smoker (about 30 pack-years), was admitted to our hospital with a 3-month history of progressive dyspnea, stridor, and cough. He had a medical history of intubation and mechanical ventilation 6 months previously due to drug intoxication. He had no relevant family history. On physical examination, the patient presented tachypnea and central cyanosis. The arterial blood gas analysis showed hypoxia (pH=7.42, PaO₂=57 mmHg, PaCO₂=31 mmHg, HCO₃⁻=20 mmol/l, room air). The complete blood count revealed leukocytosis of 10.75×10⁹/L (normal range: 4.0–10.0×10⁹/L). A diagnosis of post-intubation tracheal stenosis was considered first, and chest computed tomography was performed while the patient was receiving oxygen therapy. A marked circumferential stenosis of the trachea was

found, with no signs of extrinsic mass. Fiber optic bronchoscopy was performed immediately to assess the airway stenosis, showing a subglottic stenosis of the trachea (Fig. 1.1). In order to reduce the dyspnea, an hourglass-shaped silicone stent (DumonTMSilicone stent) was inserted by means of rigid bronchoscopy, after which the bronchoscopy showed a widely patent airway (Fig. 1.2) and dyspnea improved significantly.

Two days later, dyspnea returned, and fiberoptic bronchoscopy was performed twice, finding a thick, valve-like membrane above the stent (Figs. 1.3 and 1.4). The membrane was removed under bronchoscopy with the help of grasping forceps, after which the patient's dyspnea completely resolved. The histopathological examination of the membrane showed fibrin, necrotic epithelium cells, and exudate, with no evidence of bacteria, fungi or mycobacterium.

Upper airway obstruction, which can be either malignant or benign, is a complicated clinical problem. The former is caused by primary or secondary lung cancer, while the latter is often caused by tracheal intubation, tracheostomy, and other medical treatments. The aim of therapy is to alleviate symptoms in order to prolong survival and improve quality of life. The silicone stent was first used in the management of airway stenosis in the 1990s,¹ and has been associated with complications such as worsening cough, stent obstruction with secretion, migration, or granulation.²

It is rare to find an OFTP after silicone stent insertion; most cases have hitherto been reported after tracheal intubation. The OFTP patient often complains of dyspnea, hoarseness or stridor that may occur immediately after extubation or a few hours later, and in severe cases may lead to respiratory failure. Flexible or rigid bronchoscopy is essential for the diagnosis and treatment of OFTP.



Figs. 1.1–1.4. (1) Subglottic tracheal stenosis. (2) Patent's trachea after silicone stent insertion. (3) Valve-like pseudomembrane. (4) Membrane and the silicone stent.

[☆] Please cite this article as: Han X-P, Liu D-J, Liu Y-L, Liu J-B. Seudomembrana traqueal fibrinosa obstructiva tras la inserción de una endoprótesis de silicona. Arch Bronconeumol. 2017;53:529–530.

The etiopathogenesis of OFTP remains unclear, and multiple hypotheses have been proposed. Sehgal and colleagues retrospectively analyzed a series of 54 cases, and found most pseudomembranes to be located in the subglottic region, the narrowest part, where the mucosa is most sensitive during intubation. However, not all cases are located below the glottis.³ Deslee and colleagues suggest cuff-induced ischemic damage as a possible cause, although his theory does not explain cases in which high-volume low-pressure tubes were used.⁴ In 2013, Alvarez-Maldonado and colleagues reported a case of pseudomembrane formation following percutaneous dilatational tracheostomy (PDT).⁵ In our case, OFTP occurred after silicone stent insertion. Both cases show that various factors may be related to OFTP, including mechanical stimulus and local aseptic inflammation. To sum up, OFTP is an uncommon complication after silicone stent insertion, and can be fatal if not diagnosed promptly. Bronchoscopy is essential in the management of OFTP.

References

1. Dumon JF. A dedicated tracheobronchial stent. *Chest*. 1990;97:328-32.
2. Mitsuoka M, Sakuragi T, Itoh T. Clinical benefits and complications of Dumon stent insertion for the treatment of severe central airway stenosis or airway fistula. *Gen Thorac Cardiovasc Surg*. 2007;55:275-80.

3. Sehgal IS, Dhooria S, Bal A, Aggarwal AN, Behera D, Agarwal R. Obstructive fibrous tracheal pseudomembrane after endotracheal intubation. *Respir Care*. 2016;61:1260-6.
4. Deslee G, Brichet A, Lebuffe G, Copin MC, Ramon P, Marquette CH. Obstructive fibrinous tracheal pseudomembrane. A potentially fatal complication of tracheal intubation. *Am J Respir Crit Care Med*. 2000;162:1169-71.
5. Alvarez-Maldonado P, Cicero-Sabido R, Navarro-Reynoso F, Nuñez-Pérez-Redondo C. Tracheal ring fracture and pseudomembrane formation after percutaneous dilatational tracheostomy. *J Bronchol Interv Pulmonol*. 2013;20:285-6.

Xiao-Peng Han, Dai-Jian Liu, Ying-Li Liu, Jian-Bo Liu*

Department of Respiratory Medicine, the Second Affiliated Hospital of Zhengzhou University, Henan, People's Republic of China

* Corresponding author.

E-mail address: jbliuzz@163.com (J.-B. Liu).

1579-2129/

© 2016 SEPAR. Published by Elsevier España, S.L.U. All rights reserved.

Is COPD Control a Useful Concept? Assessing Treatment Success by Evaluating COPD-Related Health Status*



¿Es útil el concepto de control de la EPOC?: evaluación del éxito terapéutico a partir de la valoración del estado de salud en relación con la EPOC

To the Editor,

In most chronic diseases, treatment decisions are usually based on whether control has been achieved in a given patient. This concept can have some clinical utility in COPD. However, there is currently no definition of well-controlled disease, and no objective criteria to define control in COPD or any objective tools to measure it.¹ In fact, it is still unclear how to evaluate response to treatment in COPD.²

In asthma, control is an important concept, because severity is assessed retrospectively from the level of treatment required to control the disease.³ However, in asthma, the concept of control is easily confused with the concept of severity, as they represent overlapping dimensions.⁴ This is not the case in COPD, and GOLD 2016, unlike previous versions, recommends using the Clinical COPD Questionnaire^{5,6} in addition to CAT and/or mMRC as a tool for evaluating symptoms and assessing COPD health status, not as a direct measure of COPD control.⁷

Patients with COPD seek health care mostly due to exertional dyspnoea and limitation of physical activity: breathlessness is the most common symptom limiting exercise capacity, and exercise intolerance or decreased physical activity are present from the beginning of the disease.⁸ The degree of physical activity is the best predictor of all-cause mortality,⁹ and COPD can be understood as an exercise intolerance disease that can impact

daily activities. From the patient's point of view, there should be several therapeutic successes in COPD, given the different perceptions of dyspnoea, variability in physical activity and general well-being.

COPD is characterised by persistent airway limitation that is usually progressive and not fully reversible. The term COPD brings together a number of entities with different clinical and pathophysiological features, and the treatment goals are symptomatic improvement, prevention of exacerbations and disease progression. The high mortality associated with COPD is mainly due to exacerbations requiring hospitalisation. Acute exacerbations also contribute to worsening of pulmonary function, change the trajectory of the disease, and contribute to impairment of health-related quality of life. Indeed, control will always be a difficult concept to define in COPD. However, based on the definition of the disease and the goals of treatment, there are probably two main domains in COPD control: a functional domain, focussed on FEV1, and a clinical domain, focussed on exacerbations.

Nevertheless, the therapeutic definition of success should not only be based on control as a biomedical concept, but rather on a multidimensional dimension, a general COPD-related health status, that should incorporate the patient's perspective, considering also the "quality of life" dimension.

As control of symptoms is insufficient to control the disease and its progression, the patient has a limited capacity to define therapeutic success in order to participate in clinical decision-making: control is thus a limiting biomedical concept. To define therapeutic success, therefore, we also need to take in account the idea of patient well-being.

COPD is a chronic and incurable disease, and although it is unlikely that most patients will remain asymptomatic, their symptoms improve with continuous bronchodilator use. The best possible improvement in symptoms and lung function, and the absence of exacerbations, seems to be more similar to the notion of controlled disease, but it is certainly part of therapeutic success. The idea of therapeutic success is useful, because it is linked to the concept of value.¹⁰ Value in medicine must be defined in terms of the patient: it is the patient's health outcomes that matter. In

* Please cite this article as: Araújo AD, Hespanhol V, Correia-de-Sousa J. ¿Es útil el concepto de control de la EPOC?: evaluación del éxito terapéutico a partir de la valoración del estado de salud en relación con la EPOC. *Arch Bronconeumol*. 2017;53:530-531.