

Clinical Image

Pulmonary artery stump thrombus in a patient with right pneumonectomy complicated by bronchopleural fistula[☆]



Trombosis del muñón de la arteria pulmonar en paciente con neumonectomía derecha complicada con fístula broncopleurales

Luis Gorospe Sarasúa,^{a,*} Ana Paz Valdebenito-Montecino,^b Gemma María Muñoz-Molina^b

^a Servicio de Radiodiagnóstico, Hospital Universitario Ramón y Cajal, Madrid, Spain

^b Servicio de Cirugía Torácica, Hospital Universitario Ramón y Cajal, Madrid, Spain

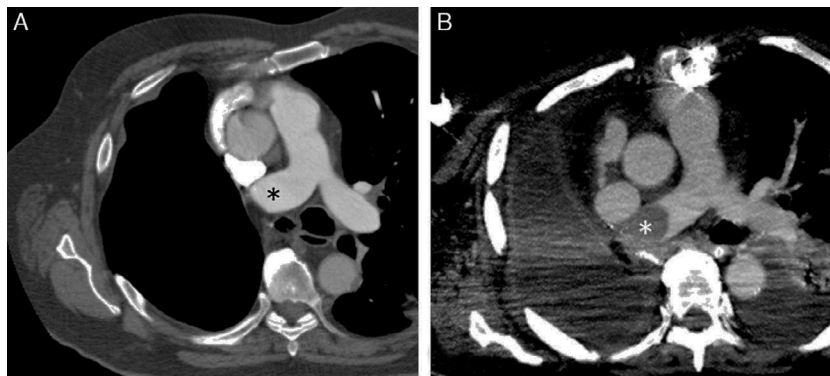


Fig. 1. (A) Axial image of chest computed tomography, 6 months after pneumonectomy, showing thrombus on main pulmonary artery stump (asterisk) with no internal filling defects. (B) Axial image of chest computed tomography, 8 weeks after bronchopleural fistula repair, showing a new convex filling defect (asterisk) in the stump of the right main pulmonary artery.

A 71-year-old man with a history of lung cancer treated by right pneumonectomy developed a bronchopleural fistula 3 months after surgery. The fistula was treated with antibiotics and chest tube drainage, while 2 attempts to seal it endoscopically with fibrin derivatives failed. Finally, we decided to close the fistula surgically with a pericardial fat pad via median sternotomy. None of the subsequent chest computed tomography studies showed evidence of thrombi on the stump of the right main pulmonary artery (Fig. 1A). However, 8 weeks after fistula repair, the patient was admitted with severe sepsis of respiratory origin, and a repeat CT revealed the appearance of a convex thrombus on the stump of the right main pulmonary artery, left pleural effusion, and opacities

apparently of infectious origin in the left lung (Fig. 1B). The patient died some days later due to multiorgan failure.

Pulmonary artery stump thrombus occurs in 12% of patients undergoing pneumonectomy, and the need for anticoagulation is a subject of debate.¹ Our case is interesting because the complication appeared at a deferred stage, after a second surgical intervention to repair a bronchopleural fistula.

Reference

1. Kim SY, Seo JB, Chae EJ, Do KH, Lee JS, Song JW, et al. Filling defect in a pulmonary arterial stump on CT after pneumonectomy: radiologic and clinical significance. *Am J Roentgenol.* 2005;185:985–8.

[☆] Please cite this article as: Gorospe Sarasúa L, Valdebenito-Montecino AP, Muñoz-Molina GM. Trombosis del muñón de la arteria pulmonar en paciente con neumonectomía derecha complicada con fístula broncopleurales. *Arch Bronconeumol.* 2017;53:71.

* Corresponding author.

E-mail address: luisgorospe@yahoo.com (L. Gorospe Sarasúa).