

Clinical Image

Pulmonary Embolism due to Metal Coil Migration After Treatment of Pelvic Varices[☆]



Embolismo pulmonar por migración de *coil* metálico tras tratamiento de varices pélvicas

Rossella D'Amato,^{*} Juan Marco Figueira Gonçalves, Juan Manuel Palmero Tejera

Servicio de Neumología, Hospital Universitario Nuestra Señora de la Candelaria, Santa Cruz de Tenerife, Spain

We report the case of a 49-year-old woman, non-smoker, non-drinker, who 15 years previously had undergone embolization of pelvic varicose veins due to pelvic congestion syndrome. She was referred after the incidental finding of a nodule with a radiographic density of metal in the left hemithorax. The patient reported no respiratory symptoms. A flexible bronchoscopy was performed, ruling out a foreign body in the endobronchial region; chest and

abdominal computed tomography (CT) showed a foreign body occupying the segmental branch of the lower left lobe (LLL) (Fig. 1) consistent with a coil. Since the patient was asymptomatic, a conservative approach was taken, with clinical and radiological monitoring.

Embolization of ovarian varicose veins is a procedure used in the endovascular treatment of pelvic congestion syndrome. It is considered a safe and effective treatment, although some cases of pulmonary embolization of metal have been described.¹ Cases of migration of coil fragments have also been reported in men after embolization of the dorsal veins of the penis or the spermatic vein for the treatment of erectile dysfunction or varicocele.²

References

1. Ratnam LA, Marsh P, Holdstock JM, Harrison CS, Hussain FF, Whiteley MS, et al. Pelvic vein embolisation in the management of varicose veins. *Cardiovasc Intervent Radiol.* 2008;31:1159–64.
2. Moriel EZ, Mehringer CM, Schwartz M, Rajfer J. Pulmonary migration of coils inserted for treatment of erectile dysfunction caused by venous leakage. *J Urol.* 1993;149:1316–8.

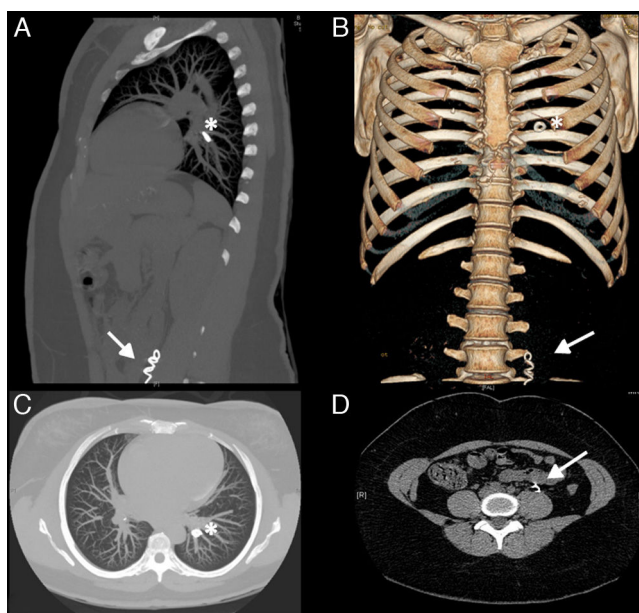


Fig. 1. Chest-abdominal computed tomography: sagittal (A), coronal (B) and axial (C and D) slices. A metal spiral-shaped foreign body seen in the interior of the left ovarian vein (arrow) and rounded embolization material in a segmental pulmonary artery of the left lower lobe (asterisk).

[☆] Please cite this article as: D'Amato R, Figueira Gonçalves JM, Palmero Tejera JM. Embolismo pulmonar por migración de *coil* metálico tras tratamiento de varices pélvicas. *Arch Bronconeumol.* 2017;53:72.

^{*} Corresponding author.

E-mail address: rossdam@hotmail.it (R. D'Amato).