

biopsy obtained, showing necrotizing non-caseifying epithelioid granulomas. Final diagnosis of pulmonary sarcoidosis stage II with secondary PE.

Discussion

The prevalence of PE in published series of sarcoidosis patients is rare, at between 1% and 2%,³ although some groups have reported rates of up to 8%–10%.^{4,5} Pleural involvement can appear at any age, but occurs mostly between the ages of 41 and 60 years, with no difference between sexes. It is usually mild-moderate, generally right-sided (48.3%), and occurs in disease stages I and II. It characteristically presents as serous exudate, although 2 distinct types have been described, depending on the etiological pathological mechanism. Lymphocytes are predominant (typically with a CD4+/CD8+ ratio between 2.61 and 8.6).² Cases described in the literature² do not state whether patients previously presented a positive PPD, as was the case with our patient, which became negative during the study of the clinical symptoms of sarcoidosis. This effect, known as “immunological paradox”,³ consists of an immune-mediated phenomenon in which, despite intense local inflammation, anergy can develop as a result of dysregulation of the T cells involved in the immunopathology of the disease.

In view of our patient's previous positive PPD and extremely high ADA in PE, active tuberculous infection had to be reliably ruled out, so we performed mycobacteria IGRA, PCR, stains and cultures for 8 weeks in pleural fluid, that were all negative. Sputum smear in bronchial aspirate and urine, and closed pleural biopsy with mycobacterial PCR, cultures and stains were also negative. In view of the high initial suspicion of TB due to the history of untreated latent TB, tuberculostatic treatment was attempted for 10 days while awaiting results, but response was unsatisfactory. The microbiological results, when obtained, were negative, so we

strongly suspected pleuropulmonary sarcoidosis in a black patient and began treatment with corticosteroids. Clinical symptoms and laboratory inflammatory parameters improved, and PE resolved, confirming the initially suspected diagnosis.

Finally, given the evidence of previous exposure to TB and current corticosteroid therapy, our patient was given chemoprophylaxis on the assumption that the PPD skin test was a false negative associated with immune system changes due to the disease itself.

References

- Mussetti A, Vignoli L, Curbelo P, Meerovich E. Sarcoidosis pulmonar. *Neumol Cir Torax*. 2006;65 Suppl. 3:S36–46.
- Rodríguez N, Rábade C, Valdés L. Derrame pleural sarcoideo. *Med Clin (Barc)*. 2014;143:502–7.
- Iannuzzi MC, Rybicki BA, Teirstein AS. Sarcoidosis. *N Engl J Med*. 2007;357:2153–65.
- Huggins JT, Doelken P, Sahn SA, King L, Judson MA. Pleural effusion in a series of 181 outpatients with sarcoidosis. *Chest*. 2006;129:1599–604.
- Ferreiro L, San José E, González-Barcala FJ, Suárez-Antelo A, Toubes ME, Valdés L. Derrame pleural y sarcoidosis: una asociación poco frecuente. *Arch Bronconeumol*. 2014;50:554–6.

María Fontecha Ortega,* Sergio Julio Rodríguez Álvarez, Jose Luis García Satué

Servicio de Medicina Interna, Hospital Universitario Getafe, Getafe, Madrid, Spain

* Corresponding author.

E-mail address: Maríafontechaortega@gmail.com

(M. Fontecha Ortega).

1579-2129/

© 2016 SEPAR. Published by Elsevier España, S.L.U. All rights reserved.

Ascaris lumbricoides Through Pleural Biopsy Needle. A Rare Case of Intrapleural Ascariasis[☆]



Observación de Ascaris lumbricoides a través de una aguja de biopsia pleural. Un caso raro de ascariasis intrapleural

Dear Editor,

Ascariasis is the most common helminthic infection. However, helminthic involvement of the pleura is very rare. We report a case

of an ascaris worm found in needle-guided pleural percutaneous aspiration.

A 60 year-old male, smoker, presented with a 1-month history of dyspnea of gradual onset and progressive course, and hemoptysis. The condition was associated with anorexia, weight loss, and abdominal discomfort. Physical examination showed splenomegaly and normal temperature, with nolympadenopathy or hepatomegaly. Respiratory examination showed dullness on percussion over the right and left lung base with decreased breath sounds. The rest of the examination was unremarkable. A chest

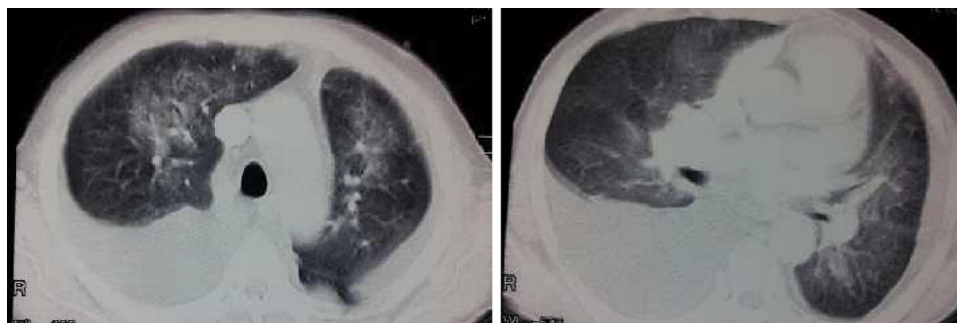


Fig. 1. Chest CT of patient at time of presentation.

[☆] Please cite this article as: Elhadidy T, Eldesoqy ME, Morsy NE, Abdelwahab HW, Tohlob M. Observación de *Ascaris lumbricoides* a través de una aguja de biopsia pleural. Un caso raro de ascariasis intrapleural. *Arch Bronconeumol*. 2017;53:171–172.



Fig. 2. Ascaris worm in pleural biopsy syringe.

radiograph showed bilateral pleural effusion and bilateral pulmonary infiltrates in both lung fields. A computed tomographic (CT) scan showed bilateral pleural effusion and bilateral consolidation involving upper lobes, middle lobe, and lingula (Fig. 1). White cell count 96 000 with 75% eosinophils. Abdominal ultrasound showed splenomegaly with simple splenic cyst. Stool examination revealed amebiasis. A repeat stool examination showed ascaris ova. Based on the clinical and laboratory findings, diagnosis was ascaris infestation. Pleural biopsy was scheduled to diagnose chest pathology. An 8 cm long, grayish white worm was seen emerging from the pleural biopsy needle during percutaneous aspiration of pleural effusion (Fig. 2). The worm was identified as *Ascaris lumbricoides*, so treatment with albendazole 400 mg for 3 days was started. Follow up CXR show marked improvement of pulmonary opacities and right sided pleural effusion with residual left pleural effusion.

Ascariasis is the most common helminthic infection, with an estimated worldwide prevalence of 25% (0.8–1.22 billion

population).¹ Ascariasis is most prevalent in children living in tropical and developing countries, where it is perpetuated by contamination of soil by human feces or use of untreated feces as fertilizer.² The adult worm resides in the gastrointestinal tract without causing any significant symptoms. However, when the environment in the intestines becomes unfavorable, such as with inflammation and obstruction, the ascaris will migrate to other less hostile environments, which can lead to serious intra-abdominal complications, such as biliary obstruction, cholangiohepatitis, liver abscess and pancreatitis.³ Two cases of pulmonary ascariasis in Austrian males have been reported. Both patients presented with dyspnea, nonproductive cough, fever, and eosinophilia (19% and 26%). One patient additionally had pulmonary infiltrates.⁴ A rare case of an ascaris worm emerging through an intercostal chest tube was reported by LONE et al., in 2010.⁵ Our case report concerns intrapleural ascariasis as a rare complication, and confirms the importance of awareness of this infestation.

References

- Bethony J, Brooker S, Albonico M, Geiger SM, Loukas A, Diemert D, et al. Soil-transmitted helminth infections: ascariasis, trichuriasis, and hookworm. *Lancet*. 2006;367:1521–32.
- Walker M, Hall A, Basáñez MG. Individual predisposition, household clustering and risk factors for human infection with *Ascaris lumbricoides*: new epidemiological insights. *PLoS Negl Trop Dis*. 2011;5:e1047.
- Markell EK, Voge M, John DT. The intestinal nematodes. In: Ozmat S, editor. *Medical parasitology*. Philadelphia: W.B. Saunders; 1992. p. 261–93.
- Surendran N, Paulose MO. Intestinal complications of round worms in children. *J Pediatr Surg*. 1988;23:931–5.
- Lone RA, Wani ML, Manzoor M, Sharma ML, Lone GN, Shah M, et al. Ascaris through a chest tube: a rare presentation. *Ulus Travma Acil Cerrahi Derg*. 2010;16:183–4.

Tamer Elhadidy, Mohammed Elsayed Eldesoqy,
Nesreen Elsayed Morsy, Heba Wagih Abdelwahab,*
Mohamed Tohlob

Chest Medicine Department, Mansoura University, Mansoura, Egypt

* Corresponding author.

E-mail address: wagihheba84@gmail.com (H.W. Abdelwahab).

1579-2129/

© 2016 SEPAR. Published by Elsevier España, S.L.U. All rights reserved.

Molecular Testing of EGFR, EGFR Resistance Mutation, ALK and ROS1 Achieved by EBUS-TBNA in Chile[☆]



Análisis moleculares de EGFR, mutación de resistencia al EGFR, ALK y ROS1 en muestras obtenidas mediante PATB-USEB en Chile

Dear Editor,

In the last 10 years, the treatment of lung cancer, especially non-small cell lung cancer (NSCLC) has changed following the development of new interventions targeting mutations detected in pathological samples of NSCLC.¹ Some of the available molecular genes include epidermal growth factor receptor (EGFR), anaplastic

lymphoma kinase (ALK), and ROS proto-oncogene 1 (ROS1), among others.²

Endobronchial ultrasound with transbronchial needle aspiration (EBUS-TBNA) is a minimally invasive technique with a high diagnostic yield, especially for central airway lesions. This technique is safe, and the European Respiratory Society (ERS), European Thoracic Society (ETS), European Society of Medical Oncology (ESMO), and American College of Chest Physician (ACCP) have suggested starting with this approach when diagnosing and staging lung cancer, especially NSCLC.^{3,4} The aim of this study is to identify the presence of 3 genetic alterations that can be targeted by specific therapeutic inhibitors, EGFR, ALK, and ROS1, collected by endobronchial ultrasound with transbronchial needle aspiration (EBUS-TBNA).

We performed a descriptive, prospective study of EBUS-TBNA samples between July 2014 and June 2015 in a reference center in Chile. Consent forms were signed by all patients and the protocol was approved by the ethics committee of our institution. The inclusion criteria were: (1) adult patients (>18 years old) with a lesion suggestive of lung cancer on clinical and radiological studies who underwent EBUS-TBNA (EBUS Olympus[®] and EBUS Fuji[®]) and (2)

[☆] Please cite this article as: Fernandez-Bussy S, Labarca G, Pires Y, Caviedes I, Burotto M. Análisis moleculares de EGFR, mutación de resistencia al EGFR, ALK y ROS1 en muestras obtenidas mediante PATB-USEB en Chile. *Arch Bronconeumol*. 2017;53:172–174.