

Organizing Pneumonia and Pulmonary Tuberculosis: Coexistent or Associated Diseases[☆]



Neumonía organizada y tuberculosis pulmonar: coexistencia o enfermedad asociada

To the Editor,

Organizing pneumonitis (OP) has been defined as secondary (SOP) if it is caused by external aggressions, such as infections, toxic substances, drugs, connective tissue diseases, or other processes, and primary, idiopathic or cryptogenic when no association with any other disease can be determined.^{1,2} The relationship between different infection types and the onset of OP is unknown.^{2,3}

We report the case of a 75-year-old patient, former smoker (25 pack-years) for 30 years, with a history of arterial hypertension, atrial fibrillation and surgery for colonic polyps, receiving treatment with acenocumarol, digoxin and valsartan.

He presented with a 2-week history of cough, sputum expectoration, dyspnea on moderate exertion, fever, joint pain and general malaise. Chest radiograph revealed pulmonary infiltrates in the right and left lower lobes, so treatment was started with cefditoren 400 mg/day and azithromycin 500 mg/day for 7 days.

The patient developed pleuritic pain in the right hemithorax due to pleural effusion and his clinical symptoms persisted, so he was admitted to hospital. Physical examination showed temperature of 38.1 °C, tachypnea and 93% oxyhemoglobin saturation while breathing ambient air (FiO₂ 21%). Pulmonary auscultation revealed rhonchi and crackles in the right lung base.

Laboratory tests on admission showed leukocytosis, 13 900 leukocytes/mm³ (80% neutrophils, 9% lymphocytes, 10% monocytes), 399 000 platelets/mm³ and ESR 111 mm/h. Of particular note among the biochemistry parameters were: ALP 133 IU/l, gamma-GT 231 IU/l and CRP 140 mg/l. Other liver tests, renal function, ions, lipids, total proteins, albumin, uric acid, thyroid hormones, procalcitonin, ACE, immunoglobulins and complement parameters were within normal limits.

Autoimmune assay was negative and no precipitins were detected in plasma for *Aspergillus* or bird proteins. Arterial blood gases on ambient air showed partial respiratory failure (pO₂ 59 mmHg) and intradermal Mantoux reaction was negative.

Chest computed tomography showed alveolar infiltrate with poorly defined borders, with the appearance of a polylobulated mass in the anterior segment of the right lower lobe and a solid nodule in the same lobe, measuring 25 mm in diameter, associated with pleural effusion. Patchy infiltrates with areas of ground glass opacity were also seen in the lingula and left lower lobe (Fig. 1).

Thoracentesis yielded 50 cm³ of yellowish serous liquid with mixed cellularity consisting of mesothelial and polymorphonuclear cells and lymphocytes. pH was 7.44, concentration of protein in pleural fluid (3.6 IU/l) and serum (6.3 g/dl), glucose 125 mg/dl and ADA 36 IU/l with no evidence of acid-alcohol resistant bacilli or other microbes. Microbiological culture of the pleural fluid, including specific media for Koch's bacillus, were negative. Bronchoscopy was performed, revealing "saber-sheath" trachea and

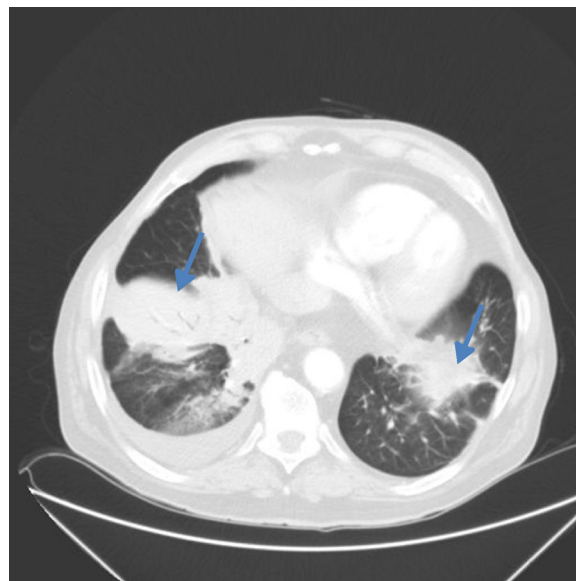


Fig. 1. Lung computed tomography showing bilateral pulmonary infiltrates (right lung base and left lower lingula) with bronchoalveolar pattern and right pleural effusion.

main bronchi with tendency to collapse, with no other significant findings.

After starting treatment with piperacillin and linezolid (for 6 days), fever resolved without radiological improvement, and the remaining symptoms persisted. Given the CT findings, a Tru-cut[®] needle biopsy was performed in the right lower lobe. The histological report was consistent with organizing pneumonia, and a non-caseifying granuloma with no AFB was also observed in the stain.

Pulmonary infiltrate and pleural effusion resolved within 3 days of starting treatment with methylprednisolone 40 mg/day. After *Mycobacterium tuberculosis* was isolated in a bronchoalveolar lavage culture, antituberculostatics were started (etambutol/isoniazid/pyrazinamide/rifampicin), while corticosteroid dosing was maintained, leading to significant clinical improvement.

Huo et al. recently associated the presence of epithelioid cell granulomas or giant multinucleated cells in organizing pneumonia resections with an infectious etiology.^{4,5} Our patient had no history of exposure that might cause hypersensitivity pneumonitis. In contrast, the presence of consolidation with air bronchogram, a nodule and patchy infiltrates with multiple areas of ground glass opacity are common findings in organizing pneumonia, and although the infectious etiology could not be ruled out, series have been published in which organizing pneumonia occurs with pleural effusion in up to 20% of patients with focal lesions.

We can conclude from this clinical case that secondary organizing pneumonia should be considered in cases of persistent infiltrates despite antibiotic treatment (including antituberculous treatment).

Acknowledgements

Our thanks to Dr M. Marigil of the Anatomical Pathology Department and Dr E. Briz of the Respiratory Medicine Department of the Hospital San Jorge, Huesca.

[☆] Please cite this article as: Sander R, Gómez C, Borderías L. Neumonía organizada y tuberculosis pulmonar: coexistencia o enfermedad asociada. Arch Bronconeumol. 2016;52:570–571.

References

1. Davison AG, Heard BE, McAllister WA, Turner Warwick ME. Cryptogenic organizing pneumonia. *Q J Med.* 1983;52:382–94.
2. Cottin V, Cordier JF. Cryptogenic organizing pneumonia. *Semin Respir Crit Care Med.* 2012;33:462–75.
3. Epler GR, Colby TV, McCloud TC, Carrington CB, Gaensler EA. Bronchiolitis obliterans organizing pneumonia. *N Engl J Med.* 1985;312:152–8.
4. Huo Z, Feng R, Tian X, Zhang H, Huo L, Liu H. Clinicopathological findings of focal organizing pneumonia: a retrospective study of 37 cases. *Int J Clin Exp Pathol.* 2015;8:511–6.
5. Zhao F, Yan SX, Wang GF, Wang J, Lu PX, Chen B, et al. CT features of focal organizing pneumonia: an analysis of consecutive histopathologically confirmed 45 cases. *Eur J Radiol.* 2014;83:73–8.

Rolf Sander,^{a,*} Carlos Gómez,^b Luis Borderías^c

^a Servicio de Geriatría, Hospital Sagrado Corazón de Jesús, Huesca, Spain

^b Servicio de Anatomía Patológica, Hospital San Jorge, Huesca, Spain

^c Servicio de Neumología, Hospital San Jorge, Huesca, Spain

* Corresponding author.

E-mail address: sanderrolf14@gmail.com (R. Sander).

Unusual Progressive Neurological Syndrome in Epidermal Growth Factor Receptor-mutated Lung Adenocarcinoma, Diagnosed at Autopsy as Invasive Meningeal Carcinomatosis[☆]



Síndrome neurológico progresivo inusual en adenocarcinoma de pulmón epidermal growth factor receptor mutado: carcinomatosis meníngea invasiva, un diagnóstico de autopsia

To the Editor,

Meningeal carcinomatosis (MC) is the most serious neurological complication in lung cancer, and is relatively common, affecting

approximately 5% of our patients, and around 20% according to some autopsy series.¹

An oncogenic epidermal growth factor receptor (EGFR) mutation has recently been associated with a greater probability of developing MC²; the exon 19 deletion (del19) in particular appears to confer a higher risk of diffuse neurological dissemination.³ However, autopsy reports of patients with oncogenic mutations are rare.

We report an unusual case of a 54-year-old woman, non-smoker, with advanced adenocarcinoma (Fig. 1) with an EGFR del19 mutation who showed good tolerance and partial radiological response after 6 months of targeted treatment with erlotinib, an oral tyrosine kinase inhibitor (TKI).

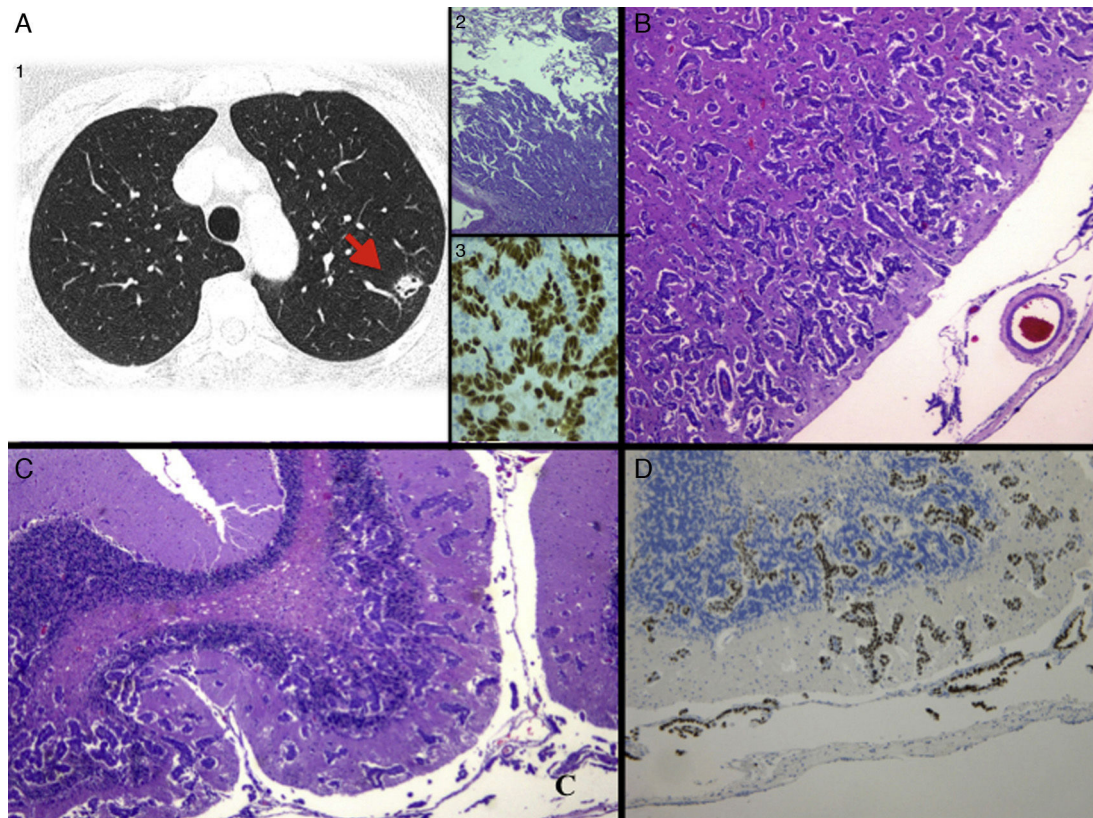


Fig. 1. (A) 1: Chest computed tomography at diagnosis, showing a nodule in the left lower lobe suggestive of primary lung tumor; 2: histological image with hematoxylin-eosin (H&E) staining of the pulmonary nodule biopsy, consistent with adenocarcinoma (4×), and 3: immunohistochemistry staining positive for thyroid transcription factor 1 (TTF-1), confirming the primary pulmonary origin. (B) Histological image with H&E staining of MC with extensive deep invasion of the frontal cortex (2.5×) and (C) cerebellum (4×). (D) Staining positive for TTF-1, confirming infiltration by adenocarcinoma of pulmonary origin.

[☆] Please cite this article as: Mezquita-Pérez L, Pian H, García N. Síndrome neurológico progresivo inusual en adenocarcinoma de pulmón epidermal growth factor receptor mutado: carcinomatosis meníngea invasiva, un diagnóstico de autopsia. *Arch Bronconeumol.* 2016;52:571–572.