

## Funding

Cardiovascular Research Network (RIC) of the Instituto de Salud Carlos III, the Spanish Pulmonary Hypertension Association, Actelion and the Fundación Air Liquide.

## References

1. Eyries M, Montani D, Girerd B, Perret C, Leroy A, Lonjou C, et al. *EIF2AK4* mutations cause pulmonary veno-occlusive disease, a recessive form of pulmonary hypertension. *Nat Genet.* 2014;46:65–9.
2. Tenorio J, Navas P, Barrios E, Fernández L, Nevado J, Quezada CA, et al. A founder *EIF2AK4* mutation causes an aggressive form of pulmonary arterial hypertension in Iberian Gypsies. *Clin Genet.* 2015;88:579–83.
3. Laparra M. Informe sobre la situación social y tendencias de cambio en la población gitana. In: *Una primera aproximación*. Ministerio de Trabajo y Asuntos Sociales; 2007.
4. Estrategia Nacional para la Inclusión Social de la población Gitana en España 2012–2020.

Paula Navas,<sup>a,b,\*</sup> Jose Julián Rodríguez Reguero,<sup>c</sup>  
Pilar Escribano Subías<sup>d</sup>

<sup>a</sup> Servicio de Cardiología, Hospital Universitario Gregorio Marañón, Madrid, Spain

<sup>b</sup> Red de investigación Cardiovascular, Instituto de Salud Carlos III, Madrid, Spain

<sup>c</sup> Servicio de Cardiología, Hospital Central de Asturias, Oviedo, Asturias, Spain

<sup>d</sup> Unidad Multidisciplinar de Hipertensión Pulmonar, Servicio de Cardiología, Hospital Universitario Doce de Octubre, Red de investigación Cardiovascular, Instituto de Salud Carlos III, Madrid, Spain

\* Corresponding author.

E-mail address: [paulanavastejedor@gmail.com](mailto:paulanavastejedor@gmail.com) (P. Navas).

## Hypersensitivity Pneumonitis as a Complication of Intravesical BCG Therapy for Bladder Cancer<sup>☆</sup>



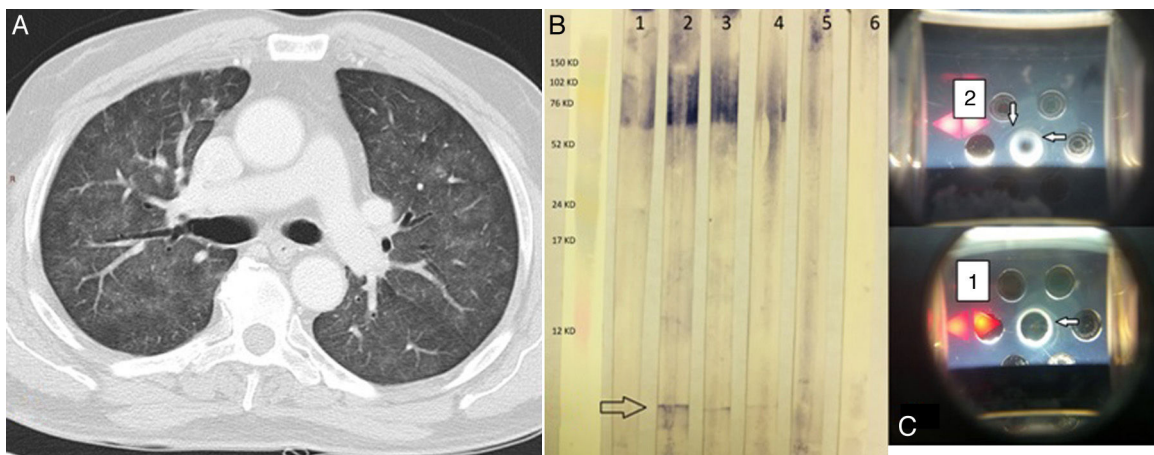
### Neumonitis por hipersensibilidad como complicación del tratamiento con BCG intravesical por carcinoma de vejiga

To the Editor,

Hypersensitivity pneumonitis (HP) or extrinsic allergic alveolitis is a pulmonary interstitial disease mainly caused by sensitization to a variety of inhaled organic particles.<sup>1</sup> The airborne antigens which most commonly lead to the development of this hypersensitivity reaction are thermophiles, molds, and avian antigens.<sup>1</sup> However, some cases caused by non-inhaled medications have also been reported, including exposure to bacillus Calmette–Guérin (BCG) in the treatment of urothelial bladder carcinoma,<sup>2</sup> such as the one we describe here.

A 73-year-old man, former smoker (accumulated consumption of 30 pack-years), arterial hypertension, with no known drug

allergies. He did not report any occupational or environmental exposure to birds, feathers or other organic substances. He had been diagnosed 3 months previously with superficial papillary urothelial carcinoma and was receiving treatment with intravesical BCG. He was admitted with a 10-day history of acute clinical symptoms, consisting of general malaise, deterioration, and fever 39 °C, coinciding with the eighth instillation of BCG. Clinical laboratory results showed leukocytes 11 900 (neutrophils 81%), C-reactive protein 87 mg/dl, and elevated liver function markers (GGT and AP). Tumor markers and angiotensin converting enzyme were normal. Cultures of sputum, urine, bronchoalveolar lavage (BAL), and blood, including Löwenstein–Jensen medium, were negative, as were pneumococcal and Legionella urinary antigen testing. Immunoglobulins (Ig) G and M were normal. Serum IgG (precipitins) for molds, birds, and feathers were negative. Chest HRCT revealed a ground glass pattern in both upper lobes, small centrilobular nodules, and consolidations in the lung bases (Fig. 1(A)). Cell distribution in BAL was: alveolar macrophages 44% and lymphocytes 56%. Flow cytometry immunophenotyping of the lymphocyte



**Fig. 1.** (A) Chest HRCT. Pulmonary parenchymal window shows a ground glass pattern and small centrilobular nodules in both lung fields. (B) Western blot. Lane 1 shows the serum of an asymptomatic individual receiving BCG; lanes 2, 3, and 4 show the index case after 3, 7, and 51 of corticosteroid therapy. Lane 5 shows the serum of an individual with a history of tuberculosis, and lane 6 is that of a healthy control. The arrow indicates a single band (specific anti-BCG antibodies). (C) Double immunodiffusion of sera 1 and 2. Arrows indicate precipitation bands.

<sup>☆</sup> Please cite this article as: Carrasco Hernández L, Castaño Núñez ÁL, Rodríguez Portal JA. Neumonitis por hipersensibilidad como complicación del tratamiento con BCG intravesical por carcinoma de vejiga. *Arch Bronconeumol.* 2016;52:445–446.

population showed: CD3+ 97.58%; CD4+ 91.88%; CD8+ 5.39%; and CD4/CD8 ratio 17. Mucosa and bronchial cartilage were retrieved by transbronchial biopsy. Spirometry was normal. Serum levels of specific anti-BCG IgG were detected using 2 different immunological techniques, double immunodiffusion (DID), and Western blot.

Treatment began with methylprednisolone 40 mg/24 h, with improvement of pulmonary lesions, and the BCG instillations were discontinued. The clinical picture did not reappear after withdrawal of the corticosteroid treatment.

BCG is an attenuated live strain of *Mycobacterium bovis* used in the intravesical treatment of superficial bladder cancer.<sup>3</sup> It is well tolerated and effective, but not completely free of side effects. HP as a rare complication of this immunotherapy has been detected in 0.7% of cases.<sup>4</sup>

For diagnosis, certain clinical, radiological, histological, and immunological criteria are needed. Clinical criteria tend to be non-specific. Chest HRCT shows a ground glass pattern, centrilobular nodules, and areas of consolidation. Lung biopsy obtained by bronchoscopy generally reveals non-caseifying granulomas, and BAL often contains >40% lymphocytes. It is very important to ensure that the patient has not developed miliary pneumonitis due to BCG, so presence of the bacillus must be ruled out using microbiological techniques.

The presence of specific antibodies against BCG is one of the major diagnostic criteria.<sup>1–5</sup> For this reason, we performed a specific anti-BCG antibody assay using DID and Western blot (Fig. 1B and C), which detected a specific band in our patient but not in the controls (a symptom-free bladder cancer patient receiving BCG and a tuberculosis patient). After the patient received steroid treatment, the intensity of the specific bands could be seen to diminish on the DID, and to a lesser extent on the Western blot, indicating a reduction in antibody concentrations.

In our case, then, in the absence of a diagnostic transbronchial biopsy, evidence of high-intensity lymphocytic alveolitis, suggestive clinical symptoms, and the presence of specific anti-BCG antibodies were key to reaching a diagnosis.

A review of PubMed between 1966 and 2013 reveals that this is first time 2 different techniques, along with a control patient receiving the same treatment, have been used to demonstrate the presence of anti-BCG antibodies possibly causative of HP.

As in any HP caused by a known agent, the main treatment is withdrawal of the causative agent and administration of oral corticosteroids.

## References

1. Navarro C, Mejía M, Gaxiola M, Mendoza F, Carrillo G, Selman M. Hypersensitivity pneumonitis: a broader perspective. *Treat Respir Med.* 2006;5:167–79.
2. Um SJ, Lee SK, Yang DK. Hypersensitivity pneumonitis following intravesical bacille Calmette-Guérin immunotherapy for superficial bladder cancer. *J Investig Allergol Clin Immunol.* 2009;19:230–2.
3. Montoya R, Izquierdo R, Pietricica B, Cano MC, Hidalgo G, Fernández T, et al. Neumonitis y hepatitis aguda tras instilación intravesical de inmunoterapia BCG. Análisis del manejo actual de las complicaciones posinstilación con BCG. *Urol Colomb.* 2011;20:51–60.
4. Tobiume M, Shinohara T, Kuno T, Mukai S, Naruse K, Hatakeyama N, et al. BCG-induced pneumonitis with lymphocytic pleurisy in the absence of elevated KL-6. *BMC Pulm Med.* 2014;14:35.
5. Cebollero P, Echechipía S, Echegoyen A, Lorente MP, Fanlo P. Hypersensitivity pneumonitis (extrinsic allergic alveolitis). *An Sist Sanit Navar.* 2005;28 Suppl. 1:S91–9 [Article in Spanish].

Laura Carrasco Hernández,<sup>a,\*</sup> Ángel Luis Castaño Núñez,<sup>b</sup>  
José Antonio Rodríguez Portal<sup>a</sup>

<sup>a</sup> Servicio de Neumología, Unidad Médico-Quirúrgica de Enfermedades Respiratorias, Hospital Universitario Virgen del Rocío, Sevilla, Spain

<sup>b</sup> Servicio de Inmunología, Hospital Universitario Virgen del Rocío, Sevilla, Spain

\* Corresponding author.

E-mail address: [lauracarrascohdez@gmail.com](mailto:lauracarrascohdez@gmail.com)

(L. Carrasco Hernández).