

hematological cancers. APL is now the most curable form of adult myeloid leukemia, with full remission persisting at 5 years and 70%–80% survival.² However DS associated with ATRA administration is probably the most toxic adverse event. The prophylactic use and length of administration of corticosteroids are controversial. Our patient received prophylactic treatment with intravenous dexamethasone, but even so, developed the syndrome. The latest PETHEMA protocol recommends prophylaxis in all patients receiving $>5 \times 10^9 \text{ l}^{-1}$ for 15 days. DS mortality is currently low (1%), due to early treatment with corticosteroids, along with the concomitant use of chemotherapy in combination with ATRA.³

DS is a clinical diagnosis based on a group of signs and symptoms in APL patients receiving induction treatment with ATRA or arsenic trioxide. Three or more of the following findings are sufficient for diagnosis and starting treatment with glucocorticoids, if other causes have been previously ruled out: fever, weight gain, respiratory distress, pulmonary infiltrates, pleural and/or pericardial effusion and/or renal failure.³

Treatment should be initiated with intravenous dexamethasone (10 mg/12 h) as soon as the syndrome is suspected. Corticosteroid treatment should continue until the syndrome has resolved, followed by gradual dose tapering over the subsequent weeks.⁴

In conclusion, DS is a relatively common serious complication in APL patients, and the time of presentation varies widely. Take-home messages: (1) suspect DS in APL patients receiving ATRA

and/or arsenic trioxide; (2) detect early signs of DS to confirm clinical diagnosis; and (3) examine the patient's behavior for rapid detection and treatment of complications.

References

1. Montesinos P, Sanz MA. The differentiation syndrome in patients with acute promyelocytic leukemia: experience of the PETHEMA group and review of the literature. *Mediterr J Hematol Infect Dis*. 2011;3:e2011059.
2. Camacho LH, Soignet SL, Chanel S, Ho R, Heller G, Scheinberg DA, et al. Leukocytosis and the retinoic acid syndrome in patients with acute promyelocytic leukemia treated with arsenic trioxide. *J Clin Oncol*. 2000;18:2620–5.
3. De Botton S, Dombret H, Sanz M, Miguel JS, Caillot D, Zittoun R, et al. Incidence, clinical features, and outcome of all trans-retinoic acid syndrome in 413 cases of newly diagnosed acute promyelocytic leukemia. The European APL Group. *Blood*. 1998;92:2712–8.
4. Wiley JS, Firkin FC. Reduction of pulmonary toxicity by prednisolone prophylaxis during all-trans retinoic acid treatment of acute promyelocytic leukemia. Australian Leukaemia Study Group. *Leukemia*. 1995;9:774–8.

Miguel Ariza-Prota,* Ana Pando-Sandoval, Marta García-Clemente

Servicio de Neumología, Hospital Universitario Central de Asturias, Oviedo, Asturias, Spain

* Corresponding author.

E-mail address: arizamiguel@hotmail.com (M. Ariza-Prota).

Pulmonary *Strongyloides stercoralis* Infection[☆]



Infestación pulmonar por *Strongyloides stercoralis*

To the Editor,

Strongyloides is a nematode that can repeat autoinfection cycles within the human host, perpetuating a chronic infection which may go unnoticed.¹ Migration of the larvae through the lungs can cause manifestations such as cough, dyspnea or wheezing,^{1–3} but the most typical manifestation is as a subclinical form of Löffler's

syndrome. However, in immunocompromised patients, the cycles are accelerated, the parasite may even disseminate to other organs, and mortality can be as high as 87%.⁴ We report a case of *Strongyloides stercoralis* infestation with severe lung involvement.

An 84-year-old man, active smoker with an accumulated consumption of 60 pack-years, hypertensive, gastrectomized 7 years previously due to gastric cancer, and operated again for splenic abscess requiring splenectomy. He had worked as a farmer, and had occasionally watered the land in his bare feet. He consulted due to a 5-month history of asthenia, dysphagia, low-grade fever, anorexia, and weight loss. He had been admitted to another hospital

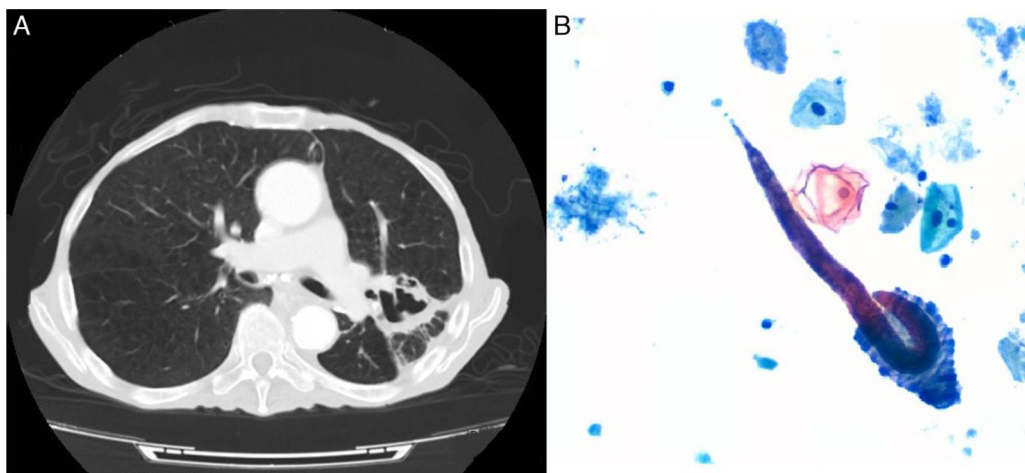


Fig. 1. (A) Chest computed axial tomography: consolidation in the posterior segment of the left upper lobe with areas of cavitation with irregular walls. (B) Bronchial aspirate cytology (Papanicolaou stain) showing *Strongyloides stercoralis* filariform larvae.

[☆] Please cite this article as: Esteban Ronda V, Franco Serrano J, Briones Urtiaga ML. Infestación pulmonar por *Strongyloides stercoralis*. *Arch Bronconeumol*. 2016;52:442–443.

for 14 days with a diagnosis of pneumonia, and received ertapenem, clindamycin, corticosteroids and bronchodilators. Seven days after discharge, he was brought to our hospital due to progressive deterioration. Physical examination revealed cachexia, crackles in the left hemithorax, and slightly tender abdomen. Clinical laboratory testing showed increased acute phase reactants, without eosinophilia. Computed axial tomography showed consolidation in the left upper lobe, areas of cavitation with irregular walls (Fig. 1A), and marked dilation of the loops of the small intestine. The patient was treated with piperacillin-tazobactam and amikacin, without improvement. Fiberoptic bronchoscopy was performed, showing a greenish liquid secretion, shown on bronchial aspirate cytology to contain *Strongyloides stercoralis* filariform larvae (Fig. 1B). In view of the diagnosis of pulmonary infestation, albendazole and ivermectin were added to the therapeutic regimen, but the patient progressively worsened and died 26 days later.

Strongyloides stercoralis filariform larvae penetrate through the skin and travel through the venous system to the right heart cavities, and from there to the lungs. They pass through the glottis to the digestive system where they lay their eggs, releasing non-infectious rhabditiform larvae. These can transform to invasive filariforms during the autoinfection cycles, penetrating the intestinal mucosa to complete the cycle,⁵ producing ulcerations making the patient susceptible to bacteremia. In pulmonary infestation, larvae infiltrate the alveolar and vascular spaces, progressing to diffuse hemorrhagic interstitial pneumonitis, acute respiratory distress syndrome, or lobar pneumonia, as in the case discussed here.^{2,3}

Our patient worked barefoot in the fields, which may explain the port of entry, while various factors may have precipitated the infestation: gastrectomy with the consequent achlorhydria, absence of spleen, malnutrition, and corticosteroid treatment.¹⁻⁴ It is interesting to note that *Strongyloides stercoralis* parasitosis is

not a strictly exotic disease: it is also endemic on the Mediterranean coast,² with the highest prevalence occurring in farmers in certain regions. It seems a reasonable approach to detect larvae in risk situations, particularly before initiating immunosuppressive treatments, to prevent disseminated disease and death.^{1,3,4}

Acknowledgement

We thank the Pathology Department of the Hospital Clínico Universitario de Valencia for their help and collaboration.

References

1. Mejia R, Nutman TB. Screening, prevention, and treatment for hyperinfection syndrome and disseminated infections caused by *Strongyloides stercoralis*. *Curr Opin Infect Dis*. 2012;25:458–63.
2. Igual R, Domínguez V. Strongyloidiasis: epidemiología, manifestaciones clínicas y diagnóstico. Experiencia en una zona endémica: la comarca de La Safor (Valencia). *Enferm Infecc Microbiol Clin*. 2007;25:38–44.
3. Keiser PB, Nutman TB. *Strongyloides stercoralis* in the immunocompromised population. *Clin Microbiol Rev*. 2004;17:208–17.
4. Llagunes J, Mateo E, Peña JJ, Carmona P, de Andrés J. Hiperinfección por *Strongyloides stercoralis*. *Med Intensiva*. 2010;34:353–6.
5. Murray PR, Rosenthal KS, Pfaller MA. Nematodes. In: Murray PR, et al., editors. *Medical Microbiology*. 6.a ed. Philadelphia: Elsevier Mosby; 2009. p. 853–70.

Violeta Esteban Ronda,* José Franco Serrano,
María Luisa Briones Urtiaga

Servicio de Neumología, Hospital Clínico Universitario, Valencia,
Spain

* Corresponding author.

E-mail address: violeta_er@hotmail.com (V. Esteban Ronda).

Three Cases of Odontological Foreign Body Bronchoaspiration[☆]



Broncoaspiración de cuerpo extraño odontológico. A propósito de tres casos

To the Editor:

We read with interest the article recently published by Gómez López et al.,¹ reporting a case of bronchoaspiration of a metal odontological foreign body. The authors emphasize the unusual nature of the aspirated material, since only 2 cases have been published, 1 of which was reported by the same authors.

In our hospital, we have had the opportunity to extract foreign bodies similar to that reported by the authors from 3 patients. In the first of these cases, on March 14, 2007, a foreign body was located in a 71-year-old man and subsequently extracted in the operating room under general anesthesia with rigid bronchoscopy and basket. On July 9, 2009, odontological material was extracted from a 63-year-old woman in the bronchoscopy room, with flexible 2.2 mm forceps under topical anesthesia only. On June 10, 2014, we attempted to extract material from the third patient, a 75-year-old woman, in the bronchoscopy room with flexible bronchoscopy and sedation with midazolam. The attempt failed, so the following day

the silicon prosthesis was removed with rigid bronchoscopy and rigid forceps under general anesthesia in the operating room.

In all cases, the patients were undergoing dental surgery with osseointegrated implants at the time of aspiration of the foreign body. The objects were lodged in the right bronchial tree (basal pyramid and intermediate bronchi), the effect of gravity causing the thickest section to settle in the distal position, with the point facing upwards, facilitating removal by the endoscopist, as described by Leuzzi et al.² The bronchoaspirated material to which we refer³ is the surgical steel tip of a manual torque wrench, 20 mm in length (several different sizes are marketed), with a 1.31 mm hexagonal




Fig. 1. Tip of manual torque key.

[☆] Please cite this article as: Páez Codeso FM, Dorado Galindo A, González Angulo GE. Broncoaspiración de cuerpo extraño odontológico. A propósito de tres casos. *Arch Bronconeumol*. 2016;52:443–444.