

limits its field of action to the tracheal and main bronchi. As this is a rigid instrument, it cannot be used with flexible bronchoscopy. It has been used in both malignant and benign lesions.<sup>2,3</sup> The literature on this device has all been generated outside Spain, and there is no record of it having been used in the lower airway in this country.

The main reason for choosing the microdebrider was that the patient presented an abnormal spirometry with a severe mixed pattern, and needed oxygen therapy at higher levels to maintain safe oxygen saturation. Thermo ablative endoscopic procedures (lasers, electrocautery, argon plasma) are known to require low FiO<sub>2</sub> due to the risk of ignition. Moreover, the speed with which mechanical resection can be performed greatly reduces anesthesia time, which is an important factor in patients with low cardiorespiratory reserves. Our patient had a permanent pacemaker, preventing the use of bronchial electrocautery. Another alternative would have been cryotherapy, but this is not available in our hospital.

In summary, we believe that mechanical debridement with this device offers new possibilities, and can be used when conventional thermoablation is either unavailable or unsafe.

## References

1. Lunn W, Garland R, Ashiku S, Thurer RL, Feller-Kopman D, Ernst A. Microdebrider bronchoscopy: a new tool for the interventional bronchoscopic. *Ann Thor Surg.* 2005;80:1485-8.
2. Kennedy MP, Morice RC, Jimenez CA, Eapen GA. Treatment of bronchial airway obstruction using a rotating tip microdebrider: a case report. *J Cardiothorac Surg.* 2007;2:16.
3. Meléndez J, Cornwell L, Green L, Casal RF. Treatment of large subglottic tracheal schwannoma with microdebrider bronchoscopy. *J Thorac Cardiovasc Surg.* 2012;144:510-2.

Francisco M. Páez Codeso,\* Antonio Dorado Galindo,  
Jordi Simó Pólit

*Servicio de Neumología, Hospital Regional Carlos Haya, Málaga, Spain*

\* Corresponding author.

E-mail address: [broncscopia.hch.sspa@juntadeandalucia.es](mailto:broncscopia.hch.sspa@juntadeandalucia.es)  
(F.M. Páez Codeso).

## Lung Injury Caused by All-Trans-Retinoic Acid in the Treatment of Acute Promyelocytic Leukemia<sup>☆</sup>



### *Afectación pulmonar por ácido transretinoico en el tratamiento de la leucemia promielocítica aguda*

To the Editor:

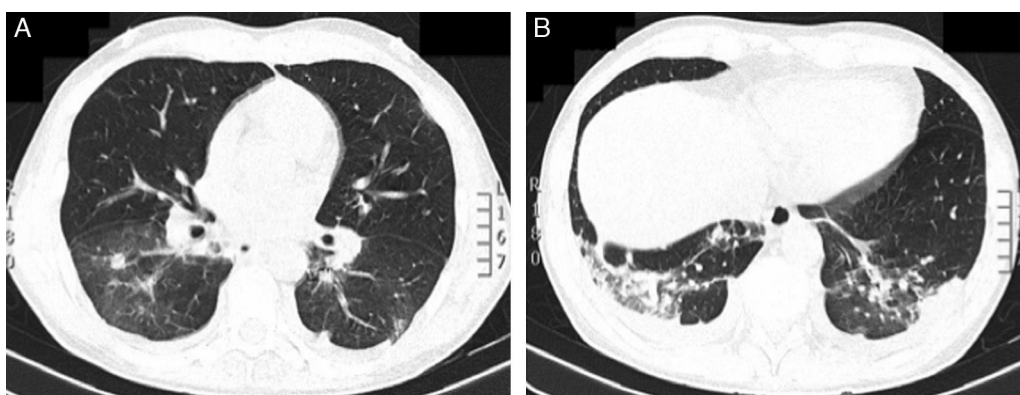
Treatment with all-trans-retinoic acid (ATRA) induces myeloid differentiation among leukemia cells in acute promyelocytic leukemia (APL). The differentiation syndrome (DS) or ATRA syndrome occurs in up to 25% of APL patients treated with ATRA, due to an inflammatory reaction accompanied by an increase in capillary permeability. It is characterized by breathing difficulties, fever, pulmonary infiltrates, pleuro-pericardial effusion, kidney failure, and hypotension.<sup>1</sup>

We report the case of a 45-year-old man with a diagnosis of APL, under treatment with ATRA (45 mg/m<sup>2</sup>) and idarubicin (12 mg/m<sup>2</sup>),

who developed fever and dyspnea hours after suspending prophylactic treatment with intravenous dexamethasone. Pulmonary auscultation revealed bilateral crackles. Chest radiograph showed a suspicious increase in density in the right lower lobe. The patient's situation was complicated by oxacillin-sensitive *Staphylococcus aureus* bacteremia, due to an infected catheter, which was treated with piperacillin-tazobactam and vancomycin.

As no clinical improvement was observed, a chest computed axial tomography was requested, showing bilateral nodules and ground glass densities, mainly in the lower lobes. An area of parenchymal consolidation and associated pleural effusion was identified in the left lower lobe (LLL) (Fig. 1A and B). Bronchoalveolar lavage was performed and microbiological cultures were negative. Treatment was started with intravenous dexamethasone (10 mg/12 h), showing favorable progress and complete resolution of the bilateral pulmonary infiltrate in less than 48 h. A diagnosis was given of DS due to ATRA treatment.

The introduction of ATRA in the treatment of APL has been one of the most significant advances in the management of



**Fig. 1.** Chest computed tomography showed: (A) Bilateral nodular lesions and ground glass densities, mainly affecting the lower lobes. (B) Area of parenchymal consolidation and associated pleural effusion in left lower lobe.

<sup>☆</sup> Please cite this article as: Ariza-Prota M, Pando-Sandoval A, García-Clemente M. Afectación pulmonar por ácido transretinoico en el tratamiento de la leucemia promielocítica aguda. *Arch Bronconeumol.* 2016;52:441-442.

hematological cancers. APL is now the most curable form of adult myeloid leukemia, with full remission persisting at 5 years and 70%–80% survival.<sup>2</sup> However DS associated with ATRA administration is probably the most toxic adverse event. The prophylactic use and length of administration of corticosteroids are controversial. Our patient received prophylactic treatment with intravenous dexamethasone, but even so, developed the syndrome. The latest PETHEMA protocol recommends prophylaxis in all patients receiving  $>5 \times 10^9 \text{ l}^{-1}$  for 15 days. DS mortality is currently low (1%), due to early treatment with corticosteroids, along with the concomitant use of chemotherapy in combination with ATRA.<sup>3</sup>

DS is a clinical diagnosis based on a group of signs and symptoms in APL patients receiving induction treatment with ATRA or arsenic trioxide. Three or more of the following findings are sufficient for diagnosis and starting treatment with glucocorticoids, if other causes have been previously ruled out: fever, weight gain, respiratory distress, pulmonary infiltrates, pleural and/or pericardial effusion and/or renal failure.<sup>3</sup>

Treatment should be initiated with intravenous dexamethasone (10 mg/12 h) as soon as the syndrome is suspected. Corticosteroid treatment should continue until the syndrome has resolved, followed by gradual dose tapering over the subsequent weeks.<sup>4</sup>

In conclusion, DS is a relatively common serious complication in APL patients, and the time of presentation varies widely. Take-home messages: (1) suspect DS in APL patients receiving ATRA

and/or arsenic trioxide; (2) detect early signs of DS to confirm clinical diagnosis; and (3) examine the patient's behavior for rapid detection and treatment of complications.

## References

1. Montesinos P, Sanz MA. The differentiation syndrome in patients with acute promyelocytic leukemia: experience of the PETHEMA group and review of the literature. *Mediterr J Hematol Infect Dis*. 2011;3:e2011059.
2. Camacho LH, Soignet SL, Chanel S, Ho R, Heller G, Scheinberg DA, et al. Leukocytosis and the retinoic acid syndrome in patients with acute promyelocytic leukemia treated with arsenic trioxide. *J Clin Oncol*. 2000;18:2620–5.
3. De Botton S, Dombret H, Sanz M, Miguel JS, Caillot D, Zittoun R, et al. Incidence, clinical features, and outcome of all trans-retinoic acid syndrome in 413 cases of newly diagnosed acute promyelocytic leukemia. The European APL Group. *Blood*. 1998;92:2712–8.
4. Wiley JS, Firkin FC. Reduction of pulmonary toxicity by prednisolone prophylaxis during all-trans retinoic acid treatment of acute promyelocytic leukemia. Australian Leukaemia Study Group. *Leukemia*. 1995;9:774–8.

Miguel Ariza-Prota,\* Ana Pando-Sandoval, Marta García-Clemente

Servicio de Neumología, Hospital Universitario Central de Asturias, Oviedo, Asturias, Spain

\* Corresponding author.

E-mail address: arizamiguel@hotmail.com (M. Ariza-Prota).

## Pulmonary *Strongyloides stercoralis* Infection<sup>☆</sup>



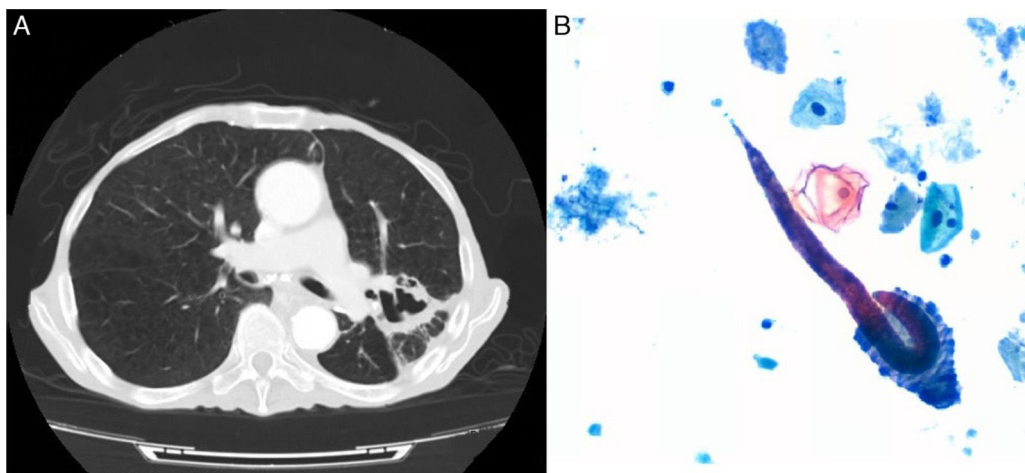
### Infestación pulmonar por *Strongyloides stercoralis*

To the Editor,

*Strongyloides* is a nematode that can repeat autoinfection cycles within the human host, perpetuating a chronic infection which may go unnoticed.<sup>1</sup> Migration of the larvae through the lungs can cause manifestations such as cough, dyspnea or wheezing,<sup>1–3</sup> but the most typical manifestation is as a subclinical form of Löffler's

syndrome. However, in immunocompromised patients, the cycles are accelerated, the parasite may even disseminate to other organs, and mortality can be as high as 87%.<sup>4</sup> We report a case of *Strongyloides stercoralis* infestation with severe lung involvement.

An 84-year-old man, active smoker with an accumulated consumption of 60 pack-years, hypertensive, gastrectomized 7 years previously due to gastric cancer, and operated again for splenic abscess requiring splenectomy. He had worked as a farmer, and had occasionally watered the land in his bare feet. He consulted due to a 5-month history of asthenia, dysphagia, low-grade fever, anorexia, and weight loss. He had been admitted to another hospital



**Fig. 1.** (A) Chest computed axial tomography: consolidation in the posterior segment of the left upper lobe with areas of cavitation with irregular walls. (B) Bronchial aspirate cytology (Papanicolaou stain) showing *Strongyloides stercoralis* filariform larvae.

<sup>☆</sup> Please cite this article as: Esteban Ronda V, Franco Serrano J, Briones Urtiaga ML. Infestación pulmonar por *Strongyloides stercoralis*. *Arch Bronconeumol*. 2016;52:442–443.