

tip. This device is attached to the torque wrench and used to screw in the titanium abutment screw, a step phase in this type of surgery. For safety purposes, these tips have a rotating crown which allows the screw to be turned, and is furnished with a small hole, as can be seen in the image, into which dental floss is introduced to prevent it falling and being aspirated (Fig. 1).

Our experience prompts us to make some comments. The methods of extraction in each of our 3 cases were very different, and the procedure depended basically on the degree of collaboration of the patient, and either flexible or rigid bronchoscopy was used to the same effect. We would advise an initial attempt with the former, as it is much more accessible in our hospital setting. However, any difficulty encountered during this procedure can be easily overcome with the use of rigid bronchoscopy. We were asked to provide 2 of the extracted pieces, which were presented as evidence in subsequent legal claims. Thus, we highlight the need for prevention of accidents of this kind, in view of their frequent occurrence, potential severity, and medical and legal implications.

Founder Mutation C.3344C>t(p.Pro1115Leu) in the EIF2KA4 Gene in Iberian Romani Patients With Pulmonary Venous-Occlusive Disease: A Warning for our Daily Practice*



Hallazgo de la mutación fundadora C.3344C>t(p.Pro1115Leu) en el gen EIF2KA4 en pacientes ibéricos de etnia gitana con enfermedad veno-oclusiva pulmonar: una llamada de atención a nuestra práctica diaria

To the Editor:

Pulmonary venous-occlusive disease (PVOD) is a rare form of pulmonary arterial hypertension. The incidence of this entity is unknown, partly due to underdiagnosis and mistaken classification as idiopathic pulmonary arterial hypertension (IPAH).

PVOD is distinguished by a marked reduction in carbon monoxide diffusing capacity (DLCO) and a typical radiological pattern. It occurs more often in men, and has a more aggressive course than IPAH.¹ Multiple causes, including genetic alterations, have been associated with its development. Recently, homozygous or compound heterozygous mutation of the *EIF2AK4* gene was described as the cause of PVOD. This mutation appears to occur in 25% of sporadic cases and 100% of familial cases, showing an autosomal recessive inheritance pattern and high penetrance.¹

Our group has described a homozygous founder mutation C.3344C>T(p.Pro1115Leu) in *EIF2AK4* in 18 patients from 10 highly consanguineous Romani families with several affected members (Table 1).²

All patients developed the disease as young adults (mean: 27.43±7.3 years), and most progressed rapidly to a fatal outcome (death or double-lung transplantation) in the first year after diagnosis.

Although the clinical characteristics of the patients varied on diagnosis, they all had a common trait: severely reduced DLCO.

It is interesting to note that the study of family members revealed a high incidence of death among relatives with no genetic studies but with a history suggestive of PVOD. Moreover, we

* Please cite this article as: Navas P, Rodríguez Reguero JJ, Escribano Subías P. Hallazgo de la mutación fundadora C.3344C>t(p.Pro1115Leu) en el gen *EIF2KA4* en pacientes ibéricos de etnia gitana con enfermedad veno-oclusiva pulmonar: una llamada de atención a nuestra práctica diaria. Arch Bronconeumol. 2016;52:444–445.

References

- Gómez López A, García Lujan R, de Miguel Poch E. Broncoaspiración de cuerpos extraños. Caso clínico y revisión. Arch Bronconeumol. 2015;51:357–68.
- Leuzzi G, Kawamukai K, Lacava N. An unusual foreign body after dental filling. Lung. 2013;191:677–8.
- Martínez-González JM, Cano Sánchez J, Campo Trapero J, Martínez González MJS, García-Sabán F. Diseño de los implantes dentales: estado actual. Av Periodon Implantol. 2002;14:129–36.

Francisco M. Páez Codeso,* Antonio Dorado Galindo, Gracia Eugenia González Angulo

Servicio de Neumología, Hospital Regional Carlos Haya, Málaga, Spain

* Corresponding author.

E-mail address: bronicoscopia.hch.sspa@juntadeandalucia.es (F.M. Páez Codeso).

found an alarming number of family members (59.7%) who were heterozygous carriers of the mutation, generating a risk of new homozygous cases in future generations (Table 1).

At the current time, the Romani population in Spain, a community characterized by a high level of consanguinity, is estimated to be around 750 000 individuals distributed around the whole country.^{3,4} Since this *EIF2AK4* mutation appears to be typical of the Romani race, and in view of the severity of the disease, we are facing a potentially serious public health problem among this population, which could be partially prevented by early genetic diagnosis and appropriate genetic counseling aimed at reducing the number of new cases.

Therefore, we believe that maintaining a high level of suspicion is essential for Spanish physicians: and that PVOD must be ruled out and a genetic study for *EIF2AK4* should be performed (as lung biopsy is contraindicated) in those Romani patients presenting with dyspnea and a family history of PAH or severely diminished DLCO. If *EIF2KA4* homozygous mutations are found, the patient must be rapidly referred to a hospital with an available lung transplantation program being the initiation of pulmonary vasodilators contraindicated due to the high risk of triggering severe pulmonary edema. Moreover, family members of carriers of this mutation must be screened and given appropriate genetic counseling, in order to avoid new cases in future generations and to prevent the propagation of this devastating disease.

Table 1
Summary of Families Studied.

Family	No. of Index Cases	No. of Family Members Studied	No. of Healthy Heterozygous Family Members	No. of Homozygous Family Members Without PVOD
Family 1	3	12	7	0
Family 2	1	0	0	0
Family 3	4	13	8	1
Family 4	1	1	1	0
Family 5	1	0	0	0
Family 6	3	28	21	1
Family 7	1	1	0	0
Family 8	0	8	3	0
Family 9	2	5	1	0
Family 10	2	1	0	0
Total	18	67	40	2

PVOD: pulmonary venous-occlusive disease.

Funding

Cardiovascular Research Network (RIC) of the Instituto de Salud Carlos III, the Spanish Pulmonary Hypertension Association, Actelion and the Fundación Air Liquide.

References

1. Eyries M, Montani D, Girerd B, Perret C, Leroy A, Lonjou C, et al. *EIF2AK4* mutations cause pulmonary veno-occlusive disease, a recessive form of pulmonary hypertension. *Nat Genet.* 2014;46:65–9.
2. Tenorio J, Navas P, Barrios E, Fernández L, Nevado J, Quezada CA, et al. A founder *EIF2AK4* mutation causes an aggressive form of pulmonary arterial hypertension in Iberian Gypsies. *Clin Genet.* 2015;88:579–83.
3. Laparra M. Informe sobre la situación social y tendencias de cambio en la población gitana. In: *Una primera aproximación*. Ministerio de Trabajo y Asuntos Sociales; 2007.
4. Estrategia Nacional para la Inclusión Social de la población Gitana en España 2012–2020.

Paula Navas,^{a,b,*} Jose Julián Rodríguez Reguero,^c
Pilar Escribano Subías^d

^a Servicio de Cardiología, Hospital Universitario Gregorio Marañón, Madrid, Spain

^b Red de investigación Cardiovascular, Instituto de Salud Carlos III, Madrid, Spain

^c Servicio de Cardiología, Hospital Central de Asturias, Oviedo, Asturias, Spain

^d Unidad Multidisciplinar de Hipertensión Pulmonar, Servicio de Cardiología, Hospital Universitario Doce de Octubre, Red de investigación Cardiovascular, Instituto de Salud Carlos III, Madrid, Spain

* Corresponding author.

E-mail address: paulanavastejedor@gmail.com (P. Navas).

Hypersensitivity Pneumonitis as a Complication of Intravesical BCG Therapy for Bladder Cancer[☆]



Neumonitis por hipersensibilidad como complicación del tratamiento con BCG intravesical por carcinoma de vejiga

To the Editor,

Hypersensitivity pneumonitis (HP) or extrinsic allergic alveolitis is a pulmonary interstitial disease mainly caused by sensitization to a variety of inhaled organic particles.¹ The airborne antigens which most commonly lead to the development of this hypersensitivity reaction are thermophiles, molds, and avian antigens.¹ However, some cases caused by non-inhaled medications have also been reported, including exposure to bacillus Calmette–Guérin (BCG) in the treatment of urothelial bladder carcinoma,² such as the one we describe here.

A 73-year-old man, former smoker (accumulated consumption of 30 pack-years), arterial hypertension, with no known drug

allergies. He did not report any occupational or environmental exposure to birds, feathers or other organic substances. He had been diagnosed 3 months previously with superficial papillary urothelial carcinoma and was receiving treatment with intravesical BCG. He was admitted with a 10-day history of acute clinical symptoms, consisting of general malaise, deterioration, and fever 39 °C, coinciding with the eighth instillation of BCG. Clinical laboratory results showed leukocytes 11 900 (neutrophils 81%), C-reactive protein 87 mg/dl, and elevated liver function markers (GGT and AP). Tumor markers and angiotensin converting enzyme were normal. Cultures of sputum, urine, bronchoalveolar lavage (BAL), and blood, including Löwenstein–Jensen medium, were negative, as were pneumococcal and Legionella urinary antigen testing. Immunoglobulins (Ig) G and M were normal. Serum IgG (precipitins) for molds, birds, and feathers were negative. Chest HRCT revealed a ground glass pattern in both upper lobes, small centrilobular nodules, and consolidations in the lung bases (Fig. 1(A)). Cell distribution in BAL was: alveolar macrophages 44% and lymphocytes 56%. Flow cytometry immunophenotyping of the lymphocyte

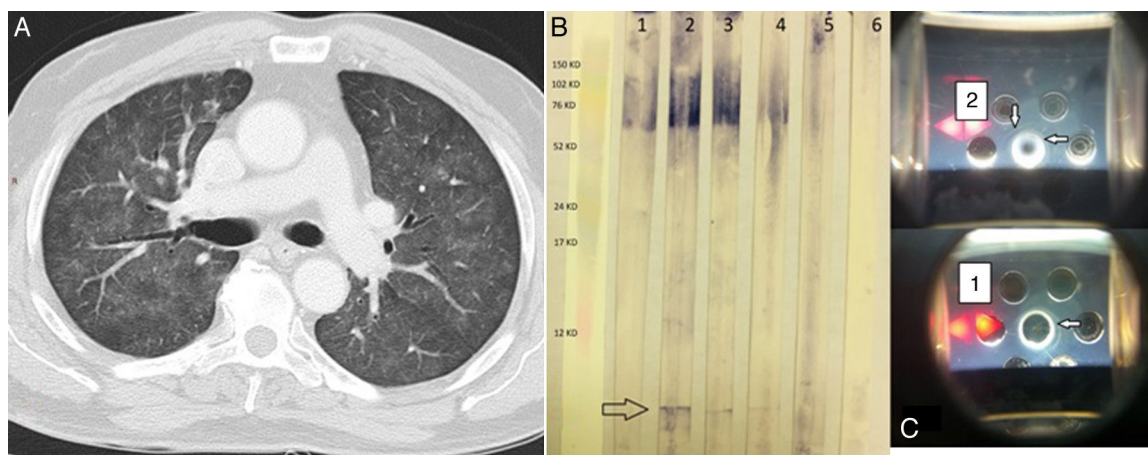


Fig. 1. (A) Chest HRCT. Pulmonary parenchymal window shows a ground glass pattern and small centrilobular nodules in both lung fields. (B) Western blot. Lane 1 shows the serum of an asymptomatic individual receiving BCG; lanes 2, 3, and 4 show the index case after 3, 7, and 51 of corticosteroid therapy. Lane 5 shows the serum of an individual with a history of tuberculosis, and lane 6 is that of a healthy control. The arrow indicates a single band (specific anti-BCG antibodies). (C) Double immunodiffusion of sera 1 and 2. Arrows indicate precipitation bands.

[☆] Please cite this article as: Carrasco Hernández L, Castaño Núñez ÁL, Rodríguez Portal JA. Neumonitis por hipersensibilidad como complicación del tratamiento con BCG intravesical por carcinoma de vejiga. *Arch Bronconeumol.* 2016;52:445–446.