

Letters to the Editor

Exogenous Lipid Pneumonia in Laryngectomy Patients: Is Ground Glass Opacity/Crazy Paving Pattern an Organizing Pneumonia Reaction That Can Predict Poor Outcome?*



Neumonía lipóidea exógena en pacientes laringectomizados: ¿es el patrón de opacificación en vidrio esmerilado/en empedrado una reacción organizada de la neumonía capaz de predecir una mala evolución?

To the Editor,

We have read with great interest the exogenous lipid pneumonia (ELP) case series from Latorre et al.,¹ which elegantly demonstrates the radiological findings inherent to pathological aspiration of petroleum jelly (Vaseline). The authors report that the most common high-resolution computed tomography (HRCT) findings in ELP are areas of low attenuation and ground glass opacity (GGO). However, on careful analysis, the CT images for Case 1 exclusively show peribronchial consolidation tissue, but no areas of GGO. The second case reported, supported by CT, CT-PET and MRI, very clearly shows fat in middle lobe. Some of the clinical cases did not have an accompanying radiological image. We respectfully would like to share our experience of two cases of aspiration of oily product, used for cleaning the stoma in adult patients (a 63-year-old woman and a 68-year-old man) after laryngectomy for cancer. Our patients showed an extended GGO component in the middle lobe, lingula and lower lobes, confirmed on bronchoalveolar lavage testing to be alveolar lipid-laden macrophages. Despite the administration of corticosteroids for a period of 6 months (after discontinuing the use of Vaseline), the results were very disappointing: the man showed absolute stability of the HRCT findings and the woman's GGO component continued to worsen, to a greater extent in the lower lobes (Fig. 1). The clinical conditions of both patients worsened with further marked reduction in DLCO in both cases. We are aware that this deterioration could be associated with an increased level of inflammation due to fatty acids, as described in a recent paper.² Fatty acids either remain in the alveolar compartment or are phagocytized by macrophages that then migrate to the interlobular septa. This phenomenon could partly explain the meaning of the "crazy paving" pattern observed on HRCT.³ However, we assume that reactivity of the affected lung is also consistent with organizing pneumonia, leading to toxic lung

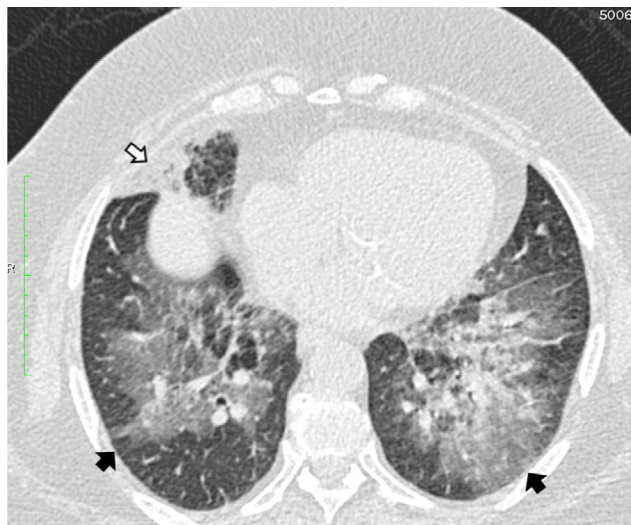


Fig. 1. High resolution computed tomography scan of the chest shows peribronchial fat consolidation in middle lobe (white arrows). Extensive representation of GGO containing subtle reticulation (crazy paving) up to pleural spaces (black arrows) 8 months after discontinuing petroleum jelly (Vaseline) and steroid therapy (prolonged for 6 months).

injury.⁴ Due to their critical clinical status, our patients could not undergo a lung biopsy so our findings unfortunately remain only a hypothesis. To sum up, HRCT is the best imaging modality for establishing the diagnosis of lipid pneumonia. However, there is an important issue which needs clarification: according to Marchiori et al.,⁵ consolidation is common in children, while GGO and crazy paving are more often seen in adults. The question here is why, after treatment, do areas of GGO and crazy paving sometimes become more extended but with no signs of fibrosis. In conclusion, in patients with pathological findings due to aspiration of petroleum jelly used to clean the tracheostoma, a careful clinical evaluation with FEV1 spirometry and possibly low dose HRCT with narrowed slices is recommended in cases in which GGO is a dominant HRCT pattern.

References

- García Latorre R, Rodríguez Díaz R, Barrios Barreto D, Ayala Carbonero A, García Gómez-Muriel MI, Gorospe Sarasúa L. Hallazgos radiológicos de la neumonía lipóidea exógena en pacientes laringectomizados. *Arc Bronconeumol.* 2015;51:e36–9.
- Agarwal R. Low attenuation consolidation – the most characteristic findings in lipid pneumonia. *Eur J Intern Med.* 2006;17:307.

* Please cite this article as: Rea G, Lassandro F, Valente T. Neumonía lipóidea exógena en pacientes laringectomizados: ¿es el patrón de opacificación en vidrio esmerilado/en empedrado una reacción organizada de la neumonía capaz de predecir una mala evolución?. *Arch Bronconeumol.* 2016;52:438–439.

3. Betencourt SL, Martínez-Jiménez S, Rossi SE, Truong MT, Jorge Carrillo J, Erasmus JJ. Lipoid pneumonia: spectrum of clinical and radiological manifestations. *AJR Am Roentgenol.* 2010;194:103–9.
4. Kulhawick D, Walecky J. Toxic lung injury in a patient addicted to “legal highs” – case study. *Pol J Radiol.* 2015;80:62–6.
5. Marchiori E, Zanetti G, Mano CM, Irion KL, Daltro PA, Hochegger B. Lipoid pneumonia in 53 patients after aspiration of mineral oil: comparison of high-resolution computed tomography findings in adults and children. *J Comput Assist Tomogr.* 2010;34:9–12.

Gaetano Rea,* Francesco Lassandro, Tullio Valente

Servicio de Radiología, Hospital Monaldi, Nápoles, Italy

* Corresponding author.

E-mail address: gaetano.rea71@gmail.com (G. Rea).

Life-Threatening Hemoptysis Secondary to Rasmussen's Aneurysm in an HIV Patient[☆]



Hemoptisis amenazante secundaria a aneurisma de Rasmussen en paciente VIH

To the Editor:

Life-threatening hemoptysis is a medical emergency defined as the expectoration of over 250 ml blood in a 24-h period. If left untreated, mortality is 80%. Most cases originate in hypertrophic bronchial arteries. However, a small percentage of life-threatening hemoptysis occurs in pulmonary arteries weakened by infectious processes caused by mycobacteria or fungi.^{1,2}

We report the case of a 55-year-old man with advanced human immunodeficiency virus infection (stage C3), smoker and former intravenous drug user, who presented at our hospital with life-threatening hemoptysis, hypotension and tachycardia. In addition to emphysema phenotype chronic obstructive lung disease and hepatitis C-related liver cirrhosis, he had had multiple lung infections caused by unusual pathogens (*Pneumocystis jirovecii*, non-tuberculous mycobacteria, semi-invasive aspergillosis, etc.) that were treated, although treatment adherence was poor. A chest computed tomography (CT) angiography was performed, showing an aneurysm 1 cm in diameter in the subsegmentary pulmonary artery of the right lower lobe (Fig. 1) and signs of ipsilateral pulmonary hemorrhage (Fig. 1C), associated with a Rasmussen's aneurysm. In view of the patient's hemodynamic instability, an

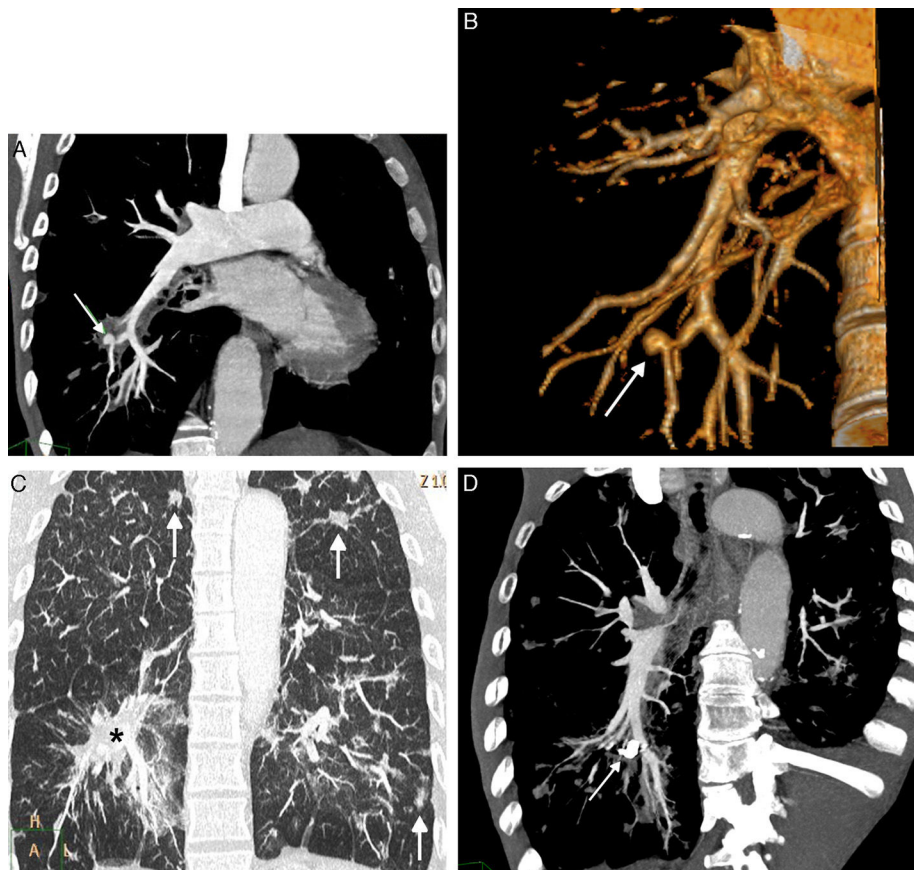


Fig. 1. (A) Coronal maximum intensity projection (MIP) CT reconstruction, showing a Rasmussen's aneurysm (arrow) on a subsegmentary branch of the right lower lobe artery. (B) CT volumetric reconstruction (3D or volume rendering) confirming Rasmussen's aneurysm (arrow). (C) Coronal MIP CT reconstruction (pulmonary parenchyma window) showing signs of lung hemorrhage (asterisk) and bilateral residual infectious parenchymal opacities (arrows). (D) Coronal oblique MIP CT reconstruction after embolization showing embolization material (coil) occluding the Rasmussen's aneurysm (arrow).

[☆] Please cite this article as: Oriol AJ, Ayala Carbonero AM, Sarasúa LG. Hemoptisis amenazante secundaria a aneurisma de Rasmussen en paciente VIH. *Arch Bronconeumol.* 2016;52:439–440.