

Bronchial Schwannoma: An Uncommon Tumor[☆]



Schwannoma bronquial, un tumor poco frecuente

To the Editor,

Bronchial schwannomas, also known as granular cell tumors and myoblastomas, are uncommon benign tumors¹ that rarely occur in the bronchi. Disease course is benign and treatment of choice is surgery.

A 40-year-old woman, smoker of 20 pack-years, with clinical criteria for chronic bronchitis, presented in the emergency department with a 2-day history of fever 39°C, general malaise, dry cough, myalgia, headache, and pharyngeal pain. Chest X-ray revealed alveolar infiltrate in the left upper lobe (LUL). A diagnosis of community-acquired pneumonia was given, and she was prescribed levofloxacin 500 mg for 7 days in an outpatient setting. Four weeks later, a radiological control was performed and the patient was referred to the respiratory medicine department. During anamnesis, she reported a long history of episodes of lower respiratory tract infections. Physical examination and blood test results were normal. Chest X-ray showed LUL atelectasis with left hilar elevation. Chest computed tomography revealed a 2 cm nodular lesion in the LUL, causing partial atelectasis, with no mediastinal or hilar lymphadenopathies. Spirometric results were normal. Fiberoptic bronchoscopy showed a pedunculated lesion in the left bronchial tree, obstructing the upper lobe. The lesion surface was smooth, shiny and vascularized. It was contingent on the carina dividing the lobes, and there was no adhesion to the lateral walls. Biopsy showed fusiform, polygonal cells and granular cytoplasm with immunohistochemical (IHC) expression

of neuron-specific enolase, S100 protein and vimentin (Fig. 1), indicative of LUL schwannoma.

The LUL was lobectomized, and the patient did not require any further treatment.

Schwannomas are extremely rare¹ benign tumors, originating in the Schwann cells that produce the myelin sheath of the peripheral nerves. The first case was described by Feckner in 1938, and at least 80 cases have been published since then. These are slow-growing tumors, that do not infiltrate the neuronal axon, but which can affect nerve conduction by extrinsic compression. They appear in wide range of sites, the most common of which are the skin and the tongue.² Endobronchial presentation occurs in only 6% of cases.^{2,3}

Schwannomas generally occur in middle age, and no differences are observed between sexes.¹ Clinical presentation can vary, and is determined by the size and location. Early symptoms include asthma, unproductive cough, recurrent infections (as in our case), fever, dyspnea and hemoptysis.^{2,3} Lesions tend to develop in the large bronchi or in bifurcations.^{3,4} Up to 25% may be multiple, and they can even mimic metastasis, if they occur concomitantly with other neoplasms.² Radiographs can be useful in differential diagnosis, but definitive diagnosis is usually obtained on fiberoptic bronchoscopy for atelectasis and secondary pneumonia, as in our case.^{2,3}

On histological examination, tumor cells are polygonal and fusiform, with granular cytoplasm. On IHC, antigen expression is positive for S100 protein, vimentin, neuron-specific enolase, and negative for keratins.⁴

While endoscopic resection has been recommended for treating small lesions, surgical resection is still the treatment of choice due to the risk of recurrence, irrespective of tumor size.^{3,5} Prognosis is favorable, and mean survival after surgery is longer than 5 years.¹

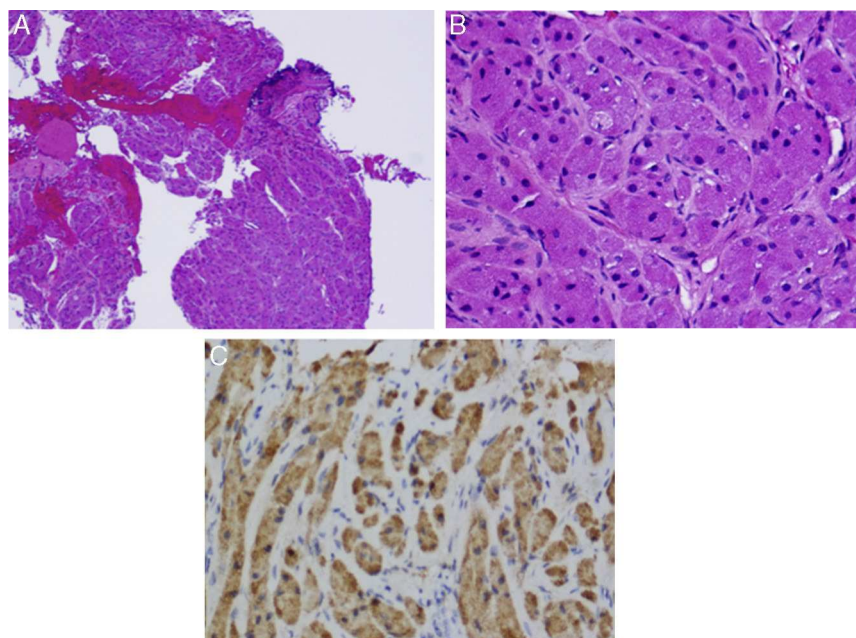


Fig. 1. (A) An area of bronchial epithelium can be seen on lower magnification (top right, darker area). The rest of the sample consists of tumor tissue. (B) Fusiform cells and granular cytoplasm can be seen on greater magnification. Bronchial schwannoma or granular cell tumor. (C) Immunohistochemistry positive for S100 (darker staining).

[☆] Please cite this article as: Landete P, Chiner E, Sancho-Chust JN, Pérez-Ferrer P. Schwannoma bronquial, un tumor poco frecuente. Arch Bronconeumol. 2015;51:471–472.

Conflict of Interests

The authors state that they have no conflict of interests.

References

1. Shrager JB, Kaiser LR. Benign lung tumors. In: Patterson GA, Cooper JD, Deslauriers J, Lerut A, Luketich JD, Rice TW, editors. *Pearson's thoracic-esophageal surgery*. 3rd ed. Philadelphia: Churchill Livingstone; 2008. p. 691-3.
2. Deavers M, Guinee D, Koss MN, Travis MD. Granular cell tumor of the lung. *Clinicopathologic study of 20 cases*. *Am J Surg Pathol*. 1995;19:627-35.
3. Durán Toconás JC, Obeso Carillo GA, Cañizares Carretero MÁ. Granular cell tumours: an uncommon endobronchial neoplasm. *Arch Bronconeumol*. 2011;47:214.

4. Meyer MA, Becker JM, Quinones W. Endobronchial granular cell tumor: a case report. *J Radiol Case Rep*. 2010;4:29-35.
5. Jiang M, Anderson T, Nwogu C, Tan D. Pulmonary malignant granular cell tumor. *World J Surg Oncol*. 2003;1:1-22.

Pedro Landete, Eusebi Chiner,* José Norberto Sancho-Chust, Patricia Pérez-Ferrer

Servicio de Neumología, Hospital Universitario San Juan de Alicante, San Juan, Alicante, Spain

* Corresponding author.

E-mail address: echinervives@gmail.com (E. Chiner).

Pertussis in Adults: A Growing Diagnosis in the Pulmonology Clinic^{*}



Tos ferina del adulto: una enfermedad emergente en la consulta del neumólogo

To the Editor,

Although cough following pertussis infection is one of the causes of chronic cough¹ (Table 1), this entity is rarely suspected in adults. Recent data, however, show that pertussis control is failing, and outbreaks² affecting adults are being reported, due to gradual loss of the immunity acquired with childhood vaccination. We report the case of a 40-year-old woman with persistent cough who was referred to a specialized asthma clinic where the final diagnosis of pertussis was made.

This was a 40-year-old woman, with no toxic habits and no routine medication. Her only disease history was squamous cell carcinoma of the buccal mucosa treated with radiation therapy administered to the right side of the face and neck 2 years previously. Response was complete. On this occasion, she presented dry cough, post-nasal drip and rhinorrhea that were treated with azithromycin, antihistamines and nasal corticosteroids, with mild initial improvement. One week later, however, the cough increased and she had her first attack of convulsive cough with laryngeal spasm. Episodes of paroxysmal cough increased in frequency until they occurred daily, with sudden onset, predominantly at night. She was assessed by the eye, nose and throat (ENT) specialist, who ruled out ENT disease and referred the patient to the asthma clinic. The patient was prescribed inhaled and systemic corticosteroids, with no improvement. Chest X-ray and lung function test results were normal, and the bronchodilator test was negative with oral exhalation of nitric oxide levels of 5 ppb. Laboratory tests revealed 13 300 leukocytes/mm³ with 77% neutrophils. Pertussis was suspected clinically, so a culture of pharyngeal exudate for *Bordetella pertussis* was requested, for which genomic detection was positive. Diagnosis was confirmed 9 weeks after onset of clinical symptoms. All treatment was discontinued, and the patient's cough abated gradually, until it was completely resolved. Her vaccination calendar was reviewed, showing that she had received 3 doses of the diphtheria-tetanus-pertussis (DTP) vaccine at age 10, 11 and 16 months, and 2 booster doses at 3 and 13 years.

^{*} Please cite this article as: Cepeda S, Martínez Moragón E, Ponce S. Tos ferina del adulto: una enfermedad emergente en la consulta del neumólogo. *Arch Bronconeumol*. 2015;51:472-473.

Pertussis is a highly contagious acute respiratory infection of the upper respiratory tract caused by the bacteria *Bordetella pertussis*. It is characterized by episodes of highly limiting violent coughing, occasionally accompanied by whooping on inspiration. Humans are the only known reservoir of infection and the mechanism of transmission is direct contact with secretions from infected respiratory mucosa. After incubation (7-10 days) and a catarrhal period with non-specific symptoms (1-2 weeks), the paroxysmal phase begins (2-4 weeks) with convulsive cough followed by deep inspiration against a closed glottis at the end of the paroxysm, which produces the typical whoop. It gradually resolves after 3 months, but the incidence of residual cough in adults can be as high as 50%.³ In these patients, clinical symptoms are more latent: cough is severe and prolonged, mainly at night, and less paroxysmal than in children,⁴ which contributes to underdiagnosis. In our case, the diagnostic delay was considerable: asthma was suspected and the patient even received treatment with oral corticosteroids. It is our opinion, then, that pulmonologists should not overlook pertussis in patients with persistent cough. Once suspected, diagnosis is simple.

Table 1

Causes of Chronic Cough.

Causes of chronic cough
<i>Common causes</i>
- Post-nasal drip (8%-87%)
- Asthma (20%-33%)
- Gastroesophageal reflux (10%-21%)
- Eosinophilic bronchitis (13%)
- Chronic bronchitis and COPD (5%)
- Bronchiectasis (4%)
- Lung cancer (2%)
- Medications: ACE inhibitors (0.2%-32%), and others
- Diffuse interstitial lung diseases
- Postinfectious cough (11%-25%): virus, <i>Mycoplasma pneumoniae</i> , <i>Chlamydia pneumoniae</i> and <i>Bordetella pertussis</i>
<i>Uncommon causes</i>
- Psychogenic cough
- Occult lung infection
- Immunological diseases: temporal arteritis, Sjögren's syndrome, etc.
- Left heart failure
- Mass or aspirated foreign body
- "Bronchitis" due to toxic occupational exposure
- Nasal polyposis. Rhinoliths
- Occipital neuralgia
- Tracheobronchomalacia
- Mediastinal diseases: Hodgkin's lymphoma
- Upper airway obstruction: tracheal, laryngeal or thyroid tumors, vascular malformations
- Central nervous system diseases
- Myopathies
- Gilles de la Tourette syndrome

Source: Taken from SEPAR guidelines on chronic cough.¹