



## Case Report

# Thoracic Pulmonary Endometriosis: Two Reports of a Rare Disease<sup>☆</sup>



Ahmet Ucvet, Esra Yamansavci Sirzai, Funda Cansun Yakut, Banu Yoldas,\* Soner Gursoy

Department of Thoracic Surgery, Izmir Dr. Suat Seren Chest Diseases and Thoracic Surgery Training and Research Hospital, Izmir, Turkey

## ARTICLE INFO

### Article history:

Received 24 June 2013

Accepted 5 November 2013

Available online 11 August 2014

### Keywords:

Pulmonary  
Endometriosis  
Hemoptysis  
Surgery

## ABSTRACT

Endometriosis is characterized by the growth of endometrium outside the uterine cavity or myometrium. There is no specific radiologic finding that defines endometriosis. Parenchymal lesions, nodules or blebs are reported in the literature, although this clinical entity is rare. Definitive diagnosis and treatment are often possible with surgery. We report here two cases: a forty-two-year-old female patient with a 2-year history of intermittent hemoptysis associated with her menstrual cycle was diagnosed as having endometriosis and treated via thoracotomy; another 30-year-old female referred to our department due to recurrent pneumothorax caused by underlying endometriosis underwent surgical treatment which revealed endometrial foci on the diaphragm.

© 2013 SEPAR. Published by Elsevier España, S.L.U. All rights reserved.

## Endometriosis pulmonar torácica: presentación de 2 casos de una enfermedad muy poco frecuente

## RESUMEN

La endometriosis se caracteriza por el crecimiento del endometrio fuera de la cavidad uterina o el miometrio. No hay signos radiológicos específicos que indiquen una endometriosis. En la literatura se describen lesiones parenquimatosas, nódulos o bullas. El diagnóstico de certeza y el tratamiento son posibles a menudo con la cirugía. A una mujer de 42 años de edad con hemoptisis intermitente (asociada al ciclo menstrual) desde hacía 2 años se le diagnosticó una endometriosis y fue tratada mediante una toracotomía. Otra mujer de 30 años fue remitida a nuestro departamento a causa de un neumotórax recurrente causado por una endometriosis subyacente, y se le aplicó un tratamiento quirúrgico que puso de manifiesto la presencia de focos de endometrio en el diafragma.

© 2013 SEPAR. Publicado por Elsevier España, S.L.U. Todos los derechos reservados.

### Palabras clave:

Pulmonar  
Endometriosis  
Hemoptisis  
Cirugía

## Introduction

Extrauterine endometriosis was first described by Maurer et al. in 1958.<sup>1</sup> It is defined as endometrial growth outside the uterine cavity or myometrium.<sup>2</sup> Thoracic endometriosis can produce various symptoms, depending on how it affects the parenchyma or pleura. Parenchymal endometriosis does not cause clinical symptoms in every menstrual cycle and hemoptysis is more likely to be intermittent.

We present 2 cases of endometriosis managed with surgical intervention.

## Clinical Observation

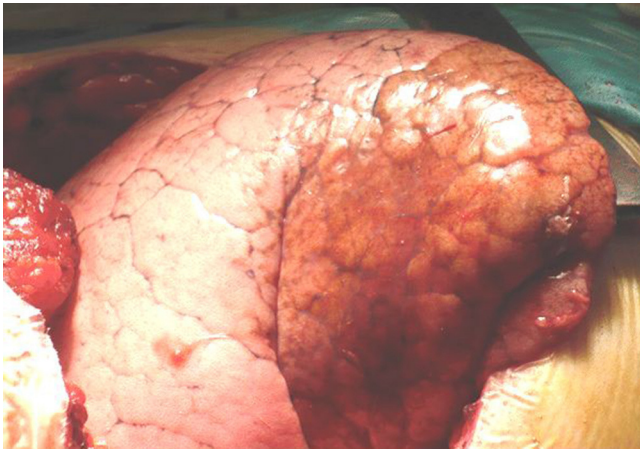
### Case 1

A forty-two-year-old woman with 3 children presented in our clinic with a 2-year history of intermittent hemoptysis. Computed tomography (CT) revealed a 16 mm × 11 mm cavitated lesion with thick, irregular walls in the lower lobe of the right lung. CT was repeated during menstruation in order to determine any association between hemoptysis and the menstrual cycle. The initial lesion was still visible, and in addition, ground-glass opacity was identified in the surrounding parenchymal tissue. Bronchoscopy revealed bloody secretions in the basal lung segments with no endobronchial lesion. In view of these data, an exploratory thoracotomy was performed. A reddish-brown lesion with an irregular surface and rubbery consistency was found in a prism-shaped area of the visceral pleura of the basal segments of the right lower lobe (Fig. 1). A basal segmentectomy was performed. The definitive pathological

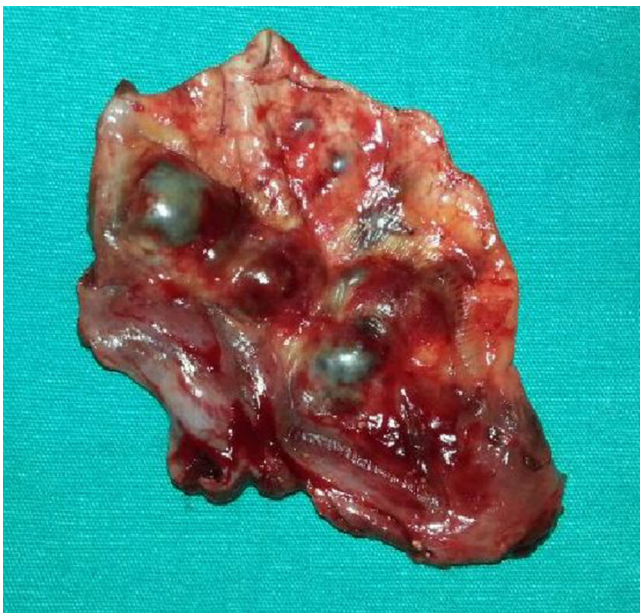<sup>☆</sup> Please cite this article as: Ucvet A, Sirzai EY, Yakut FC, Yoldas B, Gursoy S. Endometriosis pulmonar torácica: presentación de 2 casos de una enfermedad muy poco frecuente. Arch Bronconeumol. 2014;50:454–455.

\* Corresponding author.

E-mail address: banuaktin@yahoo.com (B. Yoldas).



**Fig. 1.** Intraoperative image of lesion in the lower lobe of the right lung.



**Fig. 2.** Endometriotic foci on the diaphragm surface and gross image of the resected piece.

diagnosis was “endometrial tissue in the lung parenchyma, suggestive of pulmonary endometriosis”. Three years after the procedure, the patient remains free of symptoms and has had no relapse.

#### Case 2

A thirty-year-old childless patient presented in our clinic with localized right chest pain. She reported a history of 2 episodes of pneumothorax in one year. A detailed interview revealed that these episodes were related with the patient’s menstrual cycles. Chest CT showed right pneumothorax. In view of the patient’s history, an irregularity in the right diaphragm was thought to be suggestive of endometriosis. She underwent axillary thoracotomy for the

recurrent pneumothorax revealing several foci on the diaphragm during the examination. This area was fully resected and frozen slices were found to indicate endometriosis (Fig. 2). In this case too, the definitive diagnostic report was “endometrial tissue suggestive of endometriosis”.

#### Discussion

Endometriosis is thought to affect 5%–15% of women of child-bearing age. Pelvic and extraperitoneal endometriosis is very rare.<sup>2</sup> Symptoms are generally site-dependent, and consist primarily of pneumothorax, followed by hemothorax, hemoptysis and lung nodules.<sup>3</sup> In our first patient, symptoms were periodical (but did not appear in every cycle), suggesting a greater likelihood of parenchymal endometriosis.

The etiology of pulmonary endometriosis is not well defined. Accepted hypotheses include coelomic metaplasia during fetal life, lymphogenous and hematogenous embolization of the pelvic organs after uterine surgery or childbirth and transdiaphragmatic migration of endometrial tissue.

Radiological features include nodules, thick-wall cavities, ground-glass opacities or pulmonary blebs.<sup>4</sup>

Histopathological evaluation is essential for a definitive diagnosis. Endometriotic foci have varying proportions of stroma and normal or ectatic glandular structure, largely encased in a multi-stratified cylindrical epithelial structure. Glandular epithelium has been shown to be covered with anti-cytokeratin 7 antibodies and Ber-EP4 antibodies.<sup>5</sup> In both cases, the lesions with their borders were enhanced by the CD10 used for staining ectopic endometrial tissue.

Hemosiderin-laden macrophages may sometimes be observed in bronchoscopy aspirate. The diagnosis is mainly confirmed on surgery. If clinical and radiological diagnosis is possible, hormone treatment may be attempted with danazol and GnRH analogs, but the relapse rate<sup>3</sup> suggests that medical treatment should be combined with surgical intervention.<sup>4</sup>

During surgery, it is important to preserve the parenchyma as far as possible, while resecting as much gross pathological tissue as possible. However, in most cases a lobectomy is performed.<sup>3</sup> In our first patient, we chose to protect the upper segment of the lower lobe that was unaffected by the lesion.

To conclude, pulmonary endometriosis, while very rare, should be considered in women of childbearing age with intermittent hemoptysis and pneumothorax. Exploratory methods, including surgical intervention, must be used to obtain a definitive histopathological diagnosis.

#### References

1. Maurer ER, Schaal JA, Mendez FL. Chronic recurring spontaneous pneumothorax due to endometriosis of the diaphragm. *JAMA*. 1958;168:2013–4.
2. Brosens I, Puttemans P, Campo R, Gordts S, Brosens J. Non-invasive methods of diagnosis of endometriosis. *Curr Opin Obstet Gynecol*. 2003;15:519–22.
3. Joseph J, Sahn SA. Thoracic endometriosis syndrome: new observations from an analysis of 110 cases. *Am J Med*. 1996;100:164–70.
4. Alifano M, Trisolini R, Cancellieri A, Regnard JF. Thoracic endometriosis: current knowledge. *Ann Thorac Surg*. 2006;81:761–9.
5. Flieder DB, Moran CA, Travis WD, Koss MN, Mark EJ. Pleuro-pulmonary endometriosis and pulmonary ectopic deciduosis: a clinicopathologic and immunohistochemical study of 10 cases with emphasis on diagnostic pitfalls. *Hum Pathol*. 1998;29:1495–503.