



ARCHIVOS DE BRONCONEUMOLOGIA

www.archbronconeumol.org



Case Report

Organizing Pneumonia Associated with the Use of Trastuzumab

Álvaro Taus-García,^a Albert Sánchez-Font,^{b,*} Sònia Servitja-Tormo,^a Lara Pijuan,^c José María Maiques-Llácer,^d and Víctor Curull^b

^aServei d'Oncologia Mèdica, Hospital del Mar-IMIM, Universitat Autònoma de Barcelona, Universitat Pompeu Fabra, Barcelona, Spain

^bServei de Pneumologia, Hospital del Mar-IMIM, Universitat Autònoma de Barcelona, Universitat Pompeu Fabra, CIBER de Enfermedades Respiratorias (CibeRes), Barcelona, Spain

^cServei d'Anatomia Patològica, Hospital del Mar-IMIM, Universitat Autònoma de Barcelona, Universitat Pompeu Fabra, Barcelona, Spain

^dServei de Radiodiagnòstic, Hospital del Mar-IMIM, Universitat Autònoma de Barcelona, Universitat Pompeu Fabra, Barcelona, Spain

ARTICLE INFO

Article history:

Received September 16, 2009

Accepted September 19, 2009

Keywords:

Organizing pneumonia

Trastuzumab

Herceptin®

Breast cancer

ABSTRACT

Organizing pneumonia is a clinical and histological condition in which the onset is usually subacute with respiratory symptoms and pulmonary infiltrates. It may be unknown origin (cryptogenic) or associated with other illnesses, infectious diseases or drugs. We present a 60 year-old female patient with a previous history of breast cancer, who was being treated with trastuzumab, an antiHER2 monoclonal antibody. She was diagnosed with casual pulmonary infiltrates that had histological changes compatible with organizing pneumonia. The pulmonary infiltrates disappeared on withdrawing trastuzumab treatment. Due to the increasing use of biological therapies in different medical areas, we believe it is of interest to report this pulmonary involvement attributed to the monoclonal antibody trastuzumab.

© 2009 SEPAR. Published by Elsevier España, S.L. All rights reserved.

Neumonía organizada asociada a tratamiento con trastuzumab

RESUMEN

La neumonía organizada es una entidad clinicohistológica que suele manifestarse de forma subaguda con clínica respiratoria e infiltrados pulmonares. Puede ser de causa desconocida (criptogénica) o estar asociada a distintas enfermedades, infecciones o fármacos. Presentamos el caso de una paciente de 60 años con antecedentes de una neoplasia de mama, motivo por el cual seguía tratamiento con trastuzumab, un anticuerpo monoclonal anti-HER2, a quien se detectó de forma casual un infiltrado pulmonar, cuya biopsia transbronquial fue diagnóstica de neumonía organizada. Tras la retirada del fármaco desapareció el infiltrado pulmonar. Debido a la creciente utilización de la terapia biológica en diferentes campos de la clínica, nos parece de interés comunicar esta forma de afectación pulmonar atribuible al anticuerpo monoclonal trastuzumab.

© 2009 SEPAR. Publicado por Elsevier España, S.L. Todos los derechos reservados.

Palabras clave:

Neumonía organizada

Trastuzumab

Herceptin®

Cáncer de mama

Introduction

Organising pneumonia is a clinico-histological condition that may occur in connection with the administration of certain medicines.

Trastuzumab (Herceptin®) is a monoclonal antibody directed against the extracellular domain of the HER2 protein, which is responsible for the activity of tyrosine and is overexpressed in up to 25% of infiltrating breast carcinomas. In the case described below, we demonstrate the association between treatment with trastuzumab and the appearance of organising pneumonia in a patient with a history of breast cancer.

*Corresponding author.

E-mail address: asanchezf@imas.imim.es (A. Sánchez-Font).

Clinical Observation

The patient is a 60-year old woman, with no known medicine allergies or toxic habits and with a history of arterial hypertension, dyslipidaemia and bronchial asthma. Following the diagnosis in October 2006 of a right breast tumour, the patient underwent lumpectomy and axillary lymphadenectomy. The result of the anatomical pathology study revealed a 15x11x10 mm, grade-2 infiltrating ductal carcinoma, with only one axillary lymph node involved of the 15 isolated nodes. The immunohistochemical study showed positive oestrogen and progesterone receptors and an amplification and polysomy of the HER2 by in situ fluorescent hybridisation. Following the extension study, the case was classified as pT1c pN0 M0, and the patient was considered suitable for adjuvant treatment. Between November and March 2007, she received 6 cycles of intravenous cytostatic treatment every 21 days, according to the following scheme: docetaxel + doxorubicin + cyclophosphamide. Subsequently, between April and June 2007, she received irradiation on the right breast with 6 MV photons (a fractionation of 2 Gy per session), up to a total dose of 48 Gy, and a surgical boost of 68 Gy. The only complication observed was grade-2 dermatitis that was cured with topical treatment. In August 2007, the patient began treatment with trastuzumab at an initial dose of 8 mg/kg, followed by 6 mg/kg every 21 days. In January 2008, she underwent a chest X-ray following signs suggesting bronchial infection, which showed a 17 mm nodule in the upper lobe of the right lung. This was subsequently confirmed through a computed tomography (CT) of the chest. Approximately one month later, she repeated the plain chest radiography and soon after, the chest CT scan (fig. 1), which showed peripheral condensation, with small areas of cavitation surrounded by ground-glass opacities and fibrotic-looking pleuropulmonary tracts. As such, all these, were indicative of organising pneumonia. The patient was asymptomatic at that time. Fiberoptic bronchoscopy showed normal endobronchial levels, the microbiological cultures for bacteria and mycobacteria were negative and the cytologies showed no malignant cells. The bronchoalveolar lavage showed 59% of lymphocytes, with a predominance of CD4 (71%), and 10% neutrophils, while the transbronchial biopsy revealed intra-alveolar fibroblastic proliferation, which was indicative of a histologic pattern of organising pneumonia (fig. 2). After suspecting organising pneumonia secondary to trastuzumab, it was decided to discontinue the said treatment after the patient had received 11 cycles for 7 months. Following the discontinuance of the medicine, the pulmonary infiltrate was reduced progressively until it completely disappeared in May 2008. Following a 14-month follow-up, the patient was asymptomatic, with no evidence of neoplastic disease or parenchymal

lung disease. The nodular lesion, the study of which led to these findings, showed no uptake in the positron emission tomography. In addition, it was found that this above-mentioned lesion already existed in previous radiographs of the patient's diagnosis of breast cancer.

Discussion

Organising pneumonia (formerly known as bronchiolitis obliterans organising pneumonia) is characterised by the presence of subacute clinical manifestations (cough, dyspnoea and fever), together with alveolar and/or interstitial pulmonary infiltrates (sometimes migratory and even recurrent). The establishment of the safety diagnosis requires the demonstration of foci of organising pneumonia in transbronchial or surgical biopsy samples, accompanied by a compatible clinico-radiological profile. Organising pneumonia may be idiopathic or associated with collagenoses, infections, administration of medicines (bleomycin, ergot derivatives, nitrofurantoin, phenytoin, amiodarone, carbamazepine and cyclophosphamide) or radiotherapy.¹⁻⁴ The chest radiograph shows images of unilateral or bilateral consolidation, at times migratory and recurrent, although in some cases the images are nodular or

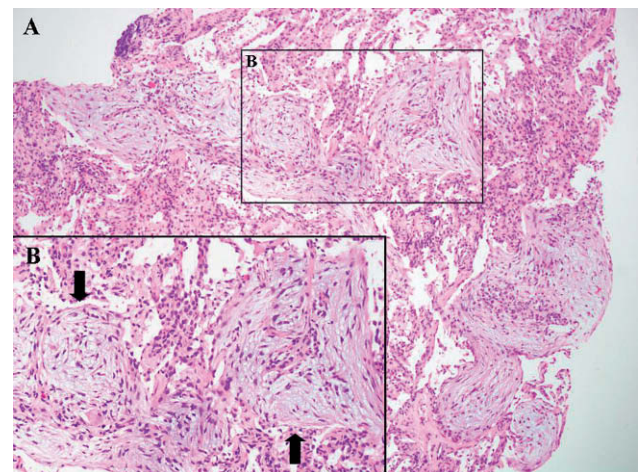


Figure 2. Transbronchial biopsy obtained by fiberoptic bronchoscopy, showing peribronchial lung parenchyma with intra-alveolar fibroblastic proliferation (arrows), which is indicative of a histologic pattern of organising pneumonia. A: haematoxylin-eosin ($\times 10$ magnification). B: haematoxylin-eosin ($\times 20$ magnification).

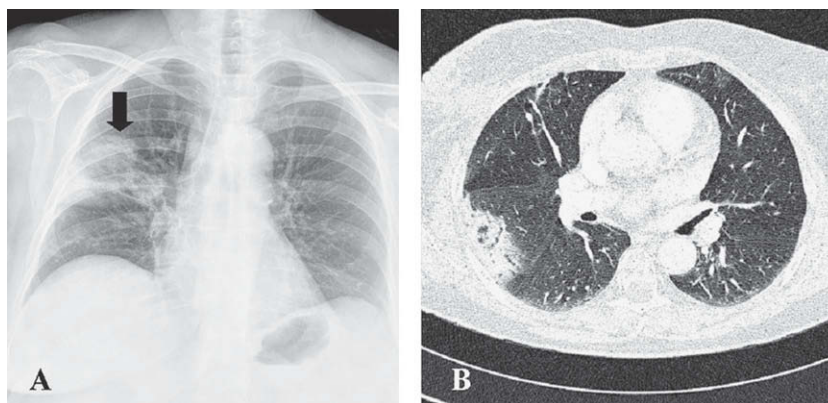


Figure 1. A. plain chest radiography (posteroanterior projection), showing a solitary pulmonary nodule and an area of consolidation in the upper right lobe (arrow). B. Axial section of a chest CT scan of the lung, showing peripheral condensation, with small areas of cavitation surrounded by ground-glass opacities.

reticulonodular. The diagnosis is guided by the finding of areas of pulmonary consolidation of subpleural or peribronchial distribution on the chest CT scan, as well as the finding of lymphocytosis in the bronchoalveolar lavage, which is often associated with neutrophilia and/or eosinophilia, together with an inversion ratio of the quotient for T CD4⁺/CD8⁺ lymphocytes.¹

At present, the therapeutic methods used in breast cancer include surgery, chemotherapy, radiotherapy, hormonal therapy and biological therapy. The therapy performed using monoclonal antibodies against the HER2 membrane receptor has shown significant benefits in patients with a high expression of this receptor.

The HER2 protein belongs to a family of 4 transmembrane receptors with tyrosine activity, which regulate the proliferation, differentiation and survival of cells.^{5,6} The overexpression of the HER2 protein or the amplification of the *HER2/neu* gene occur in 20% to 25% of infiltrating breast carcinomas,^{7,8} and they are associated with a more aggressive tumour behaviour, with a higher recurrence rate and a lower relapse-free interval following adjuvant chemotherapy.⁷ Trastuzumab (Herceptin®) is a humanised monoclonal antibody directed against the extracellular domain of the HER2 protein. The binding on the HER2 receptor prevents the receptor's dimerisation and blocks the activation of the signalling routes, thereby inhibiting the proliferation and survival of cells. The use of trastuzumab has been extended to the HER2-positive population both in metastatic disease therapy and in adjuvant and neoadjuvant therapies, and it improves overall survival and relapse-free survival. Trastuzumab is generally a well-tolerated medicine, but not without side effects. The most important toxicity is the cardiac one, mainly in the form of congestive heart failure, which reverts following drug's discontinuance. This occurs in approximately 4.5% of the cases and requires monitoring of the cardiac function before and during treatment. Additionally, although rarely, pulmonary toxicity has also been described.⁸ In 2003, the first case of organising pneumonia associated with the treatment of trastuzumab was described,⁹ and to date, we do not know of any other publications.

In our case, the association of the pulmonary disease with trastuzumab presented by the patient would be likely to occur, in accordance with the traditional criteria to consider an adverse reaction to a medicine. Thus, to define the reaction as certain, we would require the recurrence of organising pneumonia following the

re-exposure to this drug,¹⁰ a fact which was not contemplated due to ethical considerations. As described in recently published articles, Rituximab, another monoclonal antibody, has also been associated with organising pneumonia.^{11,12} Regarding the possible role of radiotherapy in the development of organising pneumonia, this complication is documented in the medical literature.¹³ In our case, the months between its completion and the appearance of the lesions reasonably dispel radiotherapy as a cause of lung disease.

With the increasing use of biological treatment in different clinical areas, it would not be surprising to see more cases reported in the medical literature in the coming years. It therefore seems important that we communicate this adverse pulmonary reaction in the form of organising pneumonia.

References

1. Xaubet A, Ancochea J, Blanquer R, Montero C, Morell F, Rodríguez Becerra E, et al. Diagnóstico y tratamiento de las enfermedades pulmonares intersticiales difusas. *Arch Bronconeumol.* 2003;39:580-600.
2. American Thoracic Society; European Respiratory Society. American Thoracic Society/European Respiratory Society international multidisciplinary consensus classification of the idiopathic interstitial pneumonias. *Am J Respir Crit Care Med.* 2002;165:277-304.
3. Camus PH, Foucher P, Bonniaud PH, Ask K. Drug-induced infiltrative lung disease. *Eur Respir J Suppl.* 2001;32:93S-100S.
4. The Drugs-Induced Lung Diseases. Available from: <http://www.pneumotox.com>.
5. Yarden Y, Sliwkowski MX. Untangling the ErbB signalling network. *Nat Rev Mol Cell Biol.* 2001;2:127-37.
6. Gschwind A, Fischer OM, Ullrich A. The discovery of receptor tyrosine kinases: targets for cancer therapy. *Nat Rev Cancer.* 2004;4:361-70.
7. Slamon DJ, Clark GM, Wong SG. Human breast cancer: correlation of relapse and survival with amplification of the *HER-2/neu* oncogene. *Science.* 1987;235:177-82.
8. Vahid B, Mehrotra A. Trastuzumab (Herceptin)-associated lung injury. *Respirology.* 2006;11:655-8.
9. Radzikowska E, Szczepulska E, Chabowski M, Bestry I. Organising pneumonia caused by trastuzumab (Herceptin) therapy for breast cancer. *Eur Respir J.* 2003;21:552-5.
10. Irey NS. Teaching monograph. Tissue reactions to drugs. *Am J Pathol.* 2006;82:613-47.
11. Soubrier M, Jeannin G, Kemeny JL, Tournadre A, Caillot N, Caillaud D, et al. Organizing pneumonia after rituximab therapy: two cases. *Joint Bone Spine.* 2008;75:362-5.
12. Lioté H, Lioté F, Séroussi B, Mayaud C, Cadranet J. Rituximab-induced lung disease: a systematic literature review. *Eur Respir J.* In press 2009.
13. Akita K, Ikawa A, Shimizu S, Tsuboi K, Ishihara K, Sato S, et al. Cryptogenic organizing pneumonia after radiotherapy for breast cancer. *Breast Cancer.* 2005;12:243-7.