

Clinical Letter

**Organizing Pneumonia Caused by Letrozole Therapy for Breast Cancer: A Case Report**

To the Director,

Organizing pneumonia (OP) is characterized by inflammation and scarring of peripheral airways and alveolar sacs. OP may be associated with autoimmune diseases, pulmonary infections, radiotherapy, adverse drug reactions and bone marrow transplantation. However, many cases OP are considered cryptogenic.<sup>1</sup>

OP is characterized by pneumonia-like symptoms such as subfebrile state, cough, and dyspnoea. High-resolution computed tomography (HRCT) usually reveals multifocal areas of consolidation often migratory.<sup>1</sup>

Drug-induced OP includes antibacterials, kinase inhibitors, checkpoints inhibitors, antineoplastic and biologic agents.<sup>1</sup> Some OP occurred as a side effect of medications used in the treatment of breast cancer including some aromatase inhibitors<sup>2,3</sup> and cyclin-dependent kinase 4/6 inhibitor.<sup>4</sup> Letrozole is used in the treatment of hormone receptor-positive breast cancer. Pulmonary toxicities have been rarely reported.<sup>5</sup> We herein report a case of OP in a patient treated with letrozole.

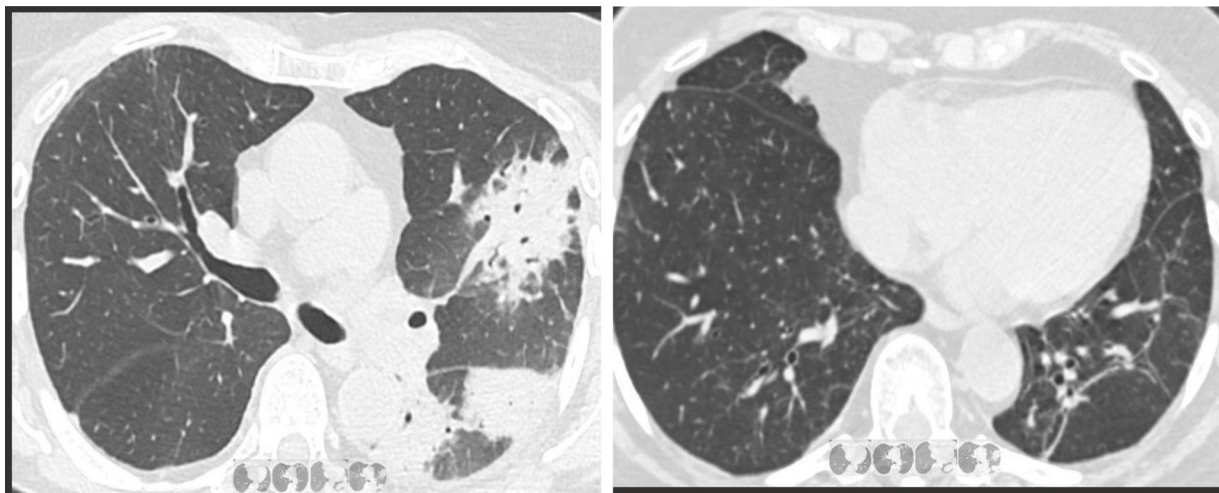
A 73-year-old, female with moderate asthma, underwent breast-conserving surgery for adenocarcinoma of the left breast, with oestrogen and progesterone receptors positive and human epidermal growth factor receptor 2-negative. Radiotherapy was applied on the post-resectional area (total dose 40 Gy). Having finished radiotherapy letrozole was initiated. After 6 months of treatment, she began experiencing dry cough and dyspnoea. A

chest radiograph showed a patchy area of air space consolidation in the right middle lobe. All routine serological and microbiologic studies were negative. Treatment with amoxicillin was initiated, but without any significant effect. The HRCT revealed the presence of airspace consolidations in upper lobes and lower left lobe and some diffuse bronchial dilatations. She was treated with ciprofloxacin and a short course of oral prednisone. There was an initial improvement in clinical symptoms; however dry cough and dyspnoea developed again with the decrease of oral prednisone dose.

The patient was referred to our hospital for further studies. Clinical symptoms and examination were like previously reported. Routine serological/microbiological examinations were negative. The HRCT showed multiple patchy foci of air consolidation distributed peripherally and bronchial dilatations in the left lung, all of them compatible with OP (Fig. 1). The results of fibrobronchoscopy with transbronchial biopsy revealed histological findings suggestive of OP.

The clinical history, radiographic examinations and pathological findings support the diagnosis of OP and suggest a role for breast cancer therapy.

A decision was made to temporarily discontinue treatment with letrozole, which was replaced by tamoxifen. Oral treatment with oral corticosteroids (60 mg prednisone) tapered over 2 months. There was a rapid improvement of symptoms and progressive clearance of pulmonary densities on the radiographs. A HRCT taken 8 months later showed total regression of pulmonary densities except for some reticular lines and bronchial dilatations in the left lower lobe.



**Fig. 1.** Airspace consolidations, bronchial thickening and bronchial dilatations (left). Eight months later showed total regression of pulmonary densities with some reticular lines and bronchial dilatations in the left lower lobe (right).

<https://doi.org/10.1016/j.arbres.2025.01.016>

0300-2896/© 2025 SEPAR. Published by Elsevier España, S.L.U. All rights are reserved, including those for text and data mining, AI training, and similar technologies.

Because migratory OP is an event considered exceptional after post-resection radiotherapy for breast cancer,<sup>2</sup> together with the complete cured of the process after stopping treatment with letrozole, allows us to reasonably rule out that radiotherapy could be responsible for the OP in this patient. Although the potential additive effect of letrozole and radiotherapy cannot be completed excluded, the cure of the process following letrozole withdrawal supports the central role play by the drug.

### Artificial Intelligence Involvement

The material has not been partially or totally produced with the help of any artificial software or tool.

### Funding

The authors of this clinical letter did not receive any grant.

### Conflicts of Interests

The authors declare not to have any conflicts of interest.

### References

1. Radzikowska E, Fijolek J. Update on cryptogenic organizing pneumonia. *Front Med (Lausanne)*. 2023;10:1146782.

2. Oie Y, Saito Y, Kato M, Ito F, Hattori H, Toyama H, Kobayashi H, Katada K. Relationship between radiation pneumonitis and organizing pneumonia after radiotherapy for breast cancer. *Radiat Oncol*. 2013;8:56.
3. Radzikowska E, Szczepulska E, Chabowski M, Bestry I. Organising pneumonia caused by trastuzumab (Herceptin) therapy for breast cancer. *Eur Respir J*. 2003;21:552–5.
4. Okayasu K, Kawasaki T, Kumagai J, Miyazaki Y. Clinicoradiological course of abemaciclib-induced pneumonitis with histology findings. *BMJ Case Rep*. 2023;16:e254349.
5. Alekhya Bukkuri S, Mayo-Malasky H, Pillai M. Letrozole-induced organising pneumonia: a case report. *Chest*. 2023;164:A3202.

César Picado<sup>a,b,c,\*</sup>, Nestor Soler<sup>a,b,c</sup>

<sup>a</sup> *Department of Respiratory Diseases, Hospital Clinic, Universitat de Barcelona, Barcelona, Spain*

<sup>b</sup> *Institut d'Investigacions Biomèdiques August Pi I Sunyer (IDIBAPS), Barcelona, Spain*

<sup>c</sup> *Centro de Investigaciones Biomédicas en Red de Enfermedades Respiratorias (CIBERES), Madrid, Spain*

Corresponding author.

E-mail address: [cpicado@ub.edu](mailto:cpicado@ub.edu) (C. Picado).