

Clinical Letter

Negative Pressure Pulmonary Edema Due to Severe Bronchospasm

To the Director,

A 44-year-old woman without history of cardiovascular disease, with severe eosinophilic allergic bronchial asthma went to the emergency room due to a severe exacerbation of her asthma, where bronchodilator treatment, corticosteroid therapy (prednisone 40 mg and hydrocortisone 200 mg), magnesium sulfate 2 g, diazepam 5 mg, morphine chloride 2 mg, nebulization of adrenaline and lidocaine was started. At 1 h she presented improvement in bronchospasm, although she persisted with dyspnea, tachypnea, and tachycardia. Initial arterial blood gas analysis revealed respiratory alkalosis, pH 7.54, pCO<sub>2</sub> 20 mmHg, and pO<sub>2</sub> 78 mmHg. She was transferred to the intensive care unit (ICU) due to persistent tachypnea, where she was started on non-invasive ventilation (NIV), which was poorly tolerated and was withdrawn after a few minutes. She remained with a Venturi mask. Analysis showed 12,300 leukocytes/microliter, CRP 21 mg/l, normal kidney function. Chest X-ray on admission without pulmonary condensation or congestive signs. PCR respiratory viruses detected Rhinovirus. A few hours after her admission to the ICU, she presented persistent bronchospasm with basal crackles at auscultation that was treated with bronchodilators and corticosteroid therapy. The chest X-ray showed signs of pulmonary congestion. Acute lung edema was suspected, so furosemide 40 mg was added. The NTproBNP value was 183 pg/ml, the transthoracic echocardiogram was normal. The patient showed progressive clinical improvement after 24 h and the control chest X-ray showed resolution of the congestive pattern (Fig. 1). She was transferred to the Pulmonology ward and was able to withdraw oxygen upon discharge. The case was diagnosed as non-cardiogenic pulmonary edema due to negative pressure.

Negative pressure pulmonary edema (NPPE) is caused by increased intrathoracic negative pressure after inspiration against the obstructed upper airway, occurring in 0.1% of patients, especially in the field of Anesthesiology.<sup>1,2</sup> Negative intrathoracic pressure is transmitted to the interstitium and pulmonary capillaries, overcoming the hydrostatic balance, causing extravasation of fluid into the lung parenchyma and alveoli.<sup>1-3</sup> NPPE was first described in 1927; the first case was reported in 1973.<sup>1</sup> Two types of NPPE are described, type I is associated with a forced inspiratory effort due to an acute obstruction of the airways, such as laryngospasm, epiglottitis, among others.<sup>3</sup> Type II NPPE occurs after relief of chronic partial upper airway obstruction, such as after tonsillectomy.<sup>3</sup> In our case, NPPE is included in type I, secondary to severe bronchospasm defined as the narrowing of the airway due to the sustained contraction of the bronchial muscles.<sup>5</sup>

Few cases of NPPE related to bronchospasm have been described. Krodel et al., describe NPPE due to bronchospasm in

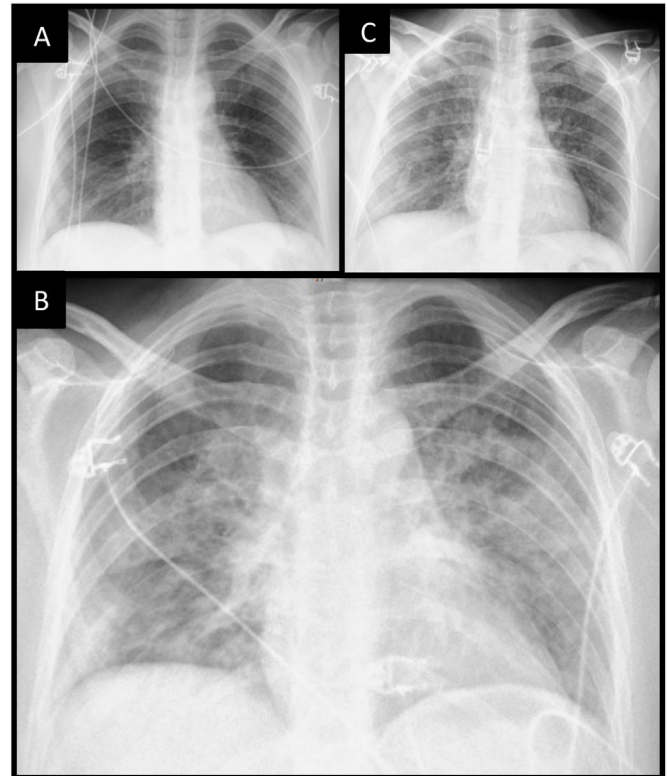


Fig. 1. (A) Chest X-ray upon admission with normal characteristics. (B) Chest X-ray after admission to IUC at 24 h with alveolar pattern suggestive of acute lung edema. (C) Chest X-ray at 72 h with resolution of the acute lung edema pattern.

the immediate postoperative period of a cervicectomy, which was resolved with NIV and furosemide. The patient had a history of asthma and COPD.<sup>4</sup> Jo et al., describe another case of NPPE due to bronchospasm, in the immediate postoperative period from a gastrectomy, which they treated with epinephrine, furosemide, and invasive mechanical ventilation.<sup>5</sup> Most cases occur within minutes of severe upper airway obstruction or relief (between 3 and 150 min).<sup>1</sup> Resolution after adequate treatment is usually rapid, without residual effects.<sup>1,2</sup> Treatment is conservative with depletives such as furosemide which reduces lung congestion; maintain a patent airway and supplemental oxygen, rarely mechanical ventilation.<sup>2</sup>

During an asthma exacerbation, the appearance of bibasilar crackles together with a radiographic pattern suggestive of acute pulmonary edema with a normal echocardiogram should make us suspect NPPE.

We describe the first case secondary to severe bronchospasm without a postoperative period. NPPE may be a complication of

<https://doi.org/10.1016/j.arbres.2024.12.007>

0300-2896/© 2024 SEPAR. Published by Elsevier España, S.L.U. All rights are reserved, including those for text and data mining, AI training, and similar technologies.

severe asthma exacerbation that requires early suspicion and identification for appropriate treatment.

### Informed Consent

Informed consent was obtained from the patient for the publication of his clinical data and the use of diagnostic images.

### Conflict of Interests

None declared.

### References

1. Rasheed A, Palaria U, Rani D, Sharma S. A case of negative pressure pulmonary edema in an asthmatic patient after laparoscopic cholecystectomy. *Anesth Essays Res.* 2014;8:86–8, <http://dx.doi.org/10.4103/0259-1162.128919> [PMID: 25886111; PMCID: PMC4173589].
2. Bhattarai B, Shrestha S. Negative pressure pulmonary edema – case series and review of literature. *Kathmandu Univ Med J (KUMJ).* 2011;9:310–5, <http://dx.doi.org/10.3126/kumj.v9i4.6352> [PMID: 22710546].
3. Udeshi A, Cantie SM, Pierre E. Postobstructive pulmonary edema. *J Crit Care.* 2010;25, <http://dx.doi.org/10.1016/j.jcrc.2009.12.014>, 508.e1-5 [Epub 22.04.10; PMID: 20413250].
4. Krodel DJ, Bittner EA, Abdunour RE, Brown RH, Eikermann M. Negative pressure pulmonary edema following bronchospasm. *Chest.* 2011;140:1351–4, <http://dx.doi.org/10.1378/chest.11-0529> [PMID: 22045880].
5. Jo YY, Kim KH, Kil HK. Negative pressure pulmonary edema related to bronchospasm during anesthetic recovery. *Korean J Anesthesiol.* 2013;65:91–2, <http://dx.doi.org/10.4097/kjae.2013.65.1.91> [PMID: 23904949; PMCID: PMC3726858].

Alan Jhunior Solis Solis<sup>a,\*</sup>, Carlos Martinez Rivera<sup>a</sup>,  
Fernando Armestar Rodriguez<sup>b</sup>

<sup>a</sup> *Department of Pulmonology, Hospital Universitari Germans Trias i Pujol, Spain*

<sup>b</sup> *Intensive Care Department, Hospital Universitari Germans Trias i Pujol, Spain*

Corresponding author.

E-mail address: [alanjhuniorolis@gmail.com](mailto:alanjhuniorolis@gmail.com) (A.J. Solis Solis).