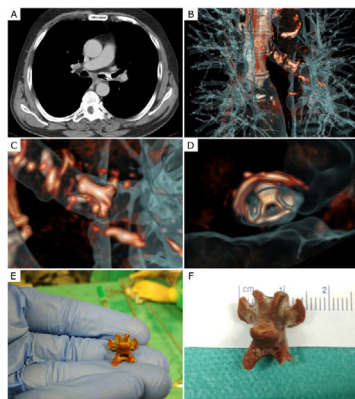


## Clinical Image

# Difficult Diagnosis of a Foreign Body Inhalation in a COPD Patient

Pedro Pereira Barros\*, Bruno dos Santos, Ulisses Brito

Centro Hospitalar Universitário do Algarve – Hospital de Faro, Portugal



**Fig. 1.** (A) Chest CT (axial plan): a perforated foreign body in the left main bronchus; (B) 3D CT reconstruction showing the bronchial tree and a perforated foreign body in the left main bronchus; (C) 3D CT reconstruction showing a perforated foreign body in the left main bronchus; (D) 3D CT reconstruction showing a perforated foreign body in the left main bronchus; (E) Foreign body compatible to a chicken's vertebra; (F) Foreign body compatible to a chicken's vertebra, measuring 1.5 cm × 1.5 cm.

61-Year-old male, former smoker, medical history of chronic obstructive pulmonary disease GOLD 3B. In the outpatient follow-up, the patient had complaints of stridor, dysphonia, and precordial oppression, while denying any choking episode. After

otorhinolaryngology observation, no alterations were seen in the laryngoscopy. In the next clinical evaluation, there was a worsening of the patient's dysphonia and dyspnea. The chest X-ray showed bilateral diffuse basal and perihilar infiltrates. Subsequently, chest CT revealed the presence of a perforated foreign body in the left main bronchus, partially obstructing it (Fig. 1 – A–D). A Rigid Bronchoscopy was performed, where the foreign body was found and removed. It was compatible with a chicken's vertebra, measuring 1.5 cm × 1.5 cm (Fig. 1 – E and F).

This case highlights the importance of a detailed investigation in the presence of unexpected symptoms in COPD and other lung diseases. The foreign body observed in this case is peculiar, and it was lodged in the left bronchial tree as opposed to the right bronchial tree, the most frequent location described in the literature.<sup>1</sup>

## Funding

No funders pertaining to this article.

## Reference

1. Sehgal IS, Dhooria S, Ram B, Singh N, Aggarwal AN, Gupta D, et al. Foreign body inhalation in the adult population: experience of 25,998 bronchoscopies and systematic review of the literature. *Respir Care*. 2015;60:1438–48. <http://dx.doi.org/10.4187/respcare.03976>.

\* Corresponding author.  
E-mail address: [pedro34621@gmail.com](mailto:pedro34621@gmail.com) (P. Pereira Barros).