

Clinical Image

Cyclic Sternocleidomastoid Contraction: An Unusual Finding in a Conventional Polysomnography



Paula Fernández Martínez^a, Estrella Caballeria Lamelas^b, Mireia Dalmases Cleries^{b,c,d,*}

^a Department of Pulmonary Medicine, Complejo Asistencial de Burgos, Burgos, Spain

^b Sleep Unit, Department of Pulmonary Medicine, Hospital Clínic de Barcelona, Barcelona, Spain

^c Institut d'Investigacions Biomèdiques August Pi i Sunyer (IDIBAPS), Barcelona, Spain

^d Centro de Investigación Biomédica en Red de Enfermedades Respiratorias (CIBERES), Madrid, Spain

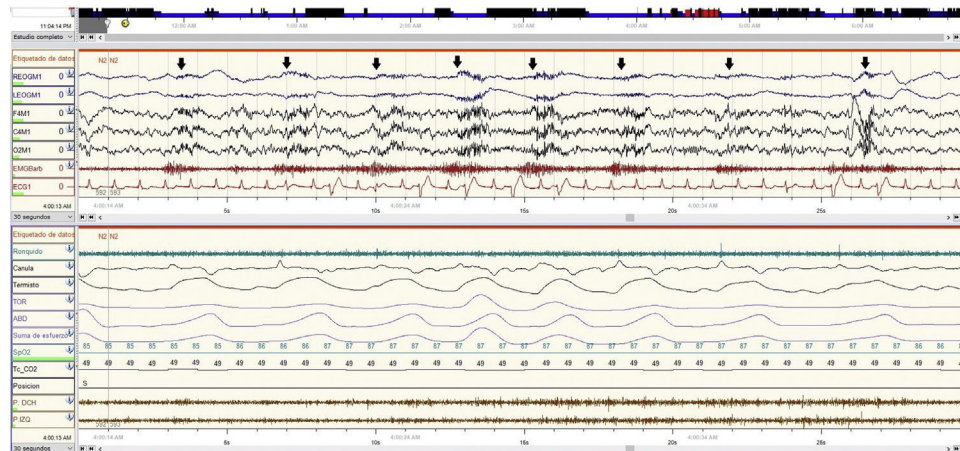


Fig. 1. A 30-second epoch of PSG-C (EEG (F4-M1, C4-M1, O2-M1), EOG (E1-M1, E2-M1), EMG and electrocardiogram) showing (arrows) the cyclical contractions in the chin EMG visible in the EEG/EOG derivations. The contractions coincide with the inspiration.

A 52-year-old woman with severe restrictive lung disease and dilated cardiomyopathy secondary to nemaline myopathy¹ was referred to the Sleep Unit for night choking and snoring. She presented dyspnea on minimal exertion and in the supine position. A conventional polysomnography (PSG-C) with percutaneous capnography was performed.

The study showed moderate obstructive sleep apnoea, premature ventricular contractions and an increase in PtCO₂ from 39 to 51 mmHg. We observed cyclic activations in the chin electromyogram (EMG) and a simultaneous artifact in the electroencephalogram (EEG) and electrooculogram (EOG) derivations (Fig. 1).

The cyclic muscle activity in the EMG/EEG/EOG channels corresponds to the contraction of the sternocleidomastoid muscle in a patient with severe restrictive lung disease who needs to use accessory respiratory muscles. The sternocleidomastoid muscle has an insertion in the mastoid process, thus near the location of the

referential electrode (M1) in a PSG-C.² Its excessive activation in this patient is the reason why the contraction becomes visible in the EEG and EOG derivations that were also referred to the same electrode.

Conflict of interest

The authors declare to have no conflict of interest.

References

1. Sewry CA, Laitila JM, Wallgren-Pettersson C. Nemaline myopathies: a current view. *J Muscle Res Cell Motil.* 2019;40:111–26. <http://dx.doi.org/10.1007/s10974-019-09519-9>.
2. Berry RB, Quan SF, Abreu AR, et al., for the American Academy of Sleep Medicine. *The AASM Manual for the Scoring of Sleep and Associated Events: Rules, Terminology and Technical Specifications. Version 2.6.* Darien, IL: American Academy of Sleep Medicine; 2020.

* Corresponding author.
E-mail address: mdalmase@clinic.cat (M. Dalmases Cleries).