

## Clinical Image

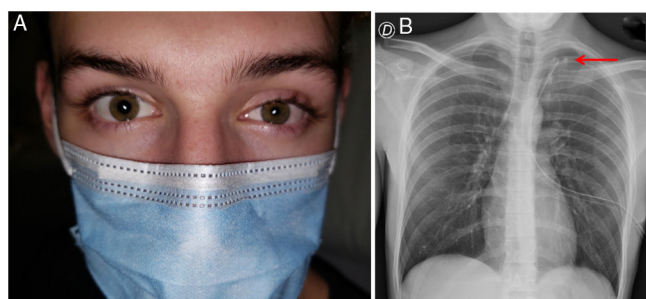
### Horner Syndrome as a Complication of Pleural Drainage

Valentina Alicia Rebolledo Navarrete<sup>a</sup>, Hernán Luis Canale<sup>a,b</sup>,  
Alejandro Gabriel Da Lozzo<sup>c</sup>, Horacio Matías Castro<sup>b,\*</sup>

<sup>a</sup> Servicio de Medicina Interna, Hospital Italiano de San Justo Agustín Rocca, Argentina

<sup>b</sup> Sección de Neumonología, Hospital Italiano de Buenos Aires, Argentina

<sup>c</sup> Sección de Cirugía Torácica, Hospital Italiano de Buenos Aires, Argentina



**Fig. 1.** (A) Eyelid ptosis and myosis of the left eye. (B) Chest X-ray: the tip of the pleural drainage tube is seen at the left lung apex (red arrow).

We report the case of a 19-year-old male patient with a history of left spontaneous pneumothorax 6 months previously who was admitted to the adult emergency department for a second spontaneous pneumothorax event. As the pneumothorax was recurrent, a left video-assisted thoracoscopy was performed with pulmonary wedge resection at the dystrophic lung apex and mechanical abrasion pleurodesis. A pleural drain connected to a  $-20$  cmH<sub>2</sub>O continuous suction system was subsequently placed. On the third day, the patient developed eyelid ptosis, anhidrosis, and unilateral left myosis (Fig. 1A), with no evidence of any other motor or sensory neurological focus. Chest X-ray showed pleural drainage in the left vertex near the region of the stellate ganglion (Fig. 1B). The case was interpreted as Horner syndrome caused by irritation of the

stellate ganglion by the drainage tube. The chest tube was partially withdrawn, and the clinical picture resolved after 5 days.

Horner syndrome due to pleural drainage has an incidence of less than 1%.<sup>1</sup> It is associated with proximity of the tube to the stellate ganglion in the lung apex. It usually resolves after withdrawing or moving the chest tube.<sup>2</sup>

#### Funding

We have no sources of funding for the development of the manuscript.

#### Conflict of interests

We have no conflict of interests related directly or indirectly to the contents of this paper.

#### Appendix A. Supplementary data

Supplementary data associated with this article can be found, in the online version, at [doi:10.1016/j.arbres.2022.05.014](https://doi.org/10.1016/j.arbres.2022.05.014).

#### References

1. Kaya SO, Liman ST, Bir LS, Yuncu G, Erbay HR, Unsal S. Horner's syndrome as a complication in thoracic surgical practice. *Eur J Cardio-Thorac Surg.* 2003;24:1025–8.
2. Thomas DT, Dagli TE, Kiyani G. Horner's syndrome as a rare complication of tube thoracostomy: case reports and review of literature. *J Pediatric Surg.* 2013;48:1429–33.

\* Corresponding author.

E-mail address: [matias.castro@hospitalitaliano.org.ar](mailto:matias.castro@hospitalitaliano.org.ar) (H.M. Castro).