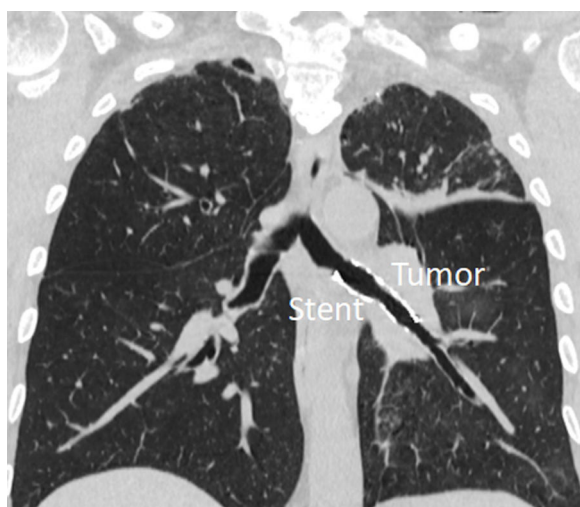


## Clinical Image

# Collateral Ventilation Effect After Endoscopic Recanalization of Malignant Stenosis

Alfonso Fiorelli\*, Gaetana Messina, Mario Santini

Thoracic Surgery Unit, University of Campania "Luigi Vanvitelli", Naples, Italy



Collateral Ventilation (CV) is defined as the ventilation of alveoli via pathways that bypass normal airways.<sup>1</sup> Herein, we reported the positive effects of CV through incomplete fissure in a patient undergoing endoscopic treatment of malignant stenosis.

A 57 year-old man underwent endoscopic recanalization of main and left lower bronchus for a malignant stenosis by rigid bronchoscope. A fully covered stent was placed from the main bronchus to the lower bronchus to prevent tumor re-growth. Chest Computed Tomography (CT) scan performed two days later discovered complete re-expansion of the lung, despite the obstruction of upper bronchus (Video 1). This evidence was likely explained by CV through incomplete fissure, as demonstrated by retrospective quantitative analysis of fissure integrity.<sup>2</sup>

This case shows that CV can improve the effect of endoscopic recanalization, and its routine assessment in addition to standard exams may be useful, when an intervention for opening up airways is scheduled. However, the presence of incomplete fissure cannot always predict CV effect. Yet, it remains unclear whether the ventilation of a lobe with obstruction of the bronchus really adds functional benefits. Thus, the decision to reopen up or not airways cannot be made only in relation to the results of CV assessment.

### Informed consent

The patient gave written consent for the publication of the study.

### Funding

The authors disclose no funding for the present paper.

### Conflict of interest

The authors disclose no conflict of interest for the present paper.

### Appendix A. Supplementary data

Supplementary data associated with this article can be found, in the online version, at [doi:10.1016/j.arbres.2022.04.006](https://doi.org/10.1016/j.arbres.2022.04.006).

### References

1. Terry PB, Traystman RJ. The clinical significance of collateral ventilation. *Ann Am Thorac Soc.* 2016;13:2251–7.
2. Fiorelli A, Poggi C, Anile M, Cascone R, Carlucci A, Cassiano F, et al. Visual analysis versus quantitative CT analysis of interlobar fissure integrity in selecting emphysematous patients for endobronchial valve treatment. *Interact Cardiovasc Thorac Surg.* 2019;28:751–9.

\* Corresponding author.  
E-mail address: [alfonso.fiorelli@unicampania.it](mailto:alfonso.fiorelli@unicampania.it) (A. Fiorelli).