

Clinical Image

[Translated article] Visualization of the Pleural Space During a Flexible Bronchoscopy due to Bronchopleural Fistula



Visualización de cavidad pleural a través de broncoscopia flexible debido a gran fístula broncopleurales

Thais Beauperthuy Levy^{a,*}, Eduard Barrio Herraiz^{a,1}, Javier Fullana^b, Enrique Cases Viedma^a

^a Servicio de Neumología, Hospital Politécnico y Universitario La Fe, Valencia, Spain

^b Servicio de Neumología, Hospital Universitario Arnau de Vilanova, Valencia, Spain

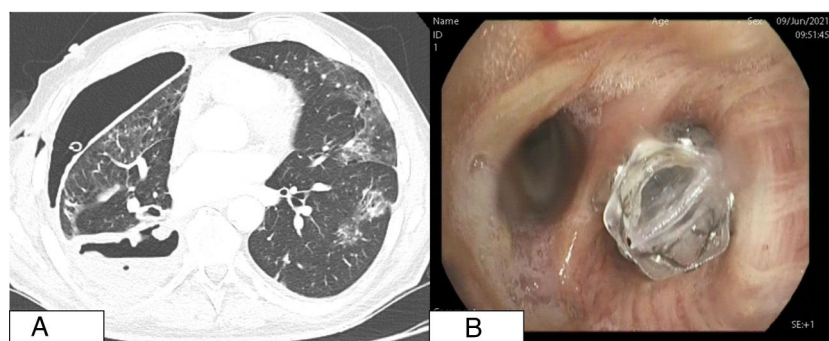


Fig. 1. (A) Chest CT scan with cavitary lesion and pneumothorax associated with pleural drainage inside the pleural cavity (note thickening of the visceral pleura). (B) Endoscopic view of the Zephyr valve at the entrance to the right lower lobe.

We report the case of a 62-year-old man, smoker (45 pack-years), with COPD and recent diagnosis of right lower lobe epidermoid lung carcinoma T4N2M0 (stage IIIB), receiving chemotherapy and radiation therapy. He was admitted for right hydropneumothorax and a chest tube was placed. His subsequent progress was poor, with *Staphylococcus aureus* empyema and persistent air leak, diagnosed as a bronchopleural fistula (Fig. 1A). Endoscopic treatment was performed using a Zephyr one-way endobronchial valve in the right lower lobe. Seven days later, the air leak occurred again, so the bronchoscopy was repeated, showing cranial displacement of the valve at the entrance of the right basal segment. In this position, it was ineffective (Fig. 1B), so it was removed. Fibrinoid and purulent material, observed distal to the valve, was removed. The pleural cavity was accessed, giving a view of the parietal and diaphragmatic pleura, both of which were thickened and had an infiltrative appearance, and of the correctly positioned chest tube (Appendix B video). Bronchopleural fistula

has a poor prognosis (mortality 0.05%–27%).¹ The most important risk factors are age, diabetes mellitus, necrotizing lung infection, COPD, chronic corticosteroid treatment, or chemoradiotherapy.² Although the treatment of choice is surgery, carefully selected patients who are not candidates for surgery may benefit from endoscopic treatment. In our case, the patient presented acute concomitant infection in addition to the fistula, creating controversy with regard to the placement of an endobronchial valve. However, surgery was ruled out due to the patient's comorbidities, so this was the only therapeutic possibility available to control the air leak. Chemoradiotherapy could subsequently be reinitiated.

Appendix A. Supplementary data

Supplementary data associated with this article can be found, in the online version, at [doi:10.1016/j.arbres.2021.09.023](https://doi.org/10.1016/j.arbres.2021.09.023).

References

1. Sirbu H, Busch T, Aleksic I, Schreiner W, Oster O, Dalichau H. Bronchopleural fistula in the surgery of non-small cell lung cancer: incidence, risk factors, and management. *Ann Thorac Cardiovasc Surg.* 2001;7:330–6. PMID: 11888471.
2. Dugan KC, Laxmanan B, Murgu S, Hogarth DK. Management of persistent air leaks. *Chest.* 2017;152:417–23. <http://dx.doi.org/10.1016/j.chest.2017.02.020>.

DOI of original article: <https://doi.org/10.1016/j.arbres.2021.09.002>

* Corresponding author.

E-mail address: thaiscarob@gmail.com (T.B. Levy).

¹ Both authors have contributed equally to the writing of this article.