



Scientific Letter

Successful Long-Term Treatment Combining Omalizumab and Anti-IL-5 Biologics in Allergic Bronchopulmonary Aspergillosis


To the Director,

Allergic bronchopulmonary aspergillosis (ABPA) is considered a T2 inflammatory disease caused by a hypersensitivity reaction to *Aspergillus fumigatus* (AF) fungal spores. It affects up to 2.5% of patients with persistent asthma and is diagnosed using recommended criteria.¹ ABPA pathogenesis is a combination of innate and adaptive allergic immune responses. It is driven by T2 interleukins (ILs), such as IL4 and IL13 cytokines, which activate immunoglobulin-E (IgE)-secreting plasmacytes and promote eosinophilic attraction and IL5 secretion.^{1,2}

Standard treatment includes oral corticosteroids (OCS) and itraconazole.¹ Despite this treatment, some patients continue to experience uncontrolled asthma symptoms. The effectiveness of omalizumab and anti-IL5/IL5 receptor (IL5R) in ABPA has been documented in case reports and case series.^{3–10}

We present for the first time the results of a long-term combination of omalizumab and anti-IL5/IL5R in 3 patients treated for severe asthma and ABPA over 2 years.

Case 1 is a 67-year-old man who was diagnosed with allergic asthma. He was treated with inhaled corticosteroids (ICs) (budesonide 320 mcg/12 h) and formoterol. His asthma progressively worsened, with 2 exacerbations that required hospitalisation needing prednisone (10 mg/24 h) in a maintenance regimen. At that time, a complete study showed a positive skin prick test for AF, and blood tests revealed eosinophilia (Fig. 1), high total IgE (1457 IU/ml) and elevated specific AF-IgE (16.3 kU/L). Computed tomography (CT) showed central bronchiectasis with mucoid impactions in both lower lobes. There were no other concomitant allergic diseases. The patient was thus diagnosed with ABPA.¹ Treatment was modified to budesonide (1600 mcg per day), formoterol, tiotropium, montelukast, prednisone (1 mg/kg/d) and itraconazole (200 mg daily). After 2 months of treatment, prednisone could not be reduced below 7.5 mg.

In an attempt to reduce OCS, omalizumab (at recommended doses adjusted to IgE level and weight) was prescribed. Over 5 years, his asthma symptoms and exacerbations were controlled, and OCS could be reduced to 2.5 mg daily.

After this period, the patient progressively needed slightly higher doses of OCS to maintain control of daily symptoms, and he experienced 2 exacerbations and elevated blood eosinophils (Fig. 1), that required increased doses of OCS to 5 mg (Fig. 2). We added benralizumab 30 mg/q4w, and q8w after 3 doses. This combined treatment controlled the exacerbations for 1 year and OCS could be suppressed, and the total IgE was reduced (610 IU/ml). Thus, we decided to reduce the omalizumab doses to 225 mg/q2w. One

year later, the patient's symptoms remain well controlled without daily OCS and with no exacerbations (Figs. 1 and 2).

Case 2 is a 74-year-old woman diagnosed with allergic asthma. Initially, her asthma was controlled with ICs (fluticasone propionate 500 mcg) and salmeterol; 5 years later, however, her asthma control worsened, with at least 4 exacerbations.

A skin prick test revealed sensitisation to AF, and a blood test showed eosinophilia (Fig. 1), high total IgE (2619 IU/ml) and elevated specific AF-IgE (96.1 kU/L). CT demonstrated central bilateral bronchiectasis with mucoid impactions. She suffered no other allergic comorbidities. Taking all these data into account, the patient was diagnosed with ABPA.¹ Treatment was intensified: fluticasone propionate was increased up to 1000 mcg/day and tiotropium was added, as well as prednisone (1 mg/kg/d) and oral itraconazole (200 mg/d).

After 2 months of treatment, even with prednisone 5 mg daily to control asthma symptoms, she experienced 2 exacerbations needing OCS. Therefore, omalizumab was started (at recommended doses adjusted to IgE level and weight), which managed to control her asthma and withdrawn OCS for 9 years.

After this period, the patient had 2 exacerbations, worsening of daily symptoms and eosinophilia (Fig. 1). Then, we started her on benralizumab 30 mg/q4w, and q8w after 3 doses.

After 1 year of follow-up, she reported an improvement in symptoms and had no exacerbations. Given that total IgE had been reduced to 770 IU/ml, we decided to reduce omalizumab to 225 mg/q2w. One year later, she remains asymptomatic.

Case 3 is a 51-year-old man diagnosed with allergic asthma. He was receiving treatment with ICs (fluticasone propionate 1000 mcg) and salmeterol.

Five years later, he had 2 severe exacerbations. A skin prick test for AF was positive, and a blood test revealed eosinophilia (Fig. 1), elevated total IgE (1206 IU/ml) and elevated specific AF-IgE (18.1 kU/L). CT showed central bronchiectasis and mucoid impaction in the left superior lobe. A diagnosis of ABPA was made.

The patient was given treatment with prednisone (1 mg/kg/day), itraconazole (200 mg/d) and inhaled tiotropium. Given that there was no clinical improvement (he had 3 exacerbations) and because it was not possible to withdraw OCS, omalizumab at recommended doses adjusted to IgE level and weight was prescribed. One year later, his symptoms had improved, and exacerbations stopped; thus, OCS could be reduced to 5 mg daily.

Three years later, he had 3 exacerbations, and eosinophils increased (Fig. 1). Mepolizumab 100 mg/q4w was initiated. It led to control of the exacerbations, and OCS was tapered 1 year later. Total IgE was reduced to 682 IU/ml. At this time, we reduced the omalizumab dose to 150 mg/q2w; 1 year later, symptoms remain controlled.

This group of patients with severe asthma and ABPA improved after being treated with maximum doses of omalizumab. A few years later, however, they experienced unexpected clinical dete-

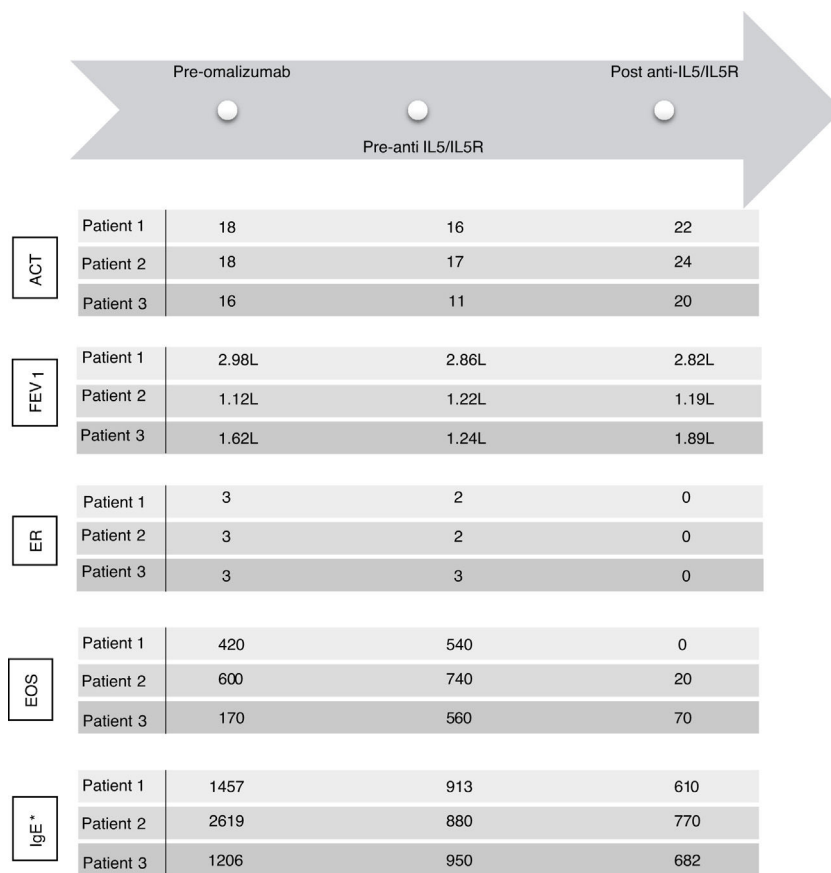


Fig. 1. ACT: Asthma Control Test; EOS: eosinophils; FEV1: forced expiratory volume in 1 second; ER: exacerbation rate; IgE: immunoglobulin E (UI/ml)*; IL5: interleukin 5; IL5R: interleukin 5 receptor. FEV1 was calculated in a MasterScreen spirometer (Viasys, Würzburg, Germany) according to ATS/ERS recommendations and GLI reference values for spirometry. * IgE levels measured during treatment with omalizumab concern free and omalizumab-bound IgE.¹⁶

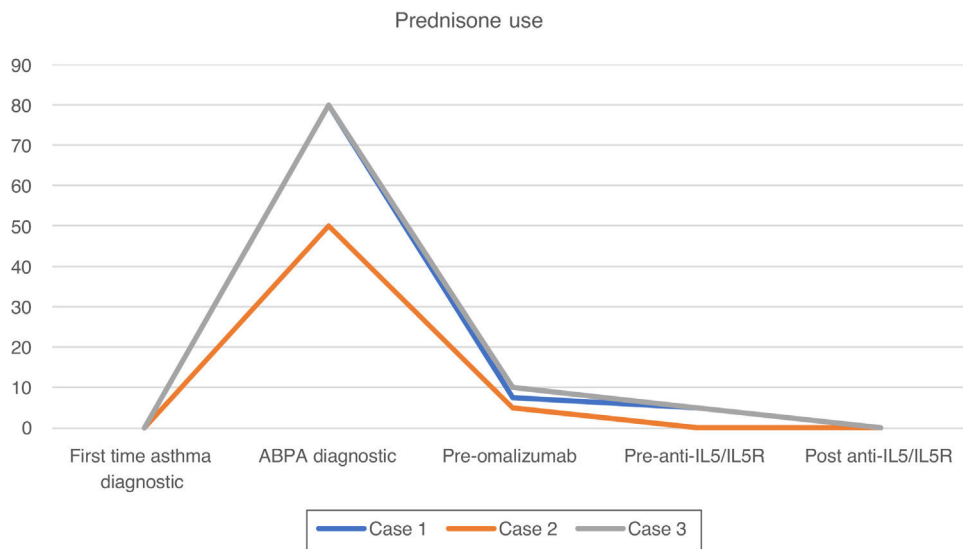


Fig. 2. Timeline of prednisone use (mg/day) during treatment of 3 cases. ABPA: allergic bronchopulmonary aspergillosis; IL5: interleukin 5; IL5R: interleukin 5 receptor.

rioration. Suspecting the involvement of an eosinophil-driven inflammatory pathway, we added anti-IL5/IL5R therapy.

We added anti-IL5/IL5R therapy to omalizumab and maintain the latter because it was initially effective in controlling symptoms (Fig. 1), preventing exacerbations and tapering OCS (Fig. 2) for several years. Combining omalizumab and anti-IL5/IL5R allowed us to control symptoms (Asthma Control Test, ACT: 20–24), reduce exacerbations to zero, improve pulmonary function (Fig. 1) and taper

OCS (Fig. 2). This improvement in ABPA control allowed us to step down progressively the dose of omalizumab, therefore reducing costs. This process is still going on, and may allow us to reduce it even more in the future, to the minimum effective dose.

Treating both allergic and eosinophilic pathways could be an effective and safe way to control refractory ABPA and spare OCS. Although the effectiveness of combining omalizumab and anti-IL5/IL5R in ABPA has been documented in case reports,^{11,12} given

that we do not know whether the same effect would be observed if omalizumab had been switched entirely for anti-IL5/IL5R, further mechanistic studies are needed.

Regarding safety, it is relevant that these patients did not present any adverse events during treatment, including bacterial or parasitic infections. There is no evidence in the literature of any adverse events from combining omalizumab with anti-IL5/R.^{11–15}

In conclusion, our results suggest that adding an IL-5/IL5R biologic on top of omalizumab offers the opportunity to control symptoms in patients with severe asthma and ABPA with a partial response to omalizumab.

Ethics

The research was conducted ethically in accordance with the World Medical Association Declaration of Helsinki. Information revealing the patient's identity has been avoided. All patients have been identified by numbers or aliases and not by their real names.

Study approval statement: Ethics approval was not required because it was a retrospective and observational study. We did not change our daily clinical practice.

Consent to publish statement: The study participants have given their written informed consent to publish their case (including publication of images).

Funding

No funding has been received for this study.

Conflicts of interest

None.

References

- Agarwal R, Sehgal IS, Dhoria S, Aggarwal AN. Developments in the diagnosis and treatment of allergic bronchopulmonary aspergillosis. *Expert Rev Respir Med.* 2016;10:1317–34.
- Parulekar AD, Diamant Z, Hananaia NA. Role of T2 inflammation biomarkers in severe asthma. *Curr Opin Pulm Med.* 2016;22:59–68.
- Quintás-Vázquez LM, Ortiz-Piquer M, Pérez de Llano LA. Effective anti-immunoglobulin-E antibody treatment of a patient with allergic bronchopulmonary aspergillosis. *Arch Bronconeumol.* 2009;45:204–8.
- Li JX, Fan LC, Li MH, Cao WC, Xu JF. Beneficial effects of Omalizumab therapy in allergic bronchopulmonary aspergillosis: a synthesis review of published literature. *Respir Med.* 2017;122:33–42.
- Terashima T, Shinozaki T, Iwami E, Nakajima T, Matsuzaki T. A case of allergic bronchopulmonary aspergillosis successfully treated with mepolizumab. *BMC Pulm Med.* 2018;18:53.
- Soeda S, Kono Y, Tsuzuki R, Yamawaki S, Katsube O, To M, et al. Allergic bronchopulmonary aspergillosis successfully treated with benralizumab. *J Allergy Clin Immunol Pract.* 2019;7:1633–5.
- Soeda S, To M, Kono Y, Yamawaki S, Tsuzuki R, Katsube O, et al. Case series of allergic bronchopulmonary aspergillosis treated successfully and safely with long-term mepolizumab. *Allergol Int.* 2019;68:377–9.
- Schleich F, Vaia ES, Pilette C, Vandenplas O, Halloy JL, Michils A, et al. Mepolizumab for allergic bronchopulmonary aspergillosis: report of 20 cases from the Belgian Severe Asthma Registry and review of the literature. *J Allergy Clin Immunol Pract.* 2020;8:2412–3.
- Bernal-Rubio L, De-la-Hoz Caballer B, Almonacid-Sánchez C, González-de-Olano D. Successful treatment of allergic bronchopulmonary aspergillosis with benralizumab in a patient who did not respond to omalizumab. *J Investig Allergol Clin Immunol.* 2020;30:378–9.
- ClinicalTrials.gov [Internet]. Mageto Y. Benralizumab in the Treatment of Patients With Severe Asthma With ABPA. Bethesda (MD): National Library of Medicine (US). 2000 Feb 29. Identifier NCT04108962. 2019 Sept 30. Available from: <https://clinicaltrials.gov/ct2/show/NCT04108962?term=NCT04108962&draw=2&rank=1> [accessed 19.12.20].
- Altman MC, Lenington J, Bronson S, Ayars AG. Combination omalizumab and mepolizumab therapy for refractory allergic bronchopulmonary aspergillosis. *J Allergy Clin Immunol Pract.* 2017;5:1137–9.
- Ortega G, Tongchinsub P, Carr T. Combination biologic therapy for severe persistent asthma. *Allergy Asthma Immunol.* 2019;123:309–11.
- Dedaj R, Unsel L. Case study: a combination of mepolizumab and omalizumab injections for severe asthma. *J Asthma.* 2019;56:473–4.
- Volpato M, Nowak S, Bourrain JL, Demoly P, Ahmed E, Bourdin A, et al. The six million dollar man. *RJ Open Res.* 2021;7:00341–2020.
- Caskey, Kaufman. Dual biologic therapy in a patient with severe asthma and other allergic disorders. *MJ Case Rep.* 2021;14:e242211.
- Bobolea I, Fernández Rodríguez C, Díaz-Campos R, Melero-Moreno C, Vives-Conesa R. Measuring total IgE is useful in detecting exacerbations in patients with allergic bronchopulmonary aspergillosis receiving omalizumab. *J Allergy Clin Immunol Pract.* 2016;4:361–3.

Daniel Laorden^{a,*}, Ester Zamarrón^a, Javier Domínguez-Ortega^b, David Romero^a, Santiago Quirce^b, Rodolfo Álvarez-Sala^a

^a Department of Pneumology, Universidad Autónoma, Madrid, La Paz University Hospital, IdiPAZ, Madrid, Spain

^b Department of Allergy, La Paz University Hospital, IdiPAZ, and CIBER of Respiratory Diseases, CIBERES, Madrid, Spain

Corresponding author.

E-mail address: daniel.laorden@salud.madrid.org (D. Laorden).