

## Clinical Image

# Sestamibi Scintigraphy & Video-assisted Thoracoscopic (VATS) Resection of Mediastinal Parathyroid adenomatosis: Surgical Technique & Case Report

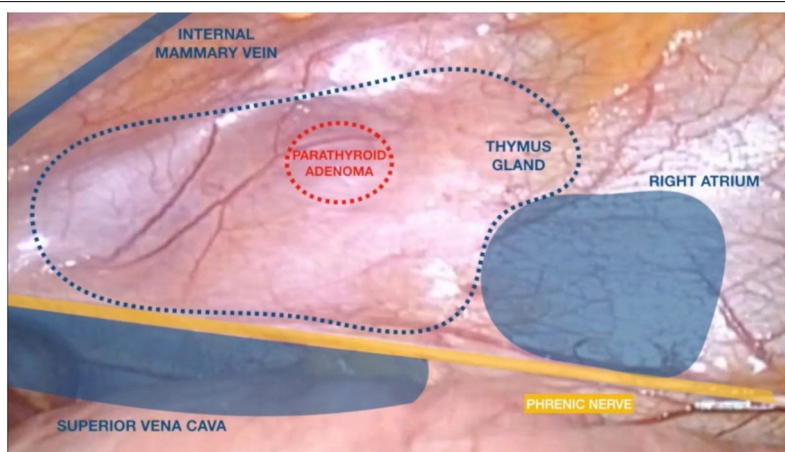


Sebastián Jeri-McFarlane<sup>a,\*</sup>, Orlando Gigirey-Castro<sup>b</sup>, Catalina Sampol-Bas<sup>c</sup>, Ángel Carvajal-Carrasco<sup>b</sup>

<sup>a</sup> General & Digestive Surgery Department, Hospital Universitari Son Espases, Palma de Mallorca, Spain

<sup>b</sup> Thoracic Surgery Department, Hospital Universitari Son Espases, Palma de Mallorca, Spain

<sup>c</sup> Nuclear Medicine Department, Hospital Universitari Son Espases, Palma de Mallorca, Spain



Intra-thoracic parathyroid glands is an unusual presentation (6–16%) of primary hyperparathyroidism,<sup>1</sup> with most patients being asymptomatic during diagnosis.<sup>2</sup>

Surgical resection is indicated for symptomatic ectopic parathyroid adenomas or if calcium levels exceed 10 mg/dl in the asymptomatic patients.

Moreover, intra-thoracic adenomas need careful surgical planning to achieve complete surgical excision. If any tissue is left, hyperparathyroidism persists. Pre-operative Sestamibi scintigraphy evaluates if patient has single or multi-gland disease.<sup>2</sup> Scintigraphy localization can be done pre & intraoperative as shown in the video.

Thymectomy is done by blunt and en-bloc dissection using ultrasonic scalpel avoiding capsular rupture that can lead in potential seeding of cells increasing the incidence of local recurrence.

The removal of ectopic mediastinal parathyroid adenoma using VATS has been described in case reports and shows fewer complications than other procedures, with the post-operative benefits of minimally invasive surgery. One of the causes of surgical failure is the inadequate resection of the adenoma, which can be avoided with the use of radioguided surgery.

Finally, the most common complications in the resection of mediastinal adenomas are the lesion of the recurrent laryngeal nerve and hypoparathyroidism that can be prevented measuring pre and post-operative PTH levels.

## Funding

No funders pertaining to this article.

## Appendix A. Supplementary data

Supplementary data associated with this article can be found, in the online version, at [doi:10.1016/j.arbres.2021.12.004](https://doi.org/10.1016/j.arbres.2021.12.004).

## References

1. Timmerman GL, Allard B, Lovrien F, Hickey D. Hyperparathyroidism: robotic-assisted thoracoscopic resection of a supernumerary anterior mediastinal parathyroid tumor. *J Laparoendosc Adv Surg Tech*. 2008;18:76–9.
2. Møller ML, Rejnmark L, Arveschoug AK, Højsgaard A, Rolighed L. Clinical value of <sup>11</sup>C-methionine positron emission tomography in persistent primary hyperparathyroidism—a case report with a mediastinal parathyroid adenoma. *Int J Surg Case Rep*. 2018;45:63–6.

\* Corresponding author.

E-mail address: [sebastian.jeri@ssib.es](mailto:sebastian.jeri@ssib.es) (S. Jeri-McFarlane).